

## CHAPTER 11

# TRAUMA

Every trauma patient is a special challenge to the surgeon because each case is different. The patient usually arrives as an emergency and may have other injuries as well. The medical staff may neither be fully prepared nor equipped to treat eye injuries. This chapter will describe the general management of any patient with ocular trauma. Then details of the treatment of the more common and important injuries will be given.

### GENERAL MANAGEMENT OF EYE TRAUMA

The injuries must first be assessed in just the same way as for any other patient.

#### **History taking**

An accurate and detailed history must be taken. Two questions in particular are important: how long ago did the injury occur and what was it that injured the eye? Unfortunately there may be a long delay between the injury and treatment. The patient may already have received some treatment either from a doctor, a nurse, or a traditional healer.

#### **Examination**

A systematic detailed eye examination is absolutely vital. This may be not be easy if the eyelids are very swollen or bruised. It may be necessary to part the swollen eyelids with a lid retractor after applying local anaesthetic drops to the eye. If this fails an examination under anaesthetic is necessary especially in children.

The examination of the eye should follow an organised routine. Particular attention should be paid to the following:

1. Measure the visual acuity carefully and in each eye.
2. Examine the eyelids looking particularly for lacerations.
3. Palpate the orbital rim for any notches, tenderness or abnormal mobility, that would suggest a fracture of the orbit.
4. Examine the ocular movement to check for diplopia. Also check for proptosis if the eye is pushed forwards, or enophthalmos if it is displaced backwards.
5. Examine the cornea and conjunctiva. A laceration of the conjunctiva may indicate a deeper laceration in the underlying sclera, and lacerations to the

cornea may be full thickness into the anterior chamber. If available, instill sterile fluorescein drops or use a filter paper impregnated with fluorescein to help to identify corneal abrasions and wounds. If there is a small corneal wound leaking aqueous, this will become very obvious when the eye is examined with fluorescein especially in a blue light (Seidel's test see Plate 3 and 4).

6. Examine the anterior chamber to check whether or not any blood is present (hyphaema). Occasionally the whole anterior chamber is full of dark clotted blood which can easily be missed in a patient with a dark iris (see plate 8). Look also for inflammatory cells in the anterior chamber (hypopyon) which is evidence of infection in the eye (see plate 9).
7. Examine the pupil, its size, shape and reaction, and whether any iris, ciliary body, or choroid has prolapsed out of the eye through the wound.
8. Check the intraocular pressure. This is often forgotten and should always be done unless there is damage to the cornea or an obvious penetrating injury.
9. If indicated, dilate the pupil to examine the lens, vitreous, retina and optic nerve head.

### Special tests

Following the eye examination, skull X-rays may be indicated if any orbital fractures are suspected. A soft tissue orbital X-ray may identify a suspected foreign body in the eye or orbit.

### Treatment

There are three possible types of treatment:

#### 1. First-aid treatment only

Penetrating eye injuries are difficult to repair well, and referral elsewhere may be the best choice. There are many factors to consider: the experience of the surgeon and the equipment available, the distance, time and money involved in referral, and the patient's circumstances. Sometimes the patient has other more serious injuries such as a head injury or serious body injuries which take precedence over the eye injury. First-aid treatment usually means applying antibiotic ointment and a sterile pad to the eye.

#### 2. Medical treatment

*Antibiotics* – The first priority is to prevent bacterial infection with antibiotics. The eyelids are very vascular, so eyelid injuries may not require antibiotics. However all penetrating injuries to the eye must receive antibiotics.

*Anti-fungal agents* – These are indicated for injuries to the cornea with vegetable matter in hot and humid climates, as these favour the growth of fungi.

*Anti-tetanus treatment* – This is necessary, especially if there is a risk of contamination to the wound by soil or faecal matter. The importance of anti-tetanus treatment is often forgotten.

*Other medical treatment* – For injuries to the eye itself *mydriatics* are used to treat iritis. *Steroids* are used both to prevent and treat iritis and inflammation in the cornea.

### 3. *Surgical treatment*

The basic aim of trauma surgery is to try to perform a primary repair of the damaged tissues as an emergency operation. This gives the best chance of restoring the function of the damaged tissues. Lacerations should be resutured so that they can heal with minimal scar formation. It may be necessary to excise dead or infected tissues and to remove foreign bodies. Sometimes primary repair may not be possible. A conjunctival flap to cover the eye may be advisable, or even enucleation of a severely damaged eye may be indicated. Delayed or secondary surgery when the wound has healed may be beneficial in some cases.

## **Summary of General Management of Eye Injuries**

1. History taking, when and how the injury occurred
2. Assessment

*Careful routine examination:*

- especially visual acuity
- fluorescein dye
- intraocular pressure

3. Treatment/First-aid

*Medical:*

- antibiotics
- antifungal agents
- anti-tetanus
- steroids
- mydriatics

*Surgical:*

- primary wound repair
- debridement and excision of damaged tissue
- foreign body removal
- conjunctival flap
- removal of the eye
- secondary (delayed) surgery

## **Types of Eye Injury**

There are a great variety of possible eye injuries but they tend to fit into the following basic types.

Penetrating eye injuries

Non-penetrating eye injuries

Minor superficial eye injuries:

- corneal abrasions
- corneal and conjunctival foreign bodies
- conjunctival lacerations

Eyelid injuries

Orbital injuries and fractures

Cranial nerve injuries affecting the eye

Burns to cornea, conjunctiva and eyelid

Naturally it is possible to have more than one of these injuries at the same time.

## PENETRATING EYE INJURIES

These are the most serious eye injuries with a great risk of total or partial sight loss. They are also common injuries. It is often difficult to decide how to treat them, and carrying out any surgical operation may also be difficult. Therefore most of this chapter concerns penetrating eye injuries. There are basically two different types of penetrating eye injury:

1. *Full thickness lacerations or rupture of the cornea or sclera.* With these injuries the corneal or scleral wounds need to be repaired. Treatment is also necessary for any damage to the eye contents.
2. *Puncture wounds.* With these injuries the wound itself is small and seals off spontaneously. However treatment is still necessary to prevent damage inside the eye.

### **Full thickness corneal or scleral lacerations**

An accurate history must be obtained and examination performed as already described. These injuries are usually easy to diagnose but in certain circumstances can be missed.

- A severe blunt injury to the eye may cause a posterior scleral rupture, which is not obvious from external eye examination. Suspicion should be aroused if the eye is soft and confirmed by examination of the fundus. A vitreous or choroidal haemorrhage will be seen.
- A conjunctival laceration may go deeper and also involve the sclera. Lacerations to the conjunctiva can easily be sutured, but the eye and wound must be examined carefully to exclude a scleral rupture.
- If the eyelids are swollen it may be difficult to examine the eye properly.

When the injury has been fully assessed a decision must be made about the basic management. There are 5 possibilities.

1. First-aid treatment and referral elsewhere.
2. Surgical repair of the wound and replacement or excision of extruded intraocular contents.
3. A conjunctival flap procedure.
4. Medical treatment only.
5. Immediate evisceration or enucleation.

### ***Surgical repair of the wound and excision or replacement of the intraocular contents***

This is the best choice of treatment and will give the best results. The corneal wound edges should be brought together and held in place by fine, non-irritant sutures. In this way the cornea will heal well, scarring will be minimized, and the

regular curvature of the cornea which focuses light on the retina will be preserved. Scleral wounds should also be repaired with direct sutures. However the sclera is opaque, does not transmit light into the eye and is covered by the conjunctiva. Suturing of the sclera need not be so accurate, nor are such fine sutures required. However the exposure of a scleral laceration may be difficult, especially if it extends backwards behind the equator of the eye. Any uveal tissue (the iris, ciliary body and choroid) which has prolapsed through the wound should be excised or replaced, and damaged lens or vitreous may also need surgical treatment.

There are problems in carrying out a primary surgical repair if the patient's arrival at hospital after the injury is delayed. With the passage of time various changes occur in a wound which is left untreated. An inflammatory reaction develops in the injured tissues so that the cornea swells and becomes softer and less easy to suture. The uveal tract (the iris, ciliary body and choroid) is very vascular. These blood vessels will dilate and new vessels grow from the uvea into the wound. The wound will be sealed off with fibrin at first, and later fibroblasts and fibrous tissue as well as blood vessels will grow into the wound to form an opaque fibrous scar. This whole process of healing is often complicated by infection. Penetrating eye wounds often become infected, and the bacteria secrete toxins which cause further inflammation both in the wound and inside the eye.

Once a wound is several days old, any attempt to carry out a primary repair will cause various problems. The iris will not separate from the wound edges and attempts to separate it will only cause bleeding. The tissues become soft, difficult to suture and bleed easily. Any manipulation is likely to spread infection in the eye. Injuries seen within the first 2 days should normally be treated by direct suture. If there is no obvious infection, direct suture can sometimes be carried out up to 4 or 5 days after an injury. After this period, direct suture becomes increasingly difficult and less effective.

### ***Conjunctival flap procedure***

Covering a corneal wound with a flap of conjunctiva is often a better choice for infected wounds or injuries over 4 days old. The wound itself and the tissues are not disturbed by the surgery. The conjunctiva covers the bare iris and provides epithelial cover which acts as a barrier against infection and prevents leakage of aqueous. The blood vessels of the conjunctiva bring in antibodies and white cells to fight against infection, and fibroblasts to help form a scar. The technique of a conjunctival flap procedure is described on pages 258-62. Conjunctival flaps are suitable for all penetrating corneal wounds, but especially for wounds in the peripheral cornea.

### ***Medical treatment only***

For very old wounds, which are more than two weeks old, even a conjunctival flap may not be of much benefit. Once the wound has become epithelialised (this is shown by a failure to stain with fluorescein dye) there is little to be gained by any form of emergency surgery. It is best to give medical treatment only and consider secondary surgery later.

### ***Enucleation or evisceration***

Some years ago this was recommended as primary treatment for many injured eyes, because of the risk of a disease called *sympathetic ophthalmitis*. This causes iritis in the other eye some weeks or months after a penetrating injury in the first eye. Nowadays the use of local steroids and better surgery has made sympathetic ophthalmitis extremely rare. However enucleation should be carried out if there is *definitely* no perception of light in the eye, and it has been very severely damaged with no hope of a good cosmetic repair. Once this decision has been made the enucleation should be carried out as an emergency.

Primary evisceration should only be carried out if there is *definitely* no perception of light in the eye and it is grossly infected.

Another advantage of enucleation or evisceration is that the wound heals up quickly, and so it avoids lengthy hospital treatment which is not going to restore any sight to the eye.

### **Surgical repair of penetrating wounds**

There are two aspects to the surgical repair of a penetrating eye wound. Firstly, how to manage the intraocular contents and secondly, how to close the wound.

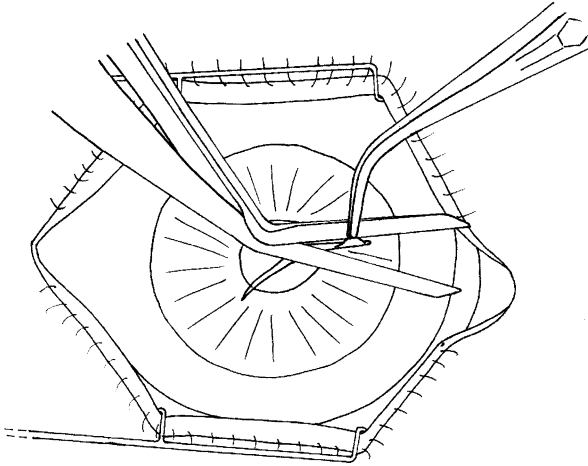
#### ***The intraocular contents***

It is likely that the uveal tract will prolapse through the wound. The iris prolapses through corneal wounds, and the ciliary body and choroid through scleral wounds. The prolapsed uveal tissue can either be excised or replaced. Replacement gives a better chance of restoring the function of the eye but risks introducing infection in the eye. Excision has less risk of infection, but will cause bleeding from the cut edge of uvea. The following factors will influence the choice of either excision or replacement:

1. *How recent and how dirty was the injury?* It is usually safe to replace the uvea in a clean injury treated within 24 hours. With increasing delay or with a contaminated wound the risk of introducing infection increases. The uvea becomes so stuck to the wound edges that it is difficult to free and replace it.
2. *How much tissue destruction has occurred?* A small knuckle of uvea can be replaced and will function normally. Badly damaged tissue will be difficult to replace and will not function normally in any case.
3. *Which part of the uvea has prolapsed – the iris, ciliary body or choroid?* An iris prolapse is likely to get infected quickly, and the iris can be excised without excessive bleeding. Therefore an iris prolapse should be excised if there is any doubt. Prolapsed ciliary body or choroid is usually covered by the conjunctiva and so is less likely to be infected. The choroid and ciliary body will bleed excessively if excised, and excision may also damage the retina, vitreous or suspensory ligament of the lens. Therefore the choroid and ciliary body should be replaced in the eye unless it is essential to excise it.

#### ***Technique for excising uveal tissue (usually the iris)***

Lift the uvea gently with fine forceps. If possible try to free it carefully from the edges of the wound with an iris repositor, then cut it flush with the surface of the



*Fig. 11.1* Excising an iris prolapse

wound using de Wecker's scissors (fig. 11.1). If the uvea is firmly adherent to the wound edges and cannot easily be freed, it is better to leave it sticking to the cornea or sclera rather than provoke bleeding and risk spreading infection by trying to separate it. However, there must be no uveal tissue prolapsing when the corneal or scleral wound is finally sewn together.

#### *Technique for replacing uveal tissue in the eye*

First try to separate any adhesions between the uvea and the wound edge with an iris repositor or similar blunt instrument. Use the side of an iris repositor or blunt irrigation cannula to slide the uveal tissue back into the eye rather than poking it back. The assistant may need to press very gently on the uvea with an iris repositor to hold it back while the cornea or sclera is being sutured. The iris repositor should only rest between the lips of the wound and not enter the eye. The iris is a very delicate tissue and the choroid even more delicate. The choroid will bleed profusely if damaged in any way during the surgery.

If the iris is adherent to the back of the corneal wound but is not present in the lips of the wound, it is best just to suture the wound and not make any attempt to free the iris from the back surface of the cornea. The iris is often firmly adherent to the cornea and the manipulation will do more harm than good.

Penetrating injuries may also involve the lens, the vitreous and the retina. As a general rule there is little to be gained by any other manipulation inside the eye. It is likely to spread infection, provoke haemorrhage and cause further damage especially to the lens. It is a good principle simply to excise or replace the prolapsed uvea, and close the corneal or scleral wound. Other secondary procedures can be carried out once the eye has healed.

Blood clot in the anterior chamber is best left alone. Trying to remove it by grasping it or irrigating it from the eye is likely to cause damage and may provoke fresh bleeding.

There are two occasions when further intraocular surgery is indicated at the time of the emergency wound repair:

- *Vitreous prolapse*, especially through a corneal wound, should be treated like vitreous loss at cataract surgery (see page 114). Every attempt should be made to clear the vitreous from the anterior chamber and prevent adhesions of vitreous to the cornea.
- *Damage to the lens*. If there is extensive damage to the lens especially in a young person, the lens protein will break up and cause severe uveitis. Extensive damage to the lens is best treated by immediate extracapsular cataract extraction. The lens matter should be irrigated out of the eye with a two-way cannula hopefully preserving the posterior capsule. If the lens is only punctured, it should be left for cataract extraction later.

In countries where penetrating wounds are seen early and advanced instrumentation is available, severe penetrating wounds are often treated more aggressively. A vitrectomy and extensive intraocular surgery may well be done at the time of the emergency wound repair. In developing countries where injuries are often seen late, and less sophisticated equipment is available, it is better to adopt a more conservative approach; to do as little as possible as long as the wound is closed carefully either by direct suture or a conjunctival flap. Providing that the wound is properly closed and the eye does not become infected, there is a possibility of further surgical treatment later.

### ***Corneal wound closure***

The aim in repairing corneal wounds is to bring the 2 edges of the wound as close together as possible, so as to minimise any distortion of the cornea and prevent the formation of an opaque scar. Because the suture material is a foreign body, it will itself cause some scarring and irritation. Therefore sutures should be as fine and as non-irritant as possible. Usually the wound is closed with interrupted sutures.

The best suture material is 10“0” or 11“0” monofilament nylon, mersilene or polypropylene. These are so fine that an operating microscope is almost essential, but it is just possible to use them with operating glasses. Ideally this suture should be placed up to three-quarters of the depth of the cornea. It is a common mistake not to put the stitches deep enough. The stitches should be carefully aligned and the same depth on both sides of the wound (fig. 11.2). The needle should pass from the centre of the cornea outwards to the periphery. The technique of tying the knot is described on pages 35–6. It is best to bury the knot, or the suture ends on the surface of the cornea will irritate the eye. Burying the knot is done by rotating the stitch with suture tying forceps after tying the knot and cutting the ends. The knot should be buried so that it passes into the periphery of the cornea. Alternatively the knot can be buried by starting and finishing the suturing with the needle in the wound.

If 10“0” or 11“0” suture material or good magnification is not available, 9“0” nylon is the best alternative and failing that virgin silk. However the knot will be too bulky to bury by rotating the stitch, and if it is buried it will be difficult to remove the knot from the cornea when removing the stitch. Therefore leave the knot on the surface, but place it at the peripheral side of the wound and cut the stitch ends very short. If neither 9“0” nor virgin silk sutures are available then use the finest sutures that are available.



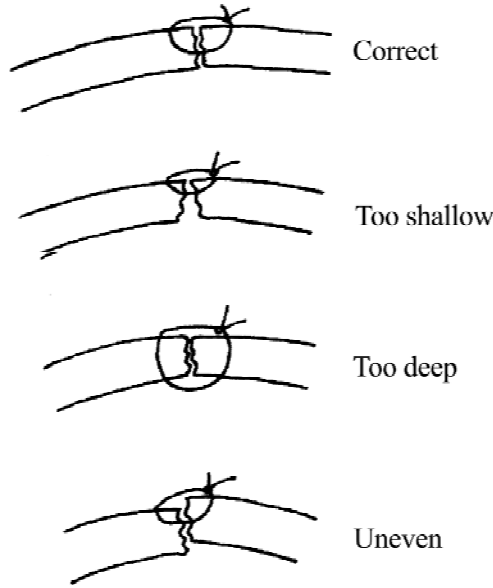


Fig. 11.2 Correct and incorrect sutures for a corneal wound

In ideal circumstances the sutured corneal wound should be “water-tight”. The anterior chamber may reform spontaneously during the operation. Alternatively it should be reformed when balanced salt solution is irrigated into the anterior chamber through a fine cannula placed in the wound between 2 sutures (fig. 11.3). Sometimes it is impossible to get a “water-tight” wound in which case an “air-tight” wound is satisfactory. A small bubble of air is injected into the anterior chamber through the fine cannula. It is best not to completely fill the anterior chamber with air as this may occasionally obstruct the circulation of aqueous in the eye and cause glaucoma. Enough sutures should be placed to ensure that the wound is at least air-tight.

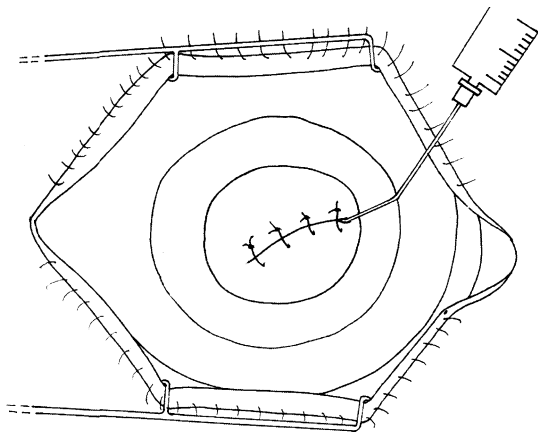


Fig. 11.3 Reforming the anterior chamber

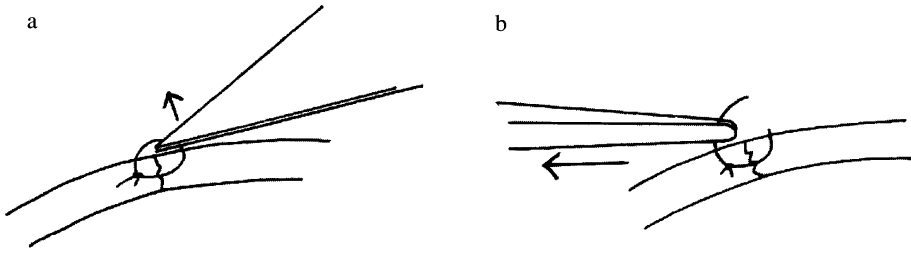


Fig. 11.4 Removing corneal sutures

### *Removal of corneal sutures*

The removal of corneal sutures is quite important, and unlike the removal of other sutures it is a task that cannot be delegated. Corneal wounds, especially in the centre of the cornea, take a long time to heal because the cornea has no blood vessels. If mono-filament sutures with buried knots have been used these will not cause any irritation, and they can be left in place for up to six months. However, if the knots are on the surface or the sutures come loose, they will act as a foreign body and cause inflammation to the cornea and provoke vascularisation and scarring. Thicker corneal sutures or those which do not have buried knots are usually removed about 4-6 weeks post-operatively because they irritate the eye. To remove corneal sutures:

- First apply local anaesthetic drops and reassure the patient that this is a painless procedure. The patient's cooperation is necessary to keep the head still and their eyes open.
- If available use a slit lamp, but if not lie the patient down and use magnifying glasses.
- Cut the suture with a scalpel blade and then pull on the cut end nearest the margin of the cornea with suture tying forceps (fig. 11.4).
- Apply topical antibiotic drops immediately before and for 2-3 days after removing corneal sutures to prevent any infection of the suture track.

### *Scleral wound closure*

Scleral wounds are more difficult to expose and identify than corneal wounds. It may be necessary to incise and retract the conjunctiva to expose the scleral wound. For very posterior scleral wounds a muscle hook placed around a rectus muscle insertion may help exposure. However scleral wounds are easier to suture than corneal wounds, because very fine sutures are not required. Nor is it necessary to bring the two surfaces perfectly together as the sclera is vascular and heals much better than the cornea. 5"0" or 6"0" suture material, either absorbable or non-absorbable, can be used as the knots will in any case be buried under the conjunctiva. If a scleral wound extends backwards and is hard to expose, a useful hint to help exposure is to put an interrupted suture in the anterior end of the

laceration. Leave the suture end long and the assistant can retract on the stitch. This will rotate the eye so that the next suture can be placed further back and so on.

After the sclera has been repaired, the conjunctiva should be sutured as a separate layer.

## **Puncture wounds of the eye**

Puncture wounds are usually small and seal off spontaneously, but extensive damage may be caused inside the eye. Puncture wounds are usually caused by thorns, splinters of wood or glass, or by tiny high velocity fragments of stone or metal which may be retained inside the eye. Careful history taking and examination are very important. The patient may not realise they have sustained a puncture wound, and often the doctor does not detect it unless a very careful examination is made. Soft tissue X-rays may be helpful to confirm the presence of a foreign body inside the eye and to locate its position. Puncture wounds do not usually require suturing. Wounds in the periphery of the cornea will often become plugged with iris, but this does not require treatment as long as the iris does not prolapse through the wound. Wounds, especially in the central cornea, may leak aqueous. If the anterior chamber is formed they do not need repairing. Even if the anterior chamber is not formed it may be better to apply a firm pad and bandage to a puncture wound than to attempt to suture it. As the tissues swell with oedema and the epithelium heals, the wound will often seal itself. If available, a sterile bandage soft contact lens will help a corneal puncture wound to seal off. Scleral puncture wounds do not usually require surgical treatment, but if there is any doubt about a scleral wound the conjunctiva should be incised and the wound examined to make sure it does not extend.

If a thorn or similar fragment is still embedded in the cornea it should be removed. If there is a possibility that the thorn has gone right through the cornea into the aqueous, apply pilocarpine drops to constrict the pupil before attempting removal. There may be a gush of aqueous humour with collapse of the anterior chamber, and constricting the pupil prevents the lens becoming damaged by the foreign body.

If a tiny fragment remains inside the eye, removal is difficult. These tiny fragments may be difficult to locate and even harder to remove. Usually it is best to leave them, but magnetic foreign bodies must be removed as they will rust and become toxic to the eye. Fortunately they can usually be extracted with a powerful magnet. This is specialised surgery which can wait for a few days, so referral is best. The post operative care and complications of penetrating injuries are basically the same whether they are lacerations or puncture wounds.

## **Post operative care of penetrating injuries**

It is usual to keep the eye padded for 3 or 4 days to help the epithelium to heal, but it should be examined every day.

### *Antibiotics*

All penetrating wounds should be given antibiotics whether they appear infected or not. The choice of antibiotic depends upon availability and any information that

may be available about the organism from culture or gram stain. A sub conjunctival antibiotic injection is routinely given at the end of any surgical repair and after puncture wounds (see page 167 for method and details of doses). A course of systemic antibiotics should be given as well. The first dose may be given by injection but oral antibiotics are perfectly satisfactory. It is usual to apply topical antibiotic drops and ointment until the wound is healed.

### *Mydriatics*

These are given routinely to prevent post operative iritis. Atropine 1% daily is usually recommended for at least a week.

### *Steroids*

There are several reasons for using steroids after penetrating injuries:

- Steroids will reduce scarring and vascularisation of the cornea.
- Steroids will treat the uveitis which always occurs to some extent after penetrating injuries.
- Steroids will lessen the very slight risk of sympathetic ophthalmitis developing.

The usual recommendation is that steroids should be started about 3-4 days after any surgical treatment, so allowing the antibiotics and the body's defences against infection to work. Some surgeons like to start topical steroid treatment immediately to try to prevent inflammation in the eye from the beginning, as the antibiotics should be effective against the risk of infection. Steroid drops or ointment are usually prescribed every 2-4 hours for about two to three weeks.

## **Complications of Penetrating Injuries**

There are many complications and only brief guide-lines about their management will be given here.

### *Infection:*

If the infection does not seem to be responding to treatment after a few days, the antibiotics should be changed. If there was loss of vitreous or the lens at the time of injury, an intra-vitreous injection of antibiotic may be indicated (see page 164). If there is no perception of light and the eye is still infected, evisceration is probably the best course.

### *Iritis:*

There is always some degree of iritis especially in severe injuries. Fortunately sympathetic ophthalmitis (see page 304) is very rare as long as penetrating injuries are treated promptly with topical steroids and effective surgery.

### *Hyphaema and vitreous haemorrhage:*

These may occur and should be left to absorb, unless the hyphaema is total.

*Cataract:*

Cataract is very common after penetrating injuries and always occurs if the lens capsule has been damaged. Cataract may appear very rapidly after the injury or there may be a delay of some months or even years. There may be swelling of the lens causing angle closure glaucoma, or lens matter may leak into the anterior chamber causing secondary iritis and glaucoma. Therefore if a cataract develops after a penetrating injury, cataract extraction should be carried out without delay. If fragments of lens are seen in the anterior chamber immediately after a penetrating injury, the eye should be treated with intensive topical steroids because these lens fragments can cause severe uveitis. It may be best to wash out the lens matter with a two-way cannula.

Traumatic cataract is quite common in young children and these are good cases for an IOL implant. However the operation is often difficult because the lens may be degenerate and the eye damaged in other ways.

*Corneal scarring and astigmatism:* After corneal injury the patient may have quite marked astigmatism which can sometimes be corrected with spectacles. Where available, contact lenses may help.

*Glaucoma and retinal detachments:* These are also complications of penetrating eye injuries. Indeed every patient after an eye injury should be seen and thoroughly examined 2 to 3 months after the injury to check for these complications.

Sometimes after a primary repair of an eye injury it becomes obvious that the eye has no hope of vision. If it is also very inflamed an early decision to enucleate the eye is best. Delay means lengthy treatment for an eye which will never see, and also risks the possibility of sympathetic ophthalmitis. However if the eye is neither painful nor inflamed there is no point in removing it except for cosmetic reasons.

## BLUNT INJURIES TO THE EYEBALL

Blunt injuries occur when the eye is struck and deformed but the cornea and sclera remained intact. These injuries may severely damage the eye by disrupting the delicate intraocular structures, (see fig. 11.5) but for most of this damage emergency surgical treatment is not required.

The only common indication for emergency surgery is to treat severe bleeding in the anterior chamber (hyphaema). This occurs from tears in the iris particularly the root of the iris, where the main iris blood vessels are found. Under normal circumstances fluid blood or blood clot will absorb from the anterior chamber without complications. The treatment is simply to rest the patient because sudden eye movements may provoke further haemorrhage. Blood should be evacuated from the anterior chamber only if there is a very severe hyphaema with raised intraocular pressure. There must be a total and complete hyphaema, so that the whole anterior chamber is full of thick dark blood obscuring any view of the iris. This is sometimes called a "black ball" hyphaema. If the intraocular pressure is raised, degenerate blood cells permanently stain the cornea and also block up the drainage angle, therefore this type of hyphaema should be evacuated.

### Blunt injury causing sudden stretching and deformity to the eye

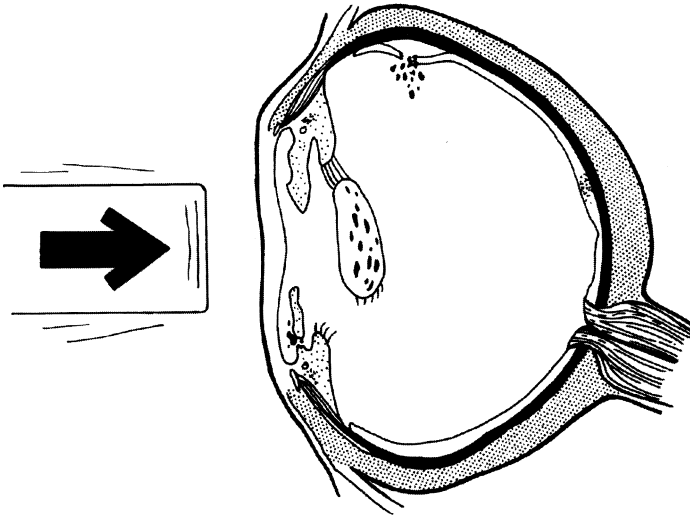


Fig. 11.5a How an eye can be damaged from a blunt injury

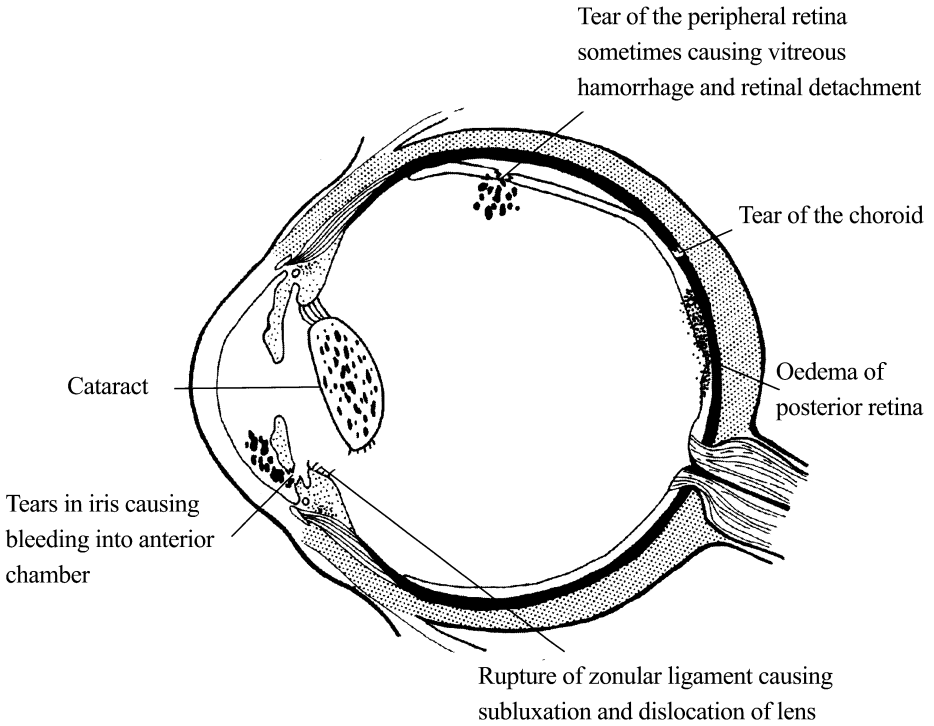


Fig. 11.5b Results of a blunt injury

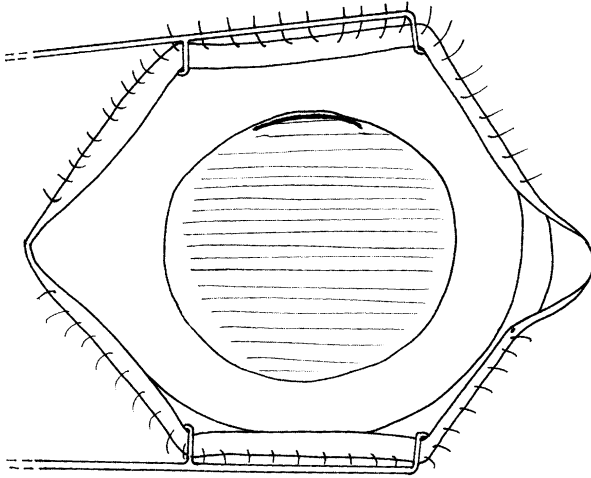


Fig. 11.6 The incision to evacuate a hyphaema

## Evacuation of a hyphaema

### *Method:*

1. Make an incision about 4 mm long in the peripheral cornea (fig. 11.6). Then slowly deepen the incision using a scalpel or a razor blade fragment and go right through the cornea into the anterior chamber. Try to decompress the eye slowly.
2. The important step is to allow thick treacle-like fluid blood to be washed out of the anterior chamber. Formed blood clot is likely to be stuck to the iris and trying to remove it may well provoke further bleeding. Gently irrigate the anterior chamber with Ringer's solution or similar irrigating fluid, attempting to remove as much as possible of the thick treacle-like blood and any blood clot which comes easily out of the eye. Close the wound with one corneo-scleral suture and reform the anterior chamber with Ringer's solution or saline.
3. Treat the patient post operatively with mydriatics and topical steroids. Check the intraocular pressure. The patient should be rested until the remaining blood clot and hyphaema have absorbed.

An emergency trabeculectomy operation (see page 193) is an alternative way of treating a hyphaema with raised intraocular pressure. This is recommended if the hyphaema is not total and complete but the intraocular pressure is raised. The operation will drain the blood out of the anterior chamber and control the pressure for the next few weeks. Nearly always the drainage bleb will then become fibrosed and cease to function, but hopefully by that time the pressure will have returned to normal.

## **Complications of blunt injuries**

These are numerous and may occur soon after the injury or even years later. The most common are:

- Mydriasis from damage to the iris muscle
- Glaucoma from damage to the anterior chamber angle
- Cataract
- Dislocated lens
- Vitreous haemorrhage
- Choroidal and retinal tears and haemorrhages
- Retinal detachment
- Optic atrophy

## **MINOR SUPERFICIAL EYE INJURIES**

These are very common. Various types of injury may occur.

### **Foreign bodies**

These are often blown into the eye and may lodge on the cornea or become trapped inside the eyelids particularly in the groove near the eyelid margin. Always evert the upper eyelid when examining a patient who may have a foreign body in the eye. Most superficial foreign bodies are very easy to remove.

A conjunctival foreign body can usually be wiped off with a sterile swab or cotton bud, after applying local anaesthetic drops.

A corneal foreign body can usually be lifted off with the edge of a small hypodermic needle. Occasionally a high velocity foreign body may become deeply impacted in the cornea. It may then be necessary to use the tip of a hypodermic needle to pick the foreign body out of the corneal stroma. Sometimes the entry point may have to be enlarged with a blade to aid the removal of a foreign body deeply embedded in the cornea. After removal of a foreign body, topical antibiotic drops or ointment should be given to prevent corneal infection. If the patient has come for treatment very late, and there is evidence of established infection in the cornea around the foreign body, then a sub conjunctival injection of antibiotic should also be given. If the foreign body was vegetable matter and injury occurred in a hot and humid climate, an antifungal preparation is also advisable. Natamycin (Pimaricin) has been widely used as an antifungal drop or ointment. If there is superficial damage to the cornea, mydriatics should also be used for 2-3 days, and the eye should be padded until the corneal epithelium has healed.

### **Corneal abrasions**

These are caused by sharp objects striking or scratching the cornea and breaking the epithelium. The eye is very painful, but the abrasion is hard to recognise until fluorescein is applied, and the damaged cornea will be then outlined with fluorescein stain. Always make sure that there is no foreign body still in the cornea or



lodged under the eyelid. The treatment is the same as for a corneal foreign body:- topical antibiotics, possibly topical antifungal agents, mydriatics and an eye pad until the corneal epithelium has healed.

### **Conjunctival lacerations**

These should be explored to make sure that the sclera is intact. Conjunctival lacerations usually heal very quickly. If the wound is gaping the edges of the conjunctiva should be brought together with one or two interrupted fine sutures. If the conjunctiva is not sutured, Tenon's capsule may prolapse through the conjunctival wound and delay healing.

### **Sub-conjunctival haemorrhages**

These are common particularly after blunt injuries. The blood will absorb without complications and no treatment is necessary. However a sub conjunctival haemorrhage may be a sign of an underlying scleral rupture so a full eye examination is necessary. It may be a sign of a fracture of the anterior cranial fossa of the skull, if there is no posterior limit to the haemorrhage, but it spreads right back into the orbit.

## **EYELID INJURIES**

The eyelids are commonly injured because of their exposed position. Eyelid skin easily lacerates because it is so thin. Haematomas occur frequently because the eyelids are so vascular. The eyelids easily swell with oedema or blood because the connective tissue is so lax and secondary infection in the wound will cause further swelling. In spite of eyelid swelling, an attempt must be made to examine the eye itself for damage. The surgical management of eyelid lacerations is essentially the same as any other wound:-

- Cleaning and debridement.
- Primary repair.
- Post-operative management.
- Secondary reconstruction.

Most eyelid repairs can be carried out under local anaesthetic infiltration with added adrenaline.

### **Cleaning and debridement**

Cleaning the wound from dirt, debris or foreign bodies is most important. A good scrub with a fine brush may be helpful although this may provoke some bleeding. Make a very thorough search right to the depths of the wound for dirt or foreign bodies before starting the repair. The eyelid blood supply is so good that debridement of eyelid tissue is not usually necessary. If it is decided to excise severely damaged tissue, only the barest minimum should be removed.

### **Primary repair**

Primary repair of eyelid lacerations should be carried out within 48 hours. The eyelids usually heal very well because of their good blood supply. Closure should be in 2 layers to prevent tethering of the skin.

The tarsal plate and the conjunctiva form the deep layer, and this should be closed with absorbable 5“0” or 6“0” sutures. Make sure that the knot is buried in the tissues and does not rest on the surface of the conjunctiva where it will irritate the cornea. If the laceration involves the eyelid margin take particular care with the suture at the lid margin, so that the two edges come together without a notch or an overlap. If the orbital fat has prolapsed through the orbital septum it can be replaced or carefully excised. The orbital septum joins the tarsal plate to the bony margin of the orbit.

The skin and orbicularis muscle form the superficial layer. Small lacerations require only the skin to be closed using 5“0” or 6“0” non-absorbable sutures. In a large laceration with gaping of the wound and separation of the muscle fibres, one or two subcutaneous sutures using absorbable material will help bring muscle fibres together. Take particular care in closing the lower eyelid skin if the wound is irregular and ragged as it is very easy to end up with skin contracture and an ectropion. If there is any loss of lower lid skin the risk of ectropion is lessened by suturing these irregular wounds vertically rather than horizontally (see page 214).

Lacerations through the medial end of the lower lid involving the lacrimal canaliculus require special care. Often the canaliculus becomes scarred leaving a persistently watering eye. It is best not to attempt a major repair of the canaliculus, but if an operating microscope is available, try to suture these wounds so that the two cut edges of the canaliculus are correctly aligned.

*Tissue loss* – Sometimes large amounts of the eyelid may have been avulsed. If the margins of the wound cannot be brought together without excess tension, then the wound must be left to granulate and eventually epithelialise. If necessary an eyelid reconstruction can be carried out later. What is at first a large defect often shrinks by means of the natural healing processes. If there is a major eyelid defect particularly in the upper lid, the cornea must be very carefully observed to make sure an exposure ulcer does not develop. Plenty of lubricant drops and antibiotic ointment should be applied. A transparent plastic shield taped to the rim of the orbit may help to preserve the cornea whilst waiting for eyelid reconstruction.

## **Post-operative management**

Eye pads are not usually necessary unless there are exceptional circumstances. Eyelid wounds very rarely become infected because of the good blood supply. However if the wound is badly contaminated, or has penetrated into the orbit, or the patient comes to hospital very late, then systemic antibiotics are a good precaution.

Skin sutures can usually be removed early (within 7 days) because the skin will heal rapidly.

## **Secondary reconstruction**

This may be necessary after some eye lid injuries, but should be delayed if possible until the scar is inactive. This may take at least 3 months. The most common reasons for secondary reconstruction are notches of the lid margin, ectropion or tethering of the lower lid. These complications can usually be avoided by a careful primary suture with attention to basic principles.

## BURNS

Burns usually occur in small children at home or in adults from accidents at work. They may have various causes. The most common are:

- Direct heat from a fire.
- A scald from hot fluids.
- Acid burns, the most common is the acid in car batteries.
- Alkali burns, the most common cause is lime or cement used in building.

There are of course many other chemicals or hot objects which may cause a burn.

There are 3 different tissues which may be burnt: the eyelids, conjunctiva and cornea. Burns from a fire usually involve the eyelids. The protective blink reflex occurs so rapidly that the conjunctiva and cornea are often partly or completely preserved.

Acid and alkali burns and indeed any chemical burn is much more likely to involve the conjunctiva and cornea because the fluid enters the eye before the blink reflex can occur. Alkali burns can be particularly severe. Alkalis are not so irritant to the skin, but spread deeply into the cornea causing severe inflammation.

### First aid treatment of burns

A chemical burn of any sort should be treated with immediate and prolonged irrigation of the eye. Even if the patient comes for treatment some hours after the injury, it is still worth irrigating the conjunctival sac with saline or water. Topical anaesthetic drops will help by relieving the pain and blepharospasm. Prolonged irrigation (15 to 30 minutes) is especially important in the treatment of alkali burns. Obviously with increasing delay irrigation becomes less beneficial but it is never harmful. Other first-aid measures are to apply topical antibiotics and a sterile or clean pad and to give the patient analgesics. Solid particles may be embedded in the conjunctiva or cornea and will need removing.

### Definitive treatment

This has 3 aims:

1. *Prevention of infection.* All burns destroy the epithelial cells which form a barrier against the infection, and so all burns have some secondary infection.
2. *Preservation and protection of the cornea.* The eyelids and the conjunctiva protect the cornea. If these are damaged the cornea is at risk of becoming ulcerated and scarred.
3. *Prevention of scarring, particularly in the cornea.* If the cornea becomes scarred the sight will be affected.

### Eyelid burns

These are usually treated by exposure so that a firm scab develops and the eye itself can be examined. If the eyelids are padded the eye cannot be examined and the

dressings may become very sticky and messy from exudate. Topical antibiotics should be applied to the burnt area and severe cases may require systemic antibiotics. In partial thickness burns when the scab finally separates, the underlying eyelid will be reasonably normal. In full thickness burns eyelid contractures will develop. If the eyelid contracture is causing exposure of the cornea, then the scab (burn eschar) must be excised and a skin graft applied. In severe burns repeated skin grafts may be required. As long as the cornea and conjunctiva remain healthy, skin grafting can be postponed until most of the inflammation in the burnt tissues has settled.

## Conjunctival and corneal burns

### *Assessment:*

Once first-aid and emergency treatment has been given, try to get as good an assessment of the injury as possible by careful clinical examination.

- Instill sterile fluorescein drops to see how much of the corneal and conjunctival epithelium has been destroyed.
- Examine the corneal stroma to see if it is transparent or hazy. A hazy corneal stroma means that the deep tissues of the cornea have been damaged, and the cornea is likely to become opaque.
- Examine the limbal blood vessels at the margin of the cornea. If there are areas where the limbal blood vessels appear whitened and constricted rather than red and dilated, the prognosis is poor. The absence of blood vessels indicates necrosis or destruction of the limbal tissues and the limbal stem cells. In these cases severe corneal scarring is likely to develop later.

### *Treatment:*

The immediate treatment of conjunctival and corneal burns is medical.

- *Antibiotics.* Topical antibiotic drops or ointment should be used frequently until the epithelium has healed. Healing may be delayed especially with alkali burns, but until the epithelium has healed there is a risk of secondary infection.
- *Padding.* Padding protects the eye and helps the epithelium to heal quicker, but unfortunately it may encourage the growth of micro-organisms. It is safe to leave the eye without a pad as long as the patient can be carefully observed in clean surroundings.
- *Mydriatics.* These help to prevent iritis whilst the eye is inflamed.
- *Steroids.* There is controversy about the use of steroids. They suppress inflammation and fibrosis and this helps to limit the scarring of the cornea. However they encourage the growth of micro-organisms, and there is also some evidence that they promote the release of enzymes from damaged cornea which cause further corneal destruction. The generally accepted principle is that topical steroids should be given at least 4 times daily for the first week, but not for the second or third weeks when there is danger of enzyme release, and then again after 3 weeks.

- *Ascorbate*. Freshly prepared 10% potassium ascorbate drops given 2 hourly are thought to limit the tissue destruction from alkali burns to the cornea but they sting. Oral ascorbic acid (vitamin C) is also helpful.

### *Delayed treatment*

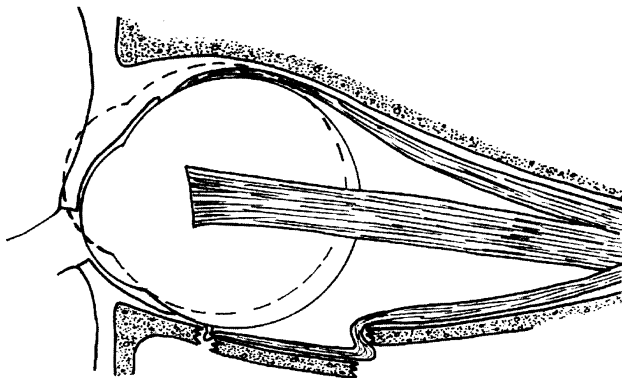
Surgery may be helpful for the delayed complications of burns to the conjunctiva and cornea. Symblepharon (adhesions between the eye and the eyelid) and cicatricial entropion can be treated with a conjunctivoplasty or a conjunctival graft from the other eye. Corneal scars can be treated with limbal grafts from the other eye (see page 267) and corneal grafts from a donor. However the patient's only good eye must not be put at risk in an attempt to preserve a badly damaged one.

## ORBITAL FRACTURES AND INJURIES

Fractures of the orbital margin most commonly involve the zygoma which lies in the lower and outer quadrant of the orbital rim. If there is significant displacement of the fracture, the bone should be replaced within 10 days of the injury. It may be necessary to hold it in place with retaining wires. After 2 weeks it is very difficult to replace the fractured displaced bone.

Fractures of the thin walls of the orbit usually occur from blunt pressure on the orbit such as a punch, and the thin orbital wall gives way. This results in a so-called "blow out" fracture (fig. 11.7) and nearly always it is the floor of the orbit forming the roof of the maxillary sinus which gives way. The following signs indicate a "blow out" fracture:-

- Anaesthesia of the cheek occurs because the infraorbital nerve, which runs along the floor of the orbit, is damaged. Limitation of eye movement and double vision particularly on looking up. This occurs because the orbital fat and the inferior rectus muscle become trapped in the fracture site.
- Enophthalmos occurs because some of the orbital contents prolapse into the sinus.



*Fig. 11.7* A "blow-out" fracture

- The fracture itself is often not obvious on X-ray because the bone is very thin, but the maxillary sinus is often opaque containing either blood or some orbital contents.

These injuries frequently improve without surgical treatment, but if there is no sign of improvement after 10 days the damaged orbital floor should be explored surgically. The prolapsed orbital tissue must be freed from the fracture and the defect in the orbital floor repaired, usually with a silicone sheet implant.

Orbital haematomas are quite common. There is rarely any indication or need for surgically draining the haematoma.

## CRANIAL NERVE INJURIES

Head injuries can affect the cranial nerves which supply the eye. Paralysis of the 4th nerve (trochlear) and 6th nerve (abducent) are most common. These are thin nerves with a long intra cranial course inside the brain. The 3rd nerve (oculomotor) and 2nd nerve (optic) are less frequently damaged. A 3rd nerve palsy in an unconscious patient causing a dilated pupil is often a sign of raised intracranial pressure and urgent neurosurgery is required.

Cranial nerve palsies especially to the 3rd, 4th and 6th nerves often recover with time, but if there is no recovery after 6 months then surgery to the extraocular muscles may improve or cure the double vision.