

## CHAPTER 5

# CATARACT SURGERY

A cataract is an opacity of the crystalline lens in the eye (see fig. 5.1). About 40 million people in the world are blind and about half of these are blind from cataract. Most patients with cataract are elderly but there are many who are young or middle aged. At present the only treatment for cataract is the removal of the opaque lens. It is not likely that any other treatment or means of preventing cataract will be discovered in the next few years. ***Therefore the greatest challenge for ophthalmology in the world at present is to make cataract surgery available for all.*** Some of the issues in providing appropriate cataract surgery have been discussed in general terms in Chapter 1 in the introduction, and the student may find it helpful to think again about these basic principles described on pages 4–12. Not only must cataract surgery be available for all who require it, but the standard of surgery and after-care should be satisfactory, even in rural “eye camps”. Regrettably in some areas it is quite common to find patients whose eyes have been spoilt from the complications of poor cataract surgery or who have never been given corrective spectacles after surgery. For anyone operating on the eye, the most important operation will be a cataract extraction. Cataract surgery is such an important subject that this chapter will describe more than just the technical details of the operation. Each of the following topics will be discussed:

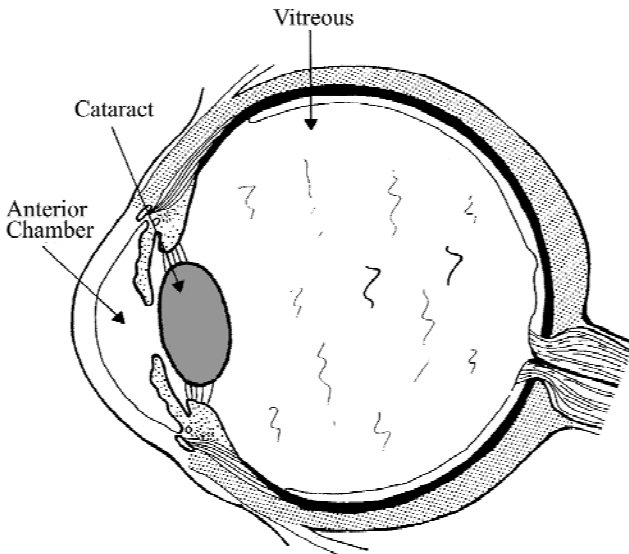


Fig. 5.1 A cross section of the eye to show a cataract

1. The history of cataract surgery.
2. How to restore the focus of the eye once the cataract has been removed.
3. The indications for surgery.
4. The choice of operation.
5. The technical details of the operation both for extracapsular and intracapsular cataract extraction, and how to manage complications during the operation.
6. The use of intraocular lenses and how to implant them.
7. Routine post-operative care.
8. Post-operative complications and how to manage them.

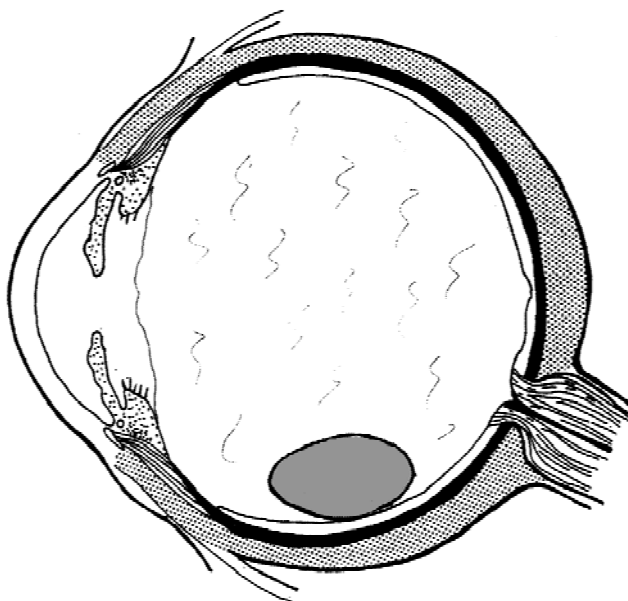
## The History of Cataract Surgery

It is not surprising that attempts have been made since the beginning of history to treat a disease as common and disabling as cataract. Surgical treatment of cataract has been described in several ancient cultures, and is thought to have started about 2500 B.C. in India. The aim of this traditional operation is to push the opaque lens downwards and backwards into the vitreous. The operation is usually called “**couching**”. The word is derived from the French word “coucher” – to push down. It has been practised for thousands of years and is still performed today in some parts of the world. The technique is basically as follows:

A needle or similar sharp instrument is inserted into the eye a few millimetres behind the limbus. It is moved around the eye to rupture the suspensory ligament of the lens so that the lens can then be pushed down and back into the vitreous (fig. 5.2). At first the patients usually have an improvement in their vision, but there are often late complications and the long-term results are not good. Two particular complications are both common and serious.

- *Infection.* Most people who practise couching are not aware of the nature of bacteria and the importance of sterile techniques. Their instruments are often not sterile and bacteria may enter into the eye during the operation. If an infection occurs in this way the eye is nearly always blinded.
- *Rupture of the Lens.* Often the lens capsule is damaged during couching. Lens protein then leaks out into the vitreous. This usually causes a severe inflammatory reaction in the eye (uveitis) and often raised intraocular pressure (glaucoma). By the time this inflammation has subsided and the intra-ocular pressure returned to normal the eye is usually blind or almost blind.

Couching is still practised today in spite of the high rate of complications. Most couchers are not well educated, they usually have little understanding of basic medical science, and travel from village to village practising their art. It is very difficult to trace them and impossible to get any scientific reports about how good or how bad the operation really is. Even with skilled couchers only about 50% of



*Fig. 5.2* The eye after “couching” or dislocation of the cataract into the vitreous

the eyes will recover some useful vision. In most cases the results are much worse. Also most couchers do not give spectacles to their patients after the operation, and so even those who have had successful operations and are free of complications will not recover good vision.

People who are trained in orthodox medicine are often very critical of the activities of these couchers. However they only continue to practise their art because orthodox medicine has not yet faced the challenge of making low cost cataract surgery available for all, especially for patients in isolated rural areas.

Is it possible to make couching a safer and more effective operation? The two main complications of couching are intraocular infection and rupture of the lens capsule. With properly sterilised instruments and sterile techniques, the risk of intraocular infection would be reduced. Some people claim that if care is taken, then it is possible to dislocate the lens without rupturing its capsule. However, there have not been enough reliable published reports to recommend it as a procedure, and so it will not be discussed any further in this book.

About 200 years ago attempts were made to remove the cataractous lens from the eye rather than pushing it into the vitreous. The first operation described was an **extracapsular cataract extraction**. This operation removed the lens nucleus and part of the lens cortex but left the lens capsule behind in the eye (see fig. 5.3).

The most common complication was that some lens cortex remained in the eye. This caused inflammation in the eye (uveitis) post operatively. Often a thick opaque membrane consisting of the lens capsule and opaque lens cortex and fibrous tissue developed in the pupil. This obscured the vision and required further surgery.

Remnants of lens capsule

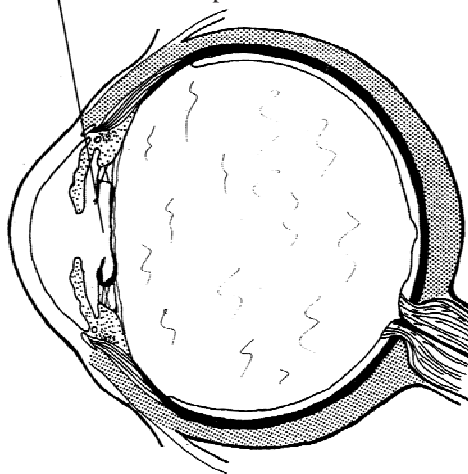


Fig. 5.3 The eye after extracapsular extraction

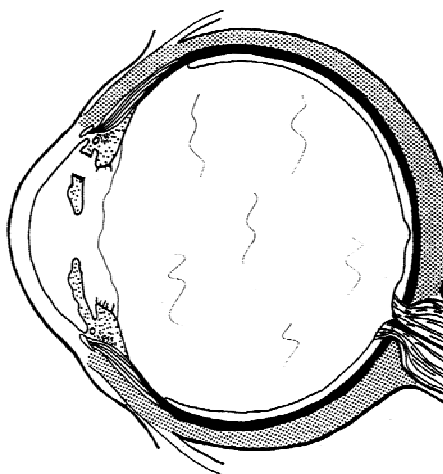


Fig. 5.4 The eye after intracapsular extraction

About 100 years ago **intracapsular cataract extraction** was introduced. This removed the whole lens (fig. 5.4) and the operation became increasingly popular. The post operative complications were less than with extracapsular extraction, and until about 15 to 20 years ago intracapsular extraction was the standard operation for senile cataract.

However during the last 20 years the results of extracapsular extraction have greatly improved. There are two reasons for this.

1. With modern surgical techniques, and particularly with the use of operating microscopes, the anterior lens capsule and all the lens cortex can be removed, leaving only the thin transparent posterior lens capsule in the eye.
2. Topical steroid treatment postoperatively has greatly reduced postoperative uveitis which was common following extracapsular extraction.

The complication rate of extracapsular extraction is now less than that of the intracapsular method, and it is now the recommended method of cataract surgery. The other great advantage of extracapsular extraction is that intraocular lens implants can easily be inserted behind the iris and in front of the posterior lens capsule. This is safest and most secure place for intraocular lens implants to rest within the eye.

Technology continues to advance rapidly. Extracapsular extraction can now be performed using an ultrasonic probe to break up the cataract inside the eye so it is removed through a tiny incision. The operation is called **phakoemulsification**. Because its results are so good, phakoemulsification has now become the standard way of removing most cataracts in developed countries. There are several advantages of phakoemulsification.

### ***The advantages of phakoemulsification***

- Because of the smaller incision the wound heals more quickly, and the shape of the eye is not altered so there is very little astigmatism after the operation.
- No suturing of the wound is required. This saves time and cost, and it means that there are no problems later on from the sutures causing irritation or inflammation.
- The shape and the volume of the eye and the intraocular pressure are maintained throughout the operation. This reduces the trauma to the eye during surgery, and so causes less postoperative uveitis.
- Because of the smaller incision, good local anaesthetic blocks are not so essential. Indeed some expert phakoemulsification surgeons only use topical anaesthetic drops.

Phakoemulsification is now being introduced in developing countries and is being enthusiastically promoted. However it is not always an appropriate technique for general use in developing countries for several practical reasons.

### ***The disadvantages of phakoemulsification***

- Cost. The equipment is very expensive and needs expert maintenance. There are additional expenses for disposable items for each case. A top quality microscope with good illumination and focusing controls is also essential, so that the surgeon can see exactly what the “phako” probe is doing inside the lens.
- White, opaque cataracts and advanced cataracts with very dense, brown, hard nuclei are the least suitable cases for phakoemulsification, and these are both very common in developing countries. Phakoemulsification is an ideal procedure for removing cataracts which are in their early stages. As the cataract gets harder and more opaque the risk of serious complications from phakoemulsification also increases, and phakoemulsification is less likely to be successful. (However experts in phakoemulsification can “phako” nearly all cataracts).
- Training. Phakoemulsification is a difficult technique to learn, and a longer period of training is required.

The philosophy of this book is to describe technology and methods appropriate for poorer communities. Also phakoemulsification is an operation which is too detailed to be described satisfactorily in this book, and will not be discussed in more detail.

There is another rather subtle consequence from recommending phakoemulsification for all cataract surgery worldwide. This concerns the right use of medical resources. Every country, even the richest, has to put some cash limit on the cost of

medical care. So-called “developed” countries are already having to face this problem, which will become worse as modern medical care becomes even more complex and expensive. In poor “developing” countries limited medical resources must be used carefully to be of the greatest benefit to the community. The evidence is that the number of people in the world blind with cataract is increasing every year. A cataract extraction is an extremely cost-effective operation. For quite a small cost it can make a tremendous difference to a patient’s life. Lens implant surgery (see page 81) means that a cataract can be removed at a much earlier stage, and phakoemulsification is such a good operation that cataracts can be removed when the patient is only beginning to have any symptoms. In most developing countries people living in isolated rural areas have the least access to the limited medical care available, and consequently have the highest prevalence of cataract blindness. By introducing phakoemulsification the wealthier patients and those living in the cities may receive more surgery and at an earlier stage. However, this may direct resources away from the rural blind with more advanced cataracts.

Many developing countries are now in the strange situation that all four methods of cataract extraction may be practised in the same country.

*Couching* is still performed in some rural areas.

*Intracapsular cataract extraction* is still practised extensively.

*Extracapsular cataract extraction* is becoming increasingly popular especially as microscopes and good quality, low cost, intraocular lenses are being introduced.

*Phakoemulsification* is now becoming quite a common procedure in some developing countries especially in the major cities.

***The fact that operations using the technology of 3000 years ago are being carried out at the same time as those using the most modern technology shows how great is the need for community based development of surgical treatment, which will help everybody and not just a few.***

## **Restoring the Focus of the Eye After Cataract Extraction**

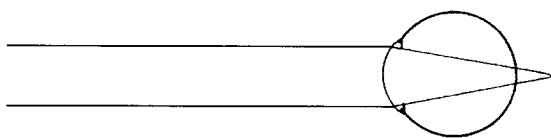
(see fig. 5.5)

An eye that has had the lens removed is called an *aphakic* eye, and the condition is called *aphakia*. The lens helps to focus the light on the retina, and so after a cataract operation the eye is badly out of focus (fig. 5.5a). A strongly positive or convex lens is needed to restore the normal focus of the eye. (The only exception to this is a very myopic patient who will not require such a strongly positive lens after cataract extraction).

There are three sorts of lens which can be used to restore the focus of the eye: *spectacles*, *contact lenses* or *intraocular lenses*.

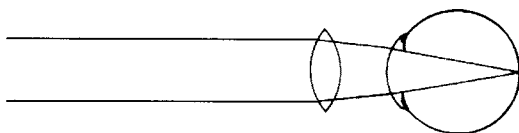
### ***Spectacle lenses***

Spectacle lenses have been used for many years to restore the focus of the aphakic eye (fig. 5.5b). A positive lens of about 10 to 12 dioptres is usually required, and a

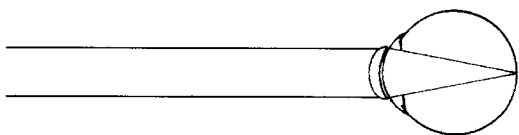


*Fig. 5.5a* The aphakic eye. The image is no longer focused on the retina.


The focus of the eye is restored by:



*Fig. 5.5b* A spectacle lens



*Fig. 5.5c* A contact lens



*Fig. 5.5d* An intraocular lens

*Fig. 5.5* The optical correction of aphakia

lens of the correct power will give the patient excellent visual acuity. Spectacle lenses can be easily and cheaply manufactured, but they have certain disadvantages:-

- *Distortion.* Some distortion occurs with spectacle lenses of strong powers. Objects appear distorted in shape and many patients feel disorientated, for example a door will tend to change shape as a person approaches it.
- *Magnification.* The image that is produced by a positive spectacle lens of about 10 dioptres is one third larger than the image in a normal eye. This magnification occurs because the lens has been removed from its normal position inside the eye, and has been replaced by a spectacle lens which is at least a centimetre in front of the eye. If the two eyes receive images of unequal size this is called aniseikonia.
- *Prismatic Effects.* When the patient looks through the side of strong spectacles a prismatic effect occurs so that the object looked at is not quite where it appears to be.
- *Discomfort.* Aphakic spectacles are heavy and so may be uncomfortable to wear. They are less heavy if they are made in a special shape but this is usually expensive. Plastic lenses are lighter but will scratch more easily.

For these reasons, patients may take some weeks to adjust to wearing spectacles after a cataract extraction. They have to learn to turn their heads rather than their

eyes when looking round, and must get used to the distortion and the magnification which makes judging distances quite difficult at first. However patients who were blind or almost blind before surgery are always delighted to see again, and rarely have real difficulties in getting used to aphakic spectacles. The only patients who do have persistent difficulties are those who have surgery when they can still see quite well, or have had a cataract removed from one eye and have normal vision in the other eye. If a spectacle lens is used to restore the focus in the aphakic eye, then the image in that eye is one third larger than the image in the normal eye. This causes double vision and is very confusing for the patient. It is best not to correct aphakia with a spectacle lens if the other eye is normal. Without spectacles the vision in the aphakic eye will be very blurred and out of focus, but it will not confuse the normal image from the healthy eye.

- “*Wear and tear*”. Besides all these optical problems with aphakic spectacles, there is an even more important practical problem, “wear and tear”. The glasses easily get lost, broken or scratched. This is especially true for people living in rural areas who do not have anywhere safe to put their glasses, and these are the very people who have difficulty in replacing them. Many surveys have shown that large numbers of patients have either lost or broken their glasses or have never been given any. (In some surveys more than half of all patients after simple cataract surgery were not using any spectacle correction!)

(It is always a good idea for a doctor or surgeon to be able to experience what the patient is experiencing. It will both make the doctor more sympathetic to the patient, and also help them to be able to explain to the patient exactly how they will feel after an operation. It is quite easy for a surgeon to experience what it is like to have a cataract operation and to wear corrective spectacles. If the surgeon has access to contact lenses and someone who fits them, then it is possible to get some soft contact lenses made with a very strong negative correction. By wearing these contact lenses, the surgeon will become very hypermetropic, in fact just like a patient who has had cataracts removed but is not wearing glasses. The surgeon can then wear some +10 glasses to correct the refractive error, and in this way experience both what it is like to have had a cataract extraction and have no refractive correction, and also to experience what it is like to have had a cataract extraction and to wear correcting spectacles. The final comparison is to put on a blindfold of thin paper to experience being blind from untreated mature cataract.)

Both contact lenses and intraocular lenses give a much more normal type of vision after cataract extraction than spectacles. A contact lens or an intraocular lens is in almost the same position as the patient's own lens and therefore there is no significant magnification of the image in the operated eye, nor is there any distortion. The lens moves as the eye moves and so gives a much more normal or natural image of the outside world.

### **Contact lenses** (fig. 5.5c)

Contact lenses have been used for some years, they rest on the surface of the cornea and must be fitted very carefully. The contact lens must be not only the right strength but also the right shape to fit exactly on the patient's cornea. If not the cornea can be damaged.



Contact lenses are made from various materials, and new and improved types of contact lens material are continually being developed. Most are known as either hard or soft lenses. Hard contact lenses are a little smaller than the diameter of the cornea and move freely over the surface of the eye. They are often slightly uncomfortable to wear at first and it takes some time to get used to them. However once the patient's eye has adapted to them they are long lasting, easy to wear and are fairly easy to keep clean.

Soft contact lenses are much more comfortable at first, but need much greater care in cleaning and sterilising and easily become scratched or damaged. Soft contact lenses are a little larger than the diameter of the cornea and do not move over the surface of the eye.

It usually takes some time for contact lenses to be fitted properly and for the patient to get used to wearing them. The patient has to learn how to put them in and take them out of the eye, and to clean and handle them properly.

Some years ago contact lenses were used quite often to correct aphakia, especially for patients who had a cataract extraction in one eye and normal vision in the other eye. However, the increasing use of intraocular lens implants has now meant that contact lenses are hardly ever used as an optical correction for aphakia.

### ***Intraocular lenses*** (fig. 5.5d and figs. 5.6 to 5.9)

Intraocular lenses (IOLs) made of high quality non-toxic plastic have been used to correct aphakia for over 30 years. At first there were various problems both with the design of the lens and the materials from which they were made, and in these early years many eyes were damaged or destroyed from the complications of IOLs. Most of these problems have now been overcome, and there is a good understanding of how the IOL behaves inside the eye and what are the best materials and designs. From a patient's point of view a successful IOL implant is by far the best way of correcting aphakia. Virtually normal vision is restored, and there is neither the distortion nor magnification of spectacles, nor the problem of fitting and wearing contact lenses. The IOL is permanent and rests inside the eye where it will neither become scratched nor spoilt. Nowadays in the developed world nearly all patients having cataract extractions receive an IOL.

When the first edition of this book was written ten years ago it was difficult to recommend routine use of IOLs because of their cost. At that time nearly all lens implants were manufactured in western countries and would cost about 100 US \$, an amount which most poor people could not afford. However, high quality lens implants are now manufactured in developing countries and their cost has fallen very rapidly and probably will continue to fall further. At present good quality lens implants can be purchased for about 5 US \$ or sometimes even less. Cost alone is no longer a barrier to carrying out lens implant surgery. An IOL which will last for ever is no more expensive than a pair of spectacles which will need replacing.

Several surveys from different countries have shown that a large proportion of patients who have had simple cataract extractions are not wearing their correcting spectacles for one reason or another. The visual acuity in an eye with uncorrected aphakia is less than 6/60. Therefore although these patients can see to get around, they are in some respects classified as still blind. For these reasons intraocular lens

implants are now being widely promoted as the standard way of rehabilitating patients after cataract extraction throughout the world.

It is important to remember that lens implants can occasionally cause problems:

- Cataract extraction is not an easy operation and inserting an IOL makes it harder, increases the postoperative complication rate, and requires more careful post operative management.
- Patients with chronic uveitis or corneal endothelial dystrophy preoperatively should not be offered lens implants.
- If the operating conditions are not ideal and there is a risk of infection, that risk is much greater if an IOL, which is a foreign body, is left inside the eye.
- If the IOL is badly handled or inserted it will seriously damage the endothelial cells of the cornea, causing bullous keratopathy and permanent loss of sight.
- Cataract surgery without implanting an IOL can be performed without the aid of an operating microscope, but this is very difficult with the best type of intraocular lens implant, a posterior chamber implant.

*In surgery it always better to be safe than sorry. Therefore IOLs may not be indicated for any of the reasons listed above.*

Lens implant surgery is undoubtedly the best way of treating cataracts, and it is now extremely cost-effective. However, a surgeon who is practising good quality routine cataract surgery without implants, and has a good system for providing low cost spectacles post-operatively, may still be giving a good and valuable service to the community, and should not necessarily be criticised. However in this situation the surgeon would be advised to get training in lens implant techniques. The old proverb “the best is the enemy of the good” is very true when trying to plan a service to eradicate cataract blindness. At present there are still many countries and many areas where most people get no treatment at all for cataract, and these patients would be grateful for any treatment.

### ***The design of intraocular lenses***

All IOLs have two different parts. The central part is called the “optic”. This is the lens part which focuses the light on the retina, and has a diameter of 5 to 7 mm. The outer part is called the “haptic” which secures the lens in the eye, so that it does not move or irritate any of the intraocular structures. Most lenses are made of polymethyl-methacrylate (PMMA), which has been used for over 20 years. Nowadays other materials such as silicone and acrylic are also available. The main advantage of silicone and acrylic is that they are softer and so a larger lens can be folded over and inserted through a much smaller incision. These lenses are only used in phakoemulsification surgery, and at present are much more expensive than those made from PMMA which is a solid non-foldable material. Therefore only the use of rigid PMMA lenses will be described in this book.

In most cases the haptics are also made of PMMA, and because the haptics are very thin they are slightly flexible. Ideally the haptics and the optics are made out of one solid piece of PMMA, but it is possible to make the haptics separately and then fix them to the optic in the factory. The haptics can be made from a

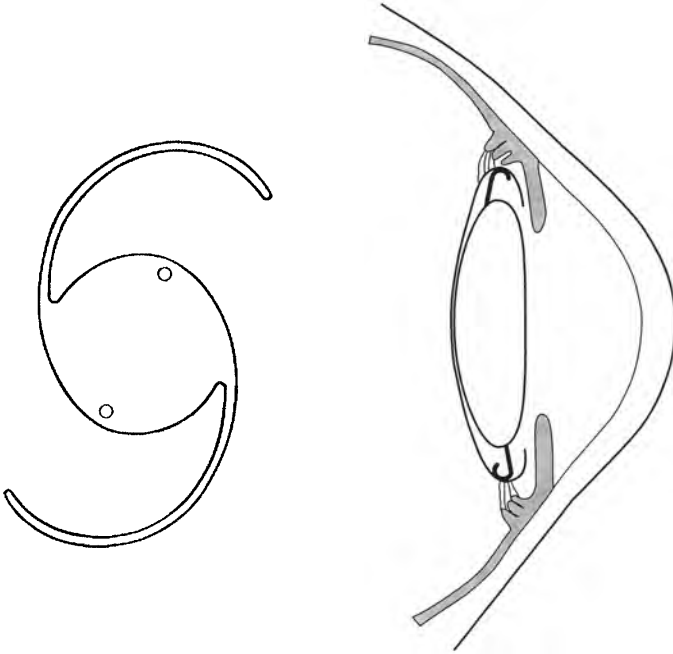
different material such as polypropylene. (However, a lens made out of one single piece of PMMA is usually the best quality and this is now the standard way of manufacturing lenses.)

There are 4 different places where the IOL can be fixed inside the eye:

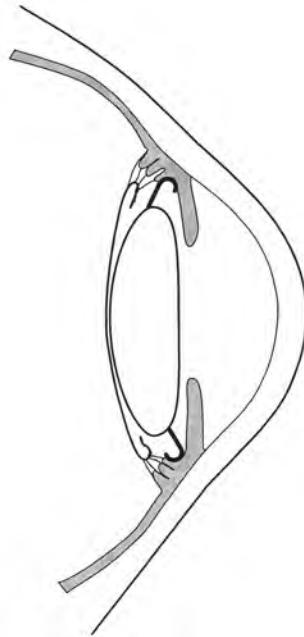
1. *In the posterior chamber* in front of the posterior lens capsule and behind the iris (fig. 5.6). This is generally considered the best place as the lens is fixed very securely, and it is also well away from the sensitive endothelial cells on the posterior corneal surface. These cells can be easily damaged by badly fitting lenses in the anterior chamber. Most posterior chamber lenses now have a fairly standard design. The haptics are angled slightly backwards so that the lens tends to press against the posterior lens capsule, and the optic has a convex curve on its posterior surface which also helps to keep the lens resting tightly against the posterior lens capsule. Many posterior chamber lenses have two small dialling holes at the outer edge of the optic. The purpose of these dialling holes is to make it easier to insert the IOL. There are however two disadvantages in having dialling holes. If the lens becomes decentred slightly, the dialling hole can come into the visual axis and may slightly disturb the vision. Also the dialling hole may become an isolated space where bacteria of low virulence can survive isolated from the body's defences, and these can cause a chronic persistent inflammation in the eye after lens implant surgery. It is fairly easy to insert an IOL without a dialling hole if the haptic loops have the right amount of flexibility. Therefore dialling holes are becoming less common as IOL design improves, but lenses with dialling holes are easier to insert.

The haptic may be within the lens capsule so that it rests in front of the posterior capsule but behind the rim of the anterior capsule (fig. 5.6). This is sometimes called "*in the bag*" fixation. Alternatively the haptic may rest in front of the rim of the anterior capsule but behind the iris (fig. 5.7) in the ciliary sulcus. This is sometimes called '*sulcus*' fixation. "*In the bag*" fixation is generally considered as slightly better than "*sulcus*" fixation, because the lens is more stable and the haptic is protected from touching the rest of the eye by the lens capsule. However in practise there is little difference between the two positions. Sometimes the haptics can be placed very carefully "*in the bag*", and yet some months later one or both the haptics may have moved spontaneously into the sulcus. Post-operative fibrosis and contracture in the capsule can cause the haptics to move in this way.

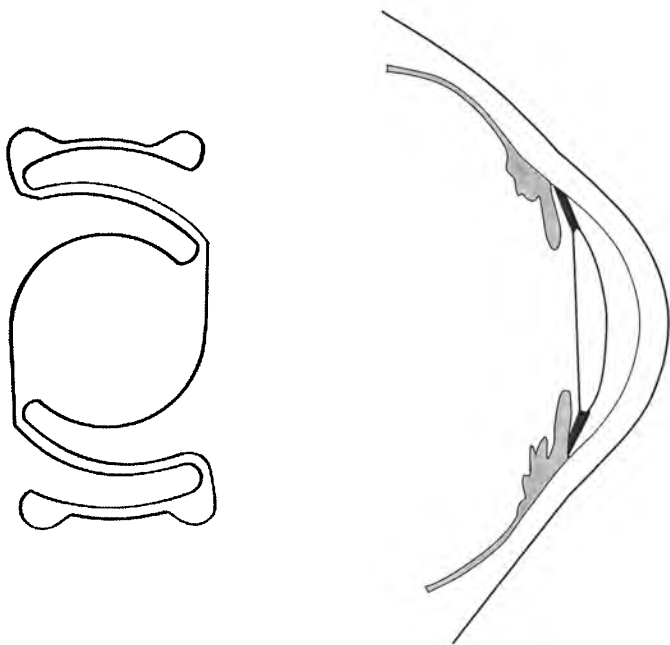
2. *In the anterior chamber*. If the patient has had an intracapsular cataract extraction, a posterior chamber lens implant cannot be used because there is no supporting posterior capsule present. The lens implant would just fall back into the vitreous. In most cases the lens is implanted into the anterior chamber (fig. 5.8). The haptics of an anterior chamber lens implant are slightly more complicated. The most acceptable design for the haptics is shown in fig. 5.8 so that the haptics touch the anterior chamber angle between the iris and the cornea in four places. (One alternative design has a three point fixation, two in the lower angle and one above.) Therefore anterior chamber lenses must have the correct power of the optic and also the correct diameter of the haptics. If the



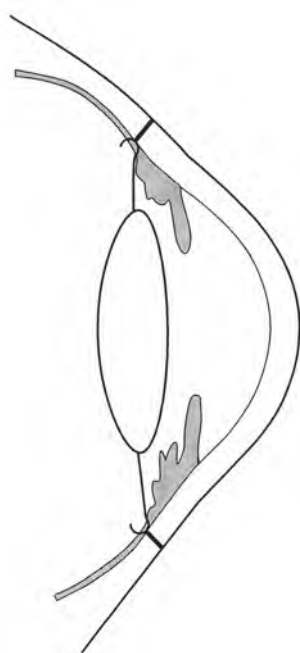
*Fig. 5.6* A posterior chamber lens implant used with extracapsular extraction (not all posterior chamber lenses have the small dialling holes shown here)



*Fig. 5.7* A posterior chamber lens with the haptics in the ciliary sulcus. Note how the haptics are in a slightly different position from those in Fig. 5.6



*Fig. 5.8* An anterior chamber lens implant used with intracapsular cataract extraction



*Fig. 5.9* A scleral fixated lens. The haptics are secured with sutures which pass through the sclera but the knots must be buried

haptic size is too small then the lens will not fit firmly into the anterior chamber angle. It will therefore be unstable and move around and destroy the endothelial cells of the cornea. These are the most vital cells in the cornea and never regenerate if destroyed. If the lens is too large then it will press too hard in the angle of the anterior chamber and cause pain, discomfort and irritation. Even a perfectly fitting anterior chamber lens will probably cause some very gradual loss of the endothelial cells because the haptics touch the peripheral cornea. There may also be some slight constant rubbing of the lens against the iris causing iritis. (In the early designs of anterior chamber lenses there was a common complication called the UGH! syndrome. This stood for Uveitis, Glaucoma, and Hyphaema.) With modern designs these problems are much less, but the anterior chamber is still not the ideal place for a lens implant. For all these reasons anterior chamber lenses should only be used in elderly patients. They should never be used in patients under 60 and only with caution in patients under 70. Other designs of anterior chamber lenses are available, but these may cause even more damage to the endothelial cells of the cornea.

3. *Iris or pupil fixated lenses.* In the early years of intraocular lens implants it was popular to fix the intraocular lens within the pupil, with two haptic loops behind the iris and two in front of the iris. This design unfortunately did not stand the test of time, because many of these lenses were found to rub against the endothelial surface of the cornea when the eye moved, causing endothelial cell loss. Sometimes the lens became unstable and fell into the vitreous. There is however one type of iris fixation which has stood the test of time. This is called the “lobster claw” lens which fixes firmly on to the anterior surface of the iris. Although it is probably a good design it is not very popular or widely available and so will not be described any further.
4. *Scleral fixation.* This is a way of inserting a posterior chamber lens behind the iris when there is no posterior capsule to support it. The anterior vitreous is removed with a vitrectomy machine and the haptics of the lens secured through the pars plana to the sclera with non-absorbable, non-irritant sutures (fig. 5.9). This is a good way of securing the intraocular lens in young patients who do not have a posterior lens capsule and so cannot have a standard posterior chamber lens. The technique and insertion is a little more difficult, but is described briefly at the end of this chapter on page 178.

## ***Choosing the power of an intraocular lens***

### ***Ocular Biometry***

The best power for an intraocular lens (IOL) is the one that will make the eye very slightly myopic (about 0.5 to 1.0 diopter), so that the patient can see fairly well for both distance and near without needing spectacles. Ocular biometry measures the eye so that the correct power of IOL is used. It measures the curvature of the cornea and the axial length of the eye, and with this knowledge the correct power of the lens can be calculated.

There is one other factor which affects the power of an IOL, its position inside the eye. The further forward the IOL rests in the eye, the greater is its effective power. The position that the IOL tends to rest in the eye is measured by a number

called the “A” constant. A lens with a high “A” constant rests far back in the eye, and a low “A” constant lens will rest further forward. Posterior chamber lenses have an “A” constant of about 118, and anterior chamber lenses an “A” constant of about 115. In practice this means that a posterior chamber lens must have a power of about 3 diopters more than an anterior chamber lens to have the same effect. When carrying out ocular biometry, the “A” constant for the lens to be inserted is also taken into account.

When choosing the power of the IOL the refraction of the other eye is also important, especially if only one eye is being operated on. For example if the other eye has 6 diopters of myopia what should be the ideal refraction in the operated eye? The most accepted solution is to plan for a refractive error of about half that of the other eye, 3 diopters of myopia in the case described.

Another factor is the occupation of the patient. Someone doing a lot of close work may prefer to be myopic, and someone working outside may prefer to be emmetropic.

#### *“Best Guess” for IOL power*

If ocular biometry is not available, the surgeon must guess the best strength of IOL. A posterior chamber lens of about 21 diopters should make a normal eye remain emmetropic postoperatively. One extra diopter of IOL power usually changes the refraction of the eye by about 0.5 diopter. Therefore a normal eye with a 23 diopter IOL should have a refraction of minus 1.0 post-operatively. This is one diopter of myopia which is the ideal. For anterior chamber lenses, 18 diopters should make the normal eye emmetropic, and so a lens of about 20 diopters should be chosen which will result in a refraction of minus 1.0.

The guesswork may be aided by knowing the patient’s preoperative refraction. If the patient was myopic before the operation, a lens of less power will be needed, and a very myopic patient (e.g. minus 20) does not need an IOL at all to become emmetropic postoperatively. (The exception to this is a patient who was myopic preoperatively because of nuclear sclerosis of the lens). Hypermetropic patients will usually require an IOL of increased power to make them emmetropic. These kind of guesses are not needed if biometry is available.

## **Indications for Surgery**

At what stage should a cataract be removed? Often this is an easy decision to make. It may be obvious that a particular patient needs a cataract operation, or that another should not have an operation. However, the decision is not always easy and there are several factors to consider.

1. Is an intraocular lens implant planned?
2. How bad is the cataract?
3. What kind of vision does that patient need?
4. Is there evidence of other disease in the same eye?
5. What is the condition of the other eye?
6. What facilities are available ?



### 1. *Is an intraocular lens implant planned?*

Cataracts can be removed at an earlier stage if an IOL is planned because this gives much more natural restoration of vision. This is particularly true if a patient has a cataract in one eye and the other eye is fairly normal. Such a patient would gain very little from cataract surgery without a lens implant. By operating on patients at an earlier stage in their disease it means that they are much less handicapped, and no longer must surgeons wait until the cataract is mature. However this policy also means there is much more cataract surgery to be done in the world.

### 2. *How bad is the cataract?*

A brief revision of the anatomy of the lens may be helpful. The lens is enclosed in a membrane called the *capsule*. This is attached to the suspensory ligament at its most peripheral part, the equator. Inside the capsule is a thin layer of fairly soft lens fibres called the lens *cortex*, but most of the bulk of the lens is made up of much harder lens fibres closely packed together and called the lens *nucleus*. In young children all the lens is soft and there is no nucleus. With increasing age the adult nucleus gets harder and bigger, occupying a greater proportion of the lens.

The opacity or cataract may develop in the nucleus which turns brown, and finally black. It may develop in the cortex which turns white and opaque, or it may develop as an opaque layer just in front of the posterior capsule. This is called a posterior subcapsular cataract, and it causes a particularly marked loss of vision. Often more than one type of cataract may occur in the same lens, and there are other less common types of cataract also.

In the early stages of cataract the patient may see fairly well, and only notice some dazzling or blurring of vision. This is called an *immature* cataract. Gradually, as the cataract becomes more dense and opaque, the vision deteriorates until the patient is blind, and can only perceive and point out the direction of bright lights. This is called a *mature* cataract.

After this, further degenerative changes may take place in the lens. The lens cortex may become liquid making the lens swell. This is known as an *intumescent cataract*. The lens swelling will make the anterior chamber shallow and may cause secondary angle-closure glaucoma.

Rarely the lens capsule may rupture spontaneously or leak. The fluid from degenerated lens protein passes into the anterior chamber where it usually causes severe uveitis. This is called *phakolytic uveitis*. The lens protein often blocks up the drainage angle of the anterior chamber causing *phakolytic glaucoma*. Eventually a shrivelled lens capsule and a small nucleus are all that remain, but by this stage the eye has often gone blind from the complications of uveitis or glaucoma.

Most cataracts get worse gradually but the speed with which they do so is variable. The patient may go from having perfect vision to complete blindness in a few months. Usually the process takes a few years, but occasionally cataracts may hardly progress at all or be completely static.

*At what stage should the cataract be removed?*

- An *intumescent cataract* should be removed as soon as possible, because of the risk of angle closure glaucoma.
- In cases of *phakolytic uveitis* intensive topical steroid treatment should be given and the cataract removed as an emergency.



- A *mature cataract* should also be removed but if the other eye is completely normal, the improvement in the patient's vision will be limited without an intraocular lens implant.
- For *immature cataracts* the decision to operate or not depends very much upon the patient's visual needs and life-style. The use of intraocular lens has meant that immature cataracts are now being operated on at a much earlier stage. Without a lens implant there is not much advantage to the patient in having a cataract extraction until the visual acuity has fallen to about 6/60. However with a lens implant many surgeons would recommend a cataract extraction with a visual acuity of 6/18. The most modern technique of phakoemulsification can produce such good results that some surgeons are even recommending an operation with a visual acuity of 6/9!! Besides causing a loss of visual acuity the cataract can cause other visual symptoms such as glare in bright light, or "ghost" images which may be quite disturbing. Having these symptoms will also affect how soon the cataract is removed.

### ***3. What kind of vision does the patient need?***

Obviously everyone wants the best vision possible. However a moderate amount of visual loss (e.g. a visual acuity of 6/18) for someone who needs to read fine print or drive a car could mean having to stop work, but for an elderly, illiterate farmer or housewife it would not be a very great handicap. In general, the time for cataract surgery is when the patient can no longer see well enough to carry out his or her normal activities.

### ***4. Is there evidence of other disease in the same eye?***

Cataract extraction is most likely to be successful if the rest of the eye is healthy. There are five simple tests to confirm this.

**Pressure** – check the intraocular pressure.

**Pupil** – o check the pupil reaction to bright light.

**Projection** – recognising the direction of a light.

**Posterior part of the eye** – check the retina and the optic nerve.

**Pin-hole** – does the visual acuity improve with a pinhole.

1. *Pressure.* At a routine eye examination the intraocular pressure should be checked. If raised, it indicates glaucoma and it is quite likely that the loss of vision is due to glaucomatous optic atrophy and not to the cataract. Even if it is decided to remove the cataract, the operation may need to be modified to treat the glaucoma at the same time.
2. *The pupil light response.* A brisk pupil light reaction is excellent confirmation that the eye is otherwise healthy. An absent or poor reaction usually indicates that the retina or optic nerve is diseased especially if the pupil light response is normal in the opposite eye. Sometimes in elderly patients or following iritis or other abnormalities of the iris the pupil reaction may be diminished. Therefore a good pupil reaction is a reliable sign that the rest of the eye is healthy, whereas an absent pupil reaction is very suspicious of retinal or optic nerve disease but does not necessarily confirm it.

However an afferent pupil defect (sometimes called a Marcus–Gunn pupil reaction) in the eye with the cataract indicates that there is other serious disease in the eye as well as cataract.

3. *The projection of light.* When the retina and optic nerve are healthy, a patient with even a dense cataract can still tell the direction from which a bright light is coming when shone into the eye. There are some useful variations of this test. One is to shine two lights held about 15 cms. apart from each other into the eye. A patient with a healthy retina should be able to discern that there are two lights and not one. Another is to shine a bright light into the eye through a special lens called a “Maddox Rod”, which is usually a part of a standard trial set of lenses. The patient will see a red line through this lens. If for example the patient has macular degeneration, the central part of this red line will either not be seen at all or will be all broken up and distorted.
4. *The posterior part of the eye (retina and optic nerve).* If the patient has a mature cataract, it is not possible to examine the retina and the optic nerve at all. If the cataract is only partial then the pupil should be dilated with mydriatics to examine the retina and optic nerve with an ophthalmoscope. (In patients with an immature cataract this can be done more easily with an indirect than a direct ophthalmoscope, or with a 90 dioptre lens and a slit lamp.) If there is evidence of another disease and the cataract is only partial, then cataract extraction will probably not benefit the patient very much.

In doubtful cases the surgeon needs to examine the red reflex from the fundus and compare this with the loss of visual acuity. If the red reflex is only slightly obscured, then the loss of visual acuity should also be fairly slight.

5. *The pin-hole visual acuity test.* This may give helpful information in patients with an early cataract. An early cataract causes the light to be scattered so that there is no clear image on the retina. Looking through a pin-hole cuts down the scattering of the light, and so the visual acuity improves with a pin-hole. This also confirms that the retina is healthy (remember that refractive errors and corneal irregularities will also cause visual loss which improves with a pin-hole).

## **5. What is the condition of the other eye?**

There are 4 basic possible conditions of the other eye, although every case may not fit exactly into one of these groups.

1. The other eye is normal (a unilateral cataract)
2. The other eye also has a cataract (bilateral cataract)
3. The other eye has had a successful cataract extraction (a second eye cataract)
4. The other eye is incurably blind (an only eye cataract)

*The other eye is normal* (a unilateral cataract)

This is a strong indication for an intraocular lens implant, because a cataract extraction without a lens implant will only give very limited improvement to the

vision. However it may be worth operating on such an eye even without a lens implant for three reasons:

- The patient's field of vision will improve.
- There is a risk that the cataract may become hypermature or intumescent in the future, and so removing the cataract will prevent the possibility of these complications.
- Cataract will usually develop in the other eye at some time in the future. Very often there may be early signs of this if the other eye is examined closely. In such cases the vision in the other eye is likely to deteriorate and the patient will then see well out of the operated first eye by using aphakic spectacles.

#### *The other eye also has a cataract (bilateral cataract)*

In this situation cataract extraction should be performed if the patient's sight is bad enough and the cataracts are dense enough. Most people would advise operating on one eye and waiting until it was free of immediate post operative complications before considering an operation on the second eye. However removing both cataracts at the same time is carried out by some surgeons.

#### *The other eye has had a successful cataract extraction (second eye cataract)*

This is the ideal case for surgery. The patient has already experienced the benefits of one operation, and will be enthusiastic about the second. In any surgical unit which is involved in training, this is the ideal operation for the trainee to perform under supervision.

#### *The other eye is incurably blind (only eye cataract)*

This is the hardest situation for cataract surgery, because the patient has everything to lose if things go wrong but everything to gain from a successful operation. The level of anxiety is likely to be high both in the patient and the surgeon. These cases should only be operated on by an expert unless there are exceptional circumstances. Patients with only one eye will often not consent to cataract surgery until the eye is completely blind. Also, most surgeons are naturally reluctant to operate on an only eye. Always try to discover why the first eye went blind. It may give useful information in planning the operation. For instance, there may be an untreatable retinal detachment in the first eye, this will be a strong indication for doing an extracapsular rather than an intracapsular cataract extraction on the remaining eye.

### **6. What facilities are available?**

In developing countries good surgical treatment is often not available locally. It may be difficult to decide whether to operate on a blind patient near his home where the facilities are not ideal but the patient is in familiar surroundings, or whether to send the patient many miles to a specialised eye unit. In general, the results of cataract surgery by even relatively inexperienced eye surgeons are fairly good provided that basic surgical principles are followed carefully. However, a young patient who is blind with cataracts or an only eye cataract should be left to an experienced surgeon, with the best possible facilities and support.

Having collected all this information, the surgeon must now decide whether or not to recommend surgery. Usually the decision is straightforward, but some cases are doubtful or uncertain. It is always a good policy to warn patients about the risks of surgery, but especially in uncertain cases where the patient has less to gain and more to lose.

**The Choice of Operation**

The technology of cataract surgery has been very rapidly progressing and changing as described earlier in this chapter. In developing countries the most modern operation may not always be the most appropriate. The choice of operation for cataract depends on several factors:-

<i>Extracapsular or intracapsular extraction?</i>
<p><b>Extracapsular</b></p> <p><i>Advantages:</i></p> <ol style="list-style-type: none"><li>1. Better fixation for IOL implants with less complications.</li><li>2. Less postoperative cystoid macular oedema and much less retinal detachment.</li><li>3. The possibility of small incision and sutureless surgery.</li><li>4. Less risk of disturbing the vitreous.</li></ol> <p><i>Disadvantages</i></p> <ol style="list-style-type: none"><li>1. Microscope with coaxial illumination required</li><li>2. Posterior capsular thickening may occur postoperatively</li><li>3. More postoperative uveitis.</li></ol>
<p><b>Intracapsular</b></p> <p><i>Advantages:</i></p> <ol style="list-style-type: none"><li>1. No microscope needed</li><li>2. No posterior capsular thickening</li><li>3. Reasonable results with anterior chamber IOLs in elderly patients</li></ol> <p><i>Disadvantages:</i></p> <ol style="list-style-type: none"><li>1. Higher risk of cystoid macular oedema and retinal detachment postoperatively</li><li>2. Larger incision and more astigmatism</li><li>3. More complications with IOLs, especially long term complications</li><li>4. Greater risk of vitreous loss during the operation</li></ol>

*1. The equipment available*

The most modern treatment for cataracts, phakoemulsification, uses very expensive equipment and the surgeon requires lengthy practical “hands on” training. A

more simple conventional extracapsular cataract extraction can be performed to a very reasonable standard with fairly basic and simple equipment, as long as an operating microscope with co-axial illumination is available. This method of surgery is now being promoted in most developing countries and by most international agencies concerned with blindness prevention and treatment. Where a microscope is not available an intracapsular extraction is probably a better choice.

## *2. Is an IOL implant planned?*

One of the main advantages of extracapsular extraction is that it is the best type of operation for implanting an IOL. If a lens implant is not planned or not available then the advantages of extracapsular extraction are less, except for young or myopic patients. Extracapsular extraction has a much smaller risk than intracapsular of a retinal detachment and cystoid macular oedema post-operatively. However extracapsular extraction has a greater risk of post-operative uveitis, and thickening of the posterior lens capsule post-operatively is quite common. This is not a problem if YAG lasers are available to treat capsular thickening, but many places do not have a laser.

Intracapsular extraction also has certain practical advantages especially where the surgical facilities are not very good, as an operating microscope is not necessary. It is possible to insert an anterior chamber IOL following intracapsular cataract extraction but the fixation and the position of the lens is less satisfactory.

## *3. The age of the patient*

Young patients must be treated by extracapsular extraction and in middle-aged patients extracapsular extraction is preferable. A middle-aged patient (40–60 years old) can have a satisfactory intracapsular cataract extraction, but anterior chamber lens implants are not generally recommended in this age group. There is also the risk of retinal detachment after intracapsular extraction. (A 50 year old patient may have 30 years of future life, and so three times the risk of a retinal detachment compared with a person with 10 years of future life). Cataracts in elderly patients can be removed perfectly satisfactorily by either the intracapsular or extracapsular technique. In the developed world intracapsular extraction is considered an obsolete operation nowadays, but this may not be true for developing countries. Indeed trials are being held to try to compare the results of intracapsular extraction plus an anterior chamber implant, with extracapsular extraction plus a posterior chamber implant.

## *4. Other factors*

Apart from young patients, extracapsular extraction is also the choice in patients who are myopic or who have had a retinal detachment in either eye. These patients have a much greater risk of developing retinal detachment following intracapsular cataract extraction.

A subluxated or dislocated lens should be treated by an intracapsular extraction. Sometimes these eyes have a poor prognosis because there may be other complications present.

## **Surgical Technique**

### ***Preparing the eye***

After the local anaesthetic has been given, the eye-lids and conjunctiva cleaned and surgical drapes applied, the eye is ready for operation.

First the eye-lids must be retracted. This can be done with eye-lid sutures or a speculum. Most surgeons prefer a speculum. There are many different designs but it is important that the speculum does not press on the eye or get in the way of the operation. The speculum shown in fig. 2.4, page 20 is very satisfactory. A slightly heavier speculum in fig. 2.3, page 20 can press on the eye. However it can have an advantage if an assistant is available to gently lift up the speculum if required. This tends to create a negative pressure in the eye and can be of help if there is slight pressure on the eye. As the speculum is lifted, the intraocular contents will fall back making more space in the anterior chamber, and lessening the risk of vitreous loss, or posterior capsule rupture.

Before starting the operation check again that the local anaesthetic nerve blocks have worked well:-

The patient should not be able to close the eye. If the eyelids can close strongly the facial block must be repeated.

There should be little or no movements of the eye ball on attempting to look in different directions. If there are good ocular movements then the retrobulbar block must be repeated, or a sub-Tenon's block given as well (see page 69).

Slight residual movements in the orbicularis oculi muscle which closes the eye-lids, or in the extraocular muscles moving the eye are acceptable, but the importance of a good local anaesthetic block cannot be emphasised too strongly. The most common cause of complications and difficulties during intraocular surgery is a poor local anaesthetic block. The speculum is inserted to hold open the eye-lids but not to force them apart.

Most surgeons now insert a superior rectus suture, this rotates the eye down and improves access to the upper limbus where the incision is made into the eye. The superior rectus suture should not be used to hold down an eye which is turning up because of an inadequate local anaesthetic block. The technique of superior rectus suture insertion is described on page 21–2. In difficult cases a superior and also an inferior rectus suture can be inserted. These will hold the eye very steady, and also bring it forward a little.

If the palpebral fissure is small, access may be improved with a canthotomy (see page 21). This is more often needed in patients from S.E. Asia who tend to have smaller palpebral fissures.

## **Extracapsular Cataract Extraction**

In extracapsular cataract extraction the anterior lens capsule, the lens nucleus, and the lens cortex are all removed, leaving the posterior lens capsule and suspensory ligament intact. (The technique described here is the simplest and easiest way of extracapsular extraction, using a fairly large incision into the eye. Small incision surgery, which is harder, is described later on page 122.)

### ***The steps of extracapsular extraction***

1. Starting the incision
2. The capsulotomy
3. Hydrodissection of the lens
4. Completing the incision
5. Expressing the nucleus
6. Irrigation/aspiration of the remaining lens cortex
7. Inserting the Intraocular lens
8. Wound closure and final irrigation/aspiration

### ***The incision into the eye***

The incision into the eye can be made in the sclera, at the limbus where the cornea meets the sclera, or in the cornea.

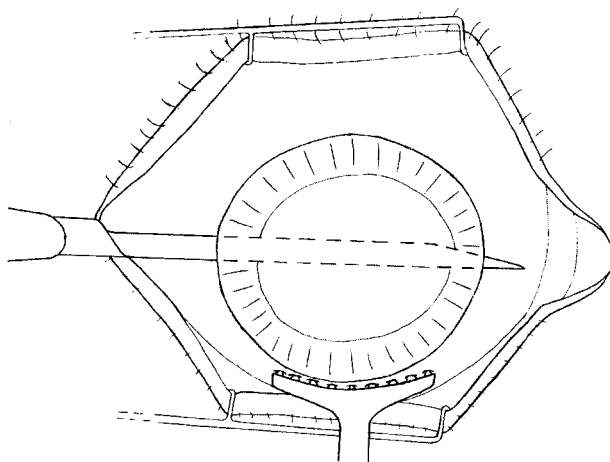
#### ***Scleral incisions***

Incisions in the sclera will bleed excessively, and some dissection is needed to reach the anterior chamber of the eye. Therefore a limbal incision is usually preferable.

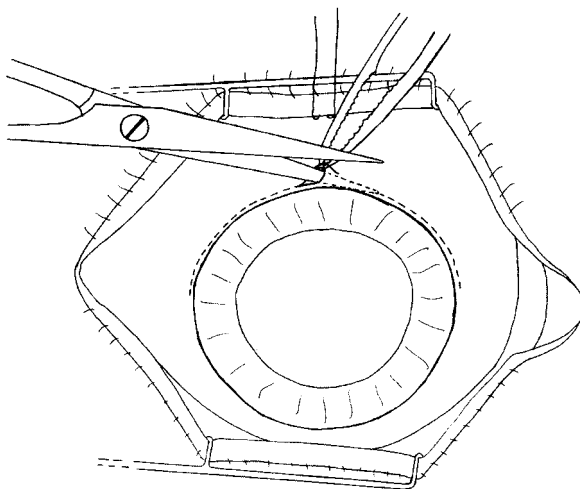
#### ***Limbal incisions***

Most people recommend that the incision should be at the limbus just under the conjunctiva. Here the sutures become buried under the conjunctiva and do not cause problems or inflammation later on. The surgical anatomy of the limbus is described in detail on page 23–25 and the student may like to revise this.

The incision can be made with a sharp pointed knife called a Graefe knife (fig. 5.10). As long as both the point and the blade of the knife are extremely sharp



*Fig. 5.10* A Graefe knife incision



*Fig. 5.11* The start of a fornix based conjunctival flap and showing the line of the incision

it is a very quick, neat and effective way of making the incision as the wound has a small shelf to it. It also heals well and securely. However, it needs both experience and a very sharp knife to make a successful incision. Bad mistakes can be made if the incision is not done properly and so this technique will not be described in detail.

A slower but safer method is to use a small sharp knife such as a razor blade fragment or a Bard-Parker scalpel (No. 15) to make an incision from the outside of the eye. (Razor blades made from carbon steel will easily snap obliquely to make sharp knives, but razor blades made from stainless steel will not snap as they are too flexible.) The incision is usually started with a knife and completed with scissors, or the entire incision can be performed with a razor blade. The method is as follows:

1. *Dissecting back the conjunctiva.* A small flap of conjunctiva and Tenon's capsule is dissected back to bare the limbus.

Either a limbus-based or fornix-based flap may be used (see p.26). Fornix-based flaps heal better as they do not interrupt the blood supply to the conjunctiva, so this method will be described. Grasp the conjunctiva gently with non-toothed forceps near the limbus and make a tiny hole in it with sharp scissors. Insert one blade of the scissors through this tiny hole and cut through the conjunctiva keeping as close to the cornea as possible (fig. 5.11). Usually and especially in elderly patients, the conjunctiva will retract very easily leaving about a 3 mm gap. If it will not retract it can be dissected back a little by cutting the attachments between the conjunctiva and Tenon's capsule to the sclera.

2. *Haemostasis.* When the conjunctiva can be retracted about 3 mm back, any bleeding points or large blood vessels in the limbal area should be sealed by applying very light cautery or diathermy (fig. 5.12). Do not burn or char the tissues as this prevents wound healing. Take particular care with haemostasis at



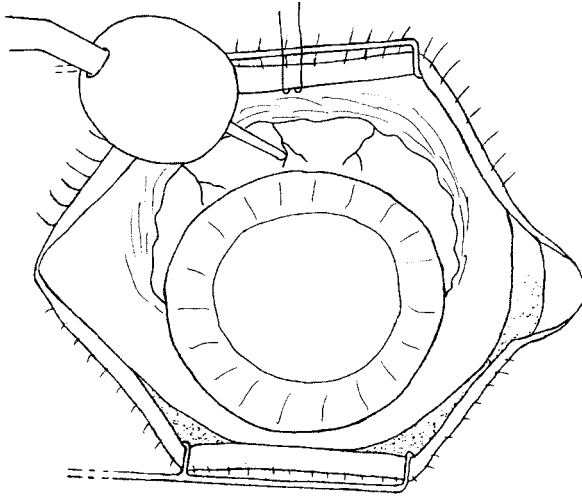


Fig. 5.12 Using a “hot point” cautery to achieve haemostasis

the two ends of the incision at “2 o’clock” and “10 o’clock” position. There may be numerous small conjunctival blood vessels there, especially if the patient has a small pterygium.

3. *The incision into the eye.* This can now be made where the grey limbal tissue meets the opaque white sclera, which is about 1 mm from the edge of the clear cornea and the attachment of the divided conjunctiva. (Page 23–25 describes in detail the exact anatomy of the limbus.) The size of the incision should be about 140 degrees of the circumference of the eye for an extracapsular extraction, significantly less than half way round the cornea (fig. 5.13).

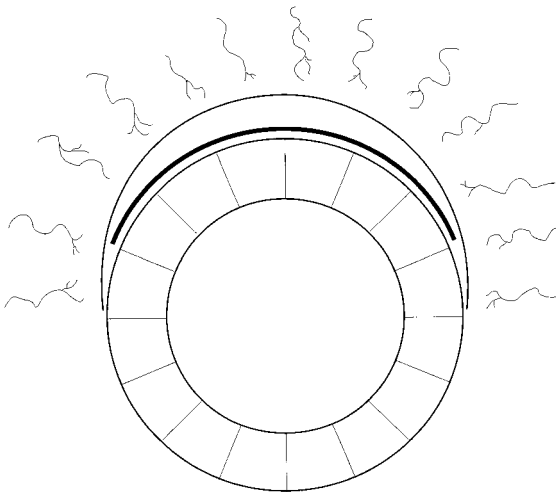

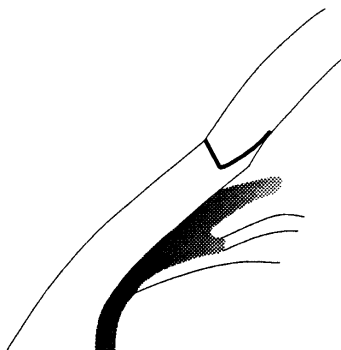


Fig. 5.13 To show the size and position of the incision for extracapsular extraction

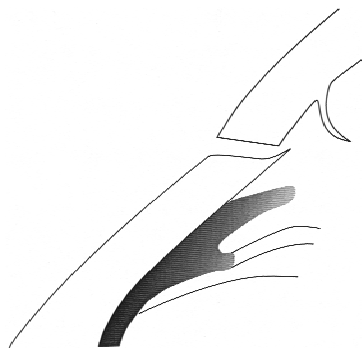*Fig. 5.14* An incision straight through into the anterior chamber. An incision shaped like this can easily leak



*Fig. 5.15* An incision with a “shelf”. This shape of incision is more watertight



*Fig. 5.16* Stripping up of Descemet’s membrane



The shape of the incision should be designed so as to make a wound which is as secure as possible and self-sealing. If the incision goes straight through into the eye (fig. 5.14) and the eye pressure rises postoperatively the wound can easily leak, but if the incision has a “shelf” (fig. 5.15) and the eye pressure rises the wound will tend to seal itself. Another advantage of the wound shown in fig. 5.15 is that the internal opening into the eye is well away from the trabecular meshwork through which the aqueous drains out of the eye. The shelf also helps prevent the iris prolapsing out from the wound during the operation which can be awkward. One slight problem to guard against with a shelving incision is a stripping of Descemet’s membrane from the inside of the cornea (fig. 5.16). It occurs if the knife blade is not sharp or if the incision is shelved too much. The Descemet’s membrane usually

sticks back by itself postoperatively, but if some corneal endothelial cells are lost, there may be a localised area of corneal oedema.

The incision starts with a cut that goes about half the depth into the sclera and at 90 degrees (perpendicular) to its surface (fig. 5.17a).

Here are some hints for a good neat, clean incision:

- Make sure that the knife is sharp.
- Make sure that the eye is grasped firmly with sharp-toothed dissecting forceps.
- Make sure that the blade of the knife is at the correct angle to the eye (figs. 5.18 and 5.19).
- Try to cut perpendicular to the surface of the eye (fig. 5.17a) and plan to cut half way through the depth of the sclera.
- Try to make one or at the most two firm cuts rather than a lot of small scratches.

If the incision is too deep and enters the anterior chamber at this stage it is not a serious problem. However once the anterior chamber has been opened, aqueous will leak out and the eye becomes soft which makes it more difficult to continue to incise the eye from outside using the knife. Also if the incision goes right through into the anterior chamber it means that the shape of the incision is not ideal for producing a shelved secure wound.

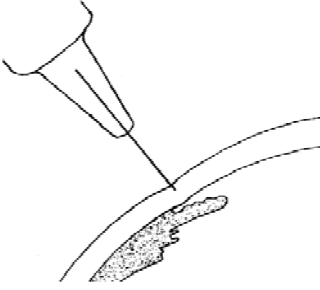
Once a half thickness groove has been made into the sclera the incision is deepened to enter the eye. The angle of the knife to the surface of the eye should be changed to point obliquely into the eye (fig. 5.20) in order to make a secure shelved wound. Alternatively the incision can be completed with a small angled keratome (fig. 5.53c). These are now readily available because they are used for phakoemulsification incisions.

Another way of constructing a secure wound is to make the first part of the incision halfway through the depth of the sclera. Then advance the incision into the cornea and make the second half of the incision straight down into the anterior chamber (fig. 5.21).

Once a small entry site has been made into the anterior chamber, it is usual to carry out the anterior capsulotomy and the hydrodissection of the lens. These are the first two steps of an extracapsular cataract extraction, and they can be performed more easily through a small incision so that the anterior chamber stays formed. This also protects the cornea. Then the wound is fully opened up (see page 106) and the rest of the cataract extraction performed. Alternatively the capsulotomy needle can be mounted on a 2 ml syringe with irrigating fluid, and pushed through the groove of the incision before the eye is opened. In this way the capsulotomy can be done through a watertight incision.

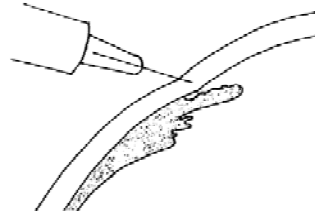
### *Corneal incisions*

Incisions further forward in the cornea are quick and bloodless, which is an advantage. However they do not heal so well and they will tend to cause more



### Correct

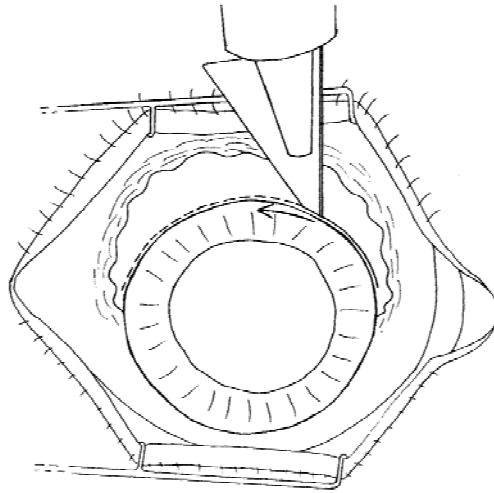
*Fig. 5.17a* The knife blade at the correct angle perpendicular to the surface of the eye



### Incorrect

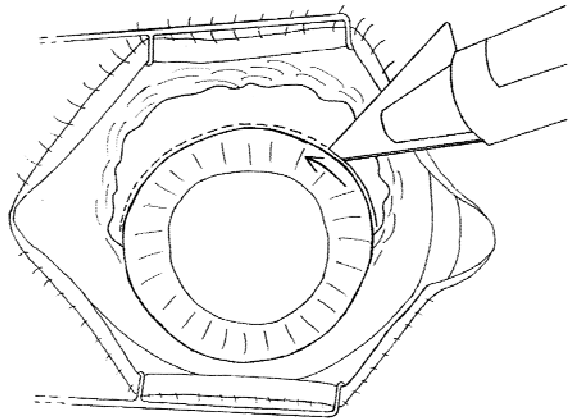
*Fig. 5.17b* The knife blade is not perpendicular to the surface of the eye

### Correct

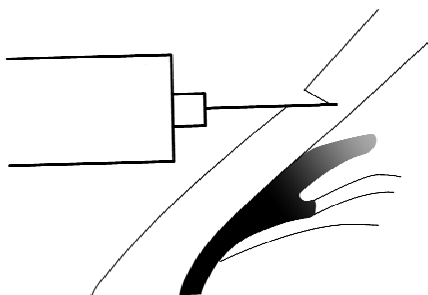


*Fig. 5.18* The incision into the eye using a razor blade fragment. Note the cutting edge of the knife is angled towards the direction in which the blade is moving

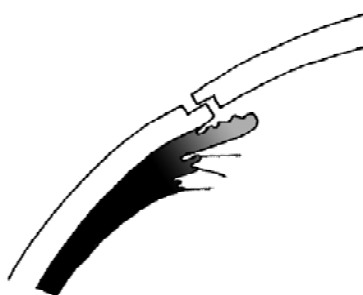
### Incorrect



*Fig. 5.19* The cutting edge of the knife is angled away from the eye and so will not cut effectively



*Fig. 5.20* The angle of the knife to complete the incision into the eye



*Fig. 5.21* An incision with a "shelf"

post-operative astigmatism because the incision is nearer the optic axis of the eye. In particular there may be problems from sutures with corneal incisions. If there are knots or suture ends left on the surface of the cornea these will cause considerable irritation and inflammation. Monofilament suture material such as 10"0" nylon or polyester will not cause any irritation as long as the knots are buried in the tissue, because the suture material becomes covered by corneal epithelium and does not irritate. However, the sutures may become loose, and after about nine months nylon sutures will begin to soften and then break. The broken ends will then cause considerable irritation. There are three rules for the suturing of corneal incisions:-

1. Always use fine monofilament suture material(10"0" nylon or polyester.)
2. Always bury the knot.
3. Always remove the suture after 4 to 6 months. This last rule can be ignored for polyester sutures, because they do not weaken and break up even after many years.

If a particular suture is very tight and is causing excessive astigmatism, it can be removed sooner, after about 6 to 8 weeks. Loose sutures should be removed immediately. A loose nylon suture can be recognised very easily. It will stain green with fluorescein because it is not covered by the corneal epithelium. (The suturing of corneal incisions is also described in chapter 2.)

Corneal incisions are specifically recommended if the patient has had a previous glaucoma operation as this avoids damaging the drainage bleb. Corneal incisions are also advisable if the patient has a high risk of developing glaucoma later, because a limbal incision will cause scarring of the conjunctiva, which reduces the chance of success of a glaucoma operation later. For all other patients a limbal incision is better.

A corneal incision is made in the same way as a limbal incision. The incision can have the same shape as a limbal incision to provide a watertight wound, but care must be taken not to cut into the central part of the cornea, as this would affect the vision. Remember that a corneal incision will need to extend further round the eye than a limbal incision to have the same size opening into the eye.

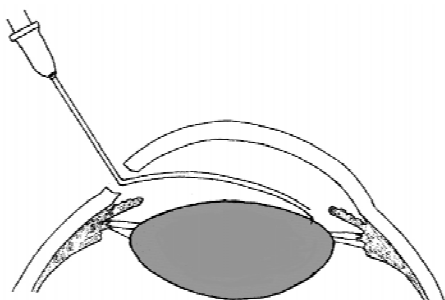


Fig. 5.22 The position of the irrigating cystitome in the eye

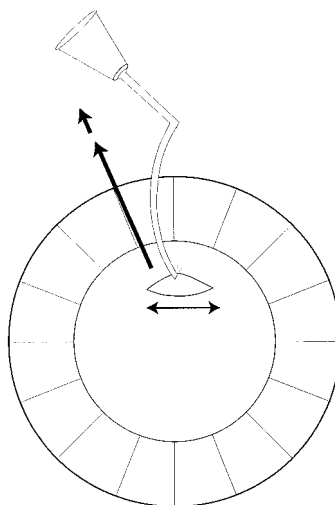


Fig. 5.23 To show how the capsule usually tears in the opposite direction to the movement of the cystitome

### ***Incising the anterior lens capsule – the capsulotomy***

Several different methods have been recommended for this. The aim is to remove the anterior capsule, but to keep intact the posterior capsule and the capsule at the equator of the lens where it is attached to the suspensory ligament. Nearly all methods use a small, specially shaped hypodermic needle called an irrigating cystitome. This can be made from a hypodermic needle simply by bending it into the right shape (fig. 5.22 and 5.23). It is very important at all times to protect the delicate endothelial cells on the back of the cornea and not to damage them either chemically or mechanically. The best way to ensure this protection is to use *visco-elastic* fluid, which is injected into the eye before doing the capsulotomy. (Various visco-elastic fluids are available. Some are very expensive, but hypromellose is quite cheap. It *must* be manufactured specially for intraocular use, and it *must* be completely pure and non-toxic.) If visco-elastic fluid is not available, then the cornea can be protected by injecting a bubble of air into the eye or alternatively by connecting the cystitome to the irrigating fluid. The constant flow of irrigating fluid will maintain the anterior chamber and protect the cornea throughout the procedure. It will also wash away any debris from the lens which may be released during the capsulotomy.

There are 3 commonly accepted ways of cutting and removing the anterior capsule. The first is called the “endocapsular” or “envelope” method, the second is called the “can opener” method, and the third is called the “continuous circular capsulo-rexis” method.

It is important to understand the way the lens capsule tears when it is punctured by the cystitome. The capsule is a thin elastic membrane. When the sharp point of

the cystitome needle is pushed into the lens, it punctures the capsule and makes a small tear in it. If the tip of the cystitome is then moved over the surface of the lens this tear then becomes bigger rather like tearing a thin piece of paper. If the cystitome is moved in one direction the capsule tends to tear in the opposite direction, at 90 degrees to the movement of the cystitome (see fig. 5.23).

### *The endocapsular method*

This is probably the safest and easiest way of performing the capsulotomy. A horizontal opening is made in the upper part of the lens capsule (fig. 5.24), but none of the capsule is removed at this stage. The nucleus and the cortex are removed through this opening. The intraocular lens is then inserted into the “envelope” between the anterior and posterior lens capsule, and finally the bulk of the anterior capsule is removed with intra-ocular scissors.

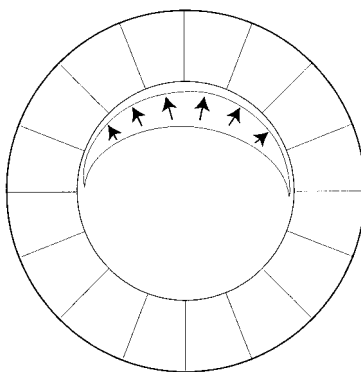
The advantages of the endocapsular method are:

- the intact anterior capsule helps to protect the corneal endothelium during the operation.
- it ensures that the intraocular lens is placed correctly inside the lens capsule.
- if the posterior capsule ruptures during the operation, the intact anterior capsule may still provide enough support for a posterior chamber IOL.

However the haptics will be in the ciliary sulcus and not in the capsular bag.

The main disadvantage of the endocapsular method is that it is sometimes difficult to remove the anterior capsule at the end of the operation without the use of visco-elastic fluids and fine intra-ocular scissors.

In the endocapsular method the cystitome punctures the lens capsule and short vertical movements are made across the upper part of the capsule. In this way a horizontal tear is made across the upper part of the capsule (fig. 5.24). Finally the tip of the cystitome is moved across the surface of the lens from left to right to make sure that the tear is complete.



*Fig. 5.24* Anterior capsulotomy by the endocapsular method. The arrows show the movements of the tip of the cystitome.

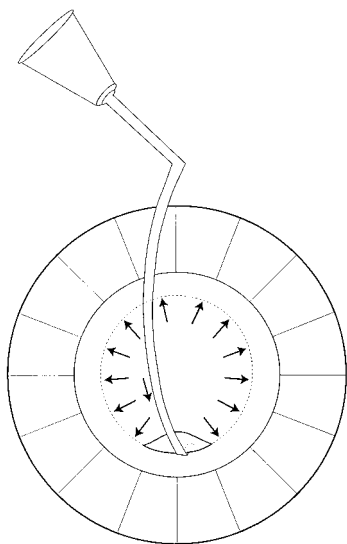


Fig. 5.25 The “can opener” capsulotomy. The arrows show the movements of the tip of the cystitome

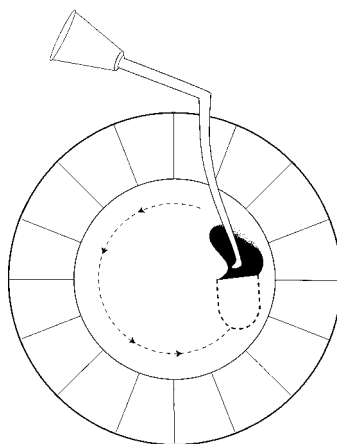


Fig. 5.26 Continuous circular capsulorexis capsulotomy. The folded over piece of capsule is shown as black.

#### *The “can opener” anterior capsulotomy.*

The aim of this is to tear the anterior capsule round its periphery and to leave a large hole in the centre. In the “can opener” technique the point of the cystitome is first pushed into the lens at the pupil margin at the 6 o’clock position at the bottom of the eye (fig. 5.25). The cystitome is then pushed about 1–2 mm downwards making a small tear in the capsule. The cystitome tip is then lifted out of the lens and pushed into it again at the 5 o’clock position and again moved 1–2 mm peripherally in order to enlarge the tear in the lens capsule. Altogether about 10 short radial cuts are made, first at the bottom of the lens, then at the sides and finally at the top, each cut pierces the lens towards the edge of the pupil and pushes outwards by 1–2 mm. In this way these radial cuts should produce a large round tear of the lens capsule (fig. 5.25). It is sometimes helpful to end by passing the cystitome right round in a circular direction to make sure that the cut is complete.

The advantage of the can-opener method is that no more manipulation in the eye is needed to remove the anterior capsule. This helps if visco-elastic fluids or fine intraocular scissors are not available. The disadvantages are:

- The capsule does not always tear in the way that is planned.
- The intraocular lens cannot always be placed reliably in the capsular bag.
- The lens nucleus may rub against and damage the corneal endothelium during expression of the nucleus.

#### *Continuous circular capsulo-rexis*

This is in theory the best way of incising and removing the anterior lens capsule, as it is torn without any jagged or irregular edges. There is therefore almost no risk of



any small tear in the capsule extending backwards round the equator of the lens capsule into the posterior capsule. It also ensures that the intraocular lens is placed very safely and securely inside the lens capsule. Continuous circular capsulo-rhexis is the only safe way of performing the anterior capsulotomy with a phakoemulsification operation. The method is to start with a small U shaped tear in the capsule, to fold this over with the tip of the needle, and then tear it right round in a circle in the same way as a thin piece of paper might be torn (fig. 5.26). There are however two problems with the technique. Firstly, it is very difficult to do in patients with dense opaque white cataracts, because the surgeon needs to see the edge of the capsule. Secondly, it is difficult to manoeuvre a large lens nucleus through the capsulo-rhexis opening and into the anterior chamber and so out of the eye. For these two reasons it is difficult to recommend capsulo-rhexis for surgery without phakoemulsification.

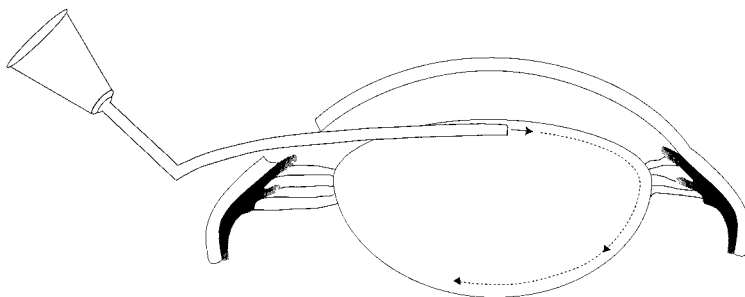
### ***Difficulties during Capsulotomy***

These may occur especially if the cataract is very dense or hypermature. The capsule may not tear in the planned direction, and as soon as the capsule is punctured, fluid white lens matter may leak out into the anterior chamber. This obscures the view and has to be washed away with irrigating fluid.

On rare occasions the capsule may be thick and calcified, and will not tear at all with the cystitome. In these patients the capsule may have to be cut using fine intra-ocular scissors, or the surgeon may have to do an intracapsular extraction instead.

### ***Hydro-dissection***

Hydro-dissection helps to separate the lens nucleus from the capsule and the lens cortex and so makes it easier to express the nucleus. A 2 or 5 ml syringe is filled with the irrigating fluid and mounted on a fine blunt cannula. This cannula is then inserted just under the capsule and irrigating fluid injected fairly vigorously just under the capsule (fig. 5.27). This helps to separate the lens nucleus and cortex from the capsule. A good hydro-dissection makes the expression of the nucleus easier. It also helps to separate the lens cortex from the capsule, so that the cortex can be stripped away from the capsule more easily.



*Fig. 5.27* Hydro-dissection. The fluid separates the lens nucleus from the cortex and can also separate the cortex from the capsule

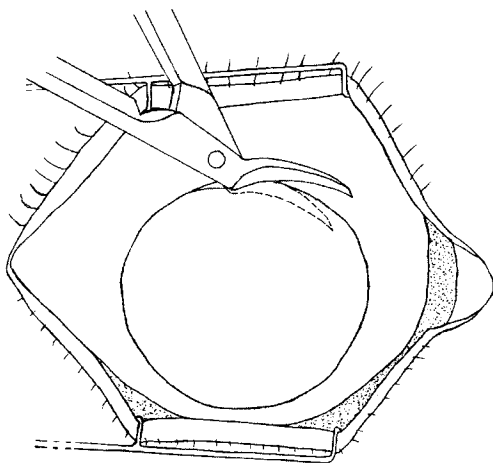


Fig. 5.28 Using corneal scissors to complete the incision

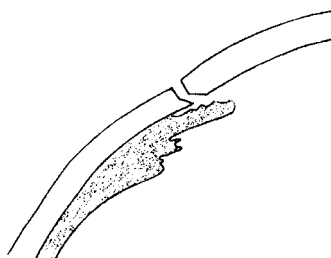


Fig. 5.29 The profile of the wound using a knife to start the incision and scissors to finish it

### ***Completing the incision.***

The incision into the eye must now be enlarged and completed. *The knife* or *keratome* can be used for this, but if the eye is soft it is very difficult to use the knife to cut into a soft eye. Visco-elastic fluid can be injected into the anterior chamber to keep the eye firm, so the incision can be completed with a knife or keratome making a shelf as already described. If the eye is soft or it is difficult to complete the incision with a knife, *corneal scissors* should be used. The opening made by the knife must be big enough to get one blade of the corneal scissors into the anterior chamber. Make sure that this blade does not catch or go through the iris. Use the scissors to complete the incision taking several small snips (fig. 5.28). If the scissors are sharp and held at the correct angle the incision can usually be completed easily. If there is any pressure on the eye the iris will bulge out through the incision. The iris will then catch on the tip of the scissors, and it is then very easy to make the mistake of cutting through the iris as well as cornea with the scissors. Fig. 5.29 shows the profile of the completed incision using a knife to start with, and scissors to complete the incision.

### ***Expressing the nucleus of the lens***

The nucleus of the lens can now be expressed out of the eye, through the hole in the anterior capsule and out through the wound. The usual way to do this is with a lens expressor and a lens loop. These are shown in fig. 5.67 on page 144. In young patients the nucleus is fairly soft and fairly small having the consistency of paste, but with increasing age the nucleus becomes larger and harder and fills most of the lens. Sometimes in intumescent cataracts the nucleus begins to shrink again, although it remains hard.

During the expression of the lens nucleus it is very important to prevent it from rubbing against the corneal endothelium. If it does, the vital endothelial cells will

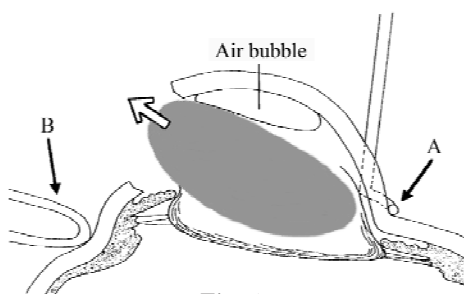


Fig. 5.30

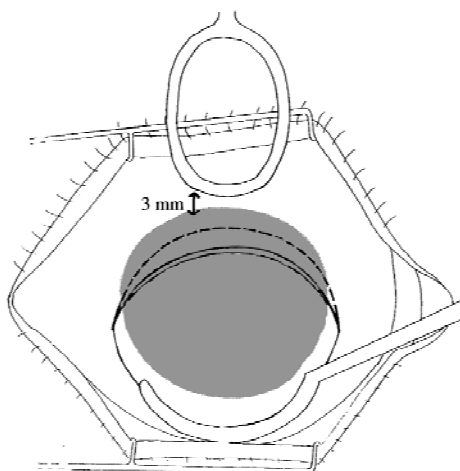


Fig. 5.31

*Figs. 5.30 and 5.31* To show the position and action of the lens expressor and lens loop when expressing the nucleus

be damaged and will never be replaced. The more the nucleus rubs against the corneal endothelial cells, the more likely these cells are to be damaged or destroyed. The best way to protect the corneal endothelium is to use visco-elastic fluid. This may have been washed out during the hydro-dissection and more may need to be inserted into the anterior chamber. If visco-elastic fluid is not available, air costs nothing and is perfectly satisfactory. During the expression of the nucleus try to keep a small air bubble in the anterior chamber to act as a cushion between the corneal endothelium and the lens.

The endocapsular method also helps to protect the corneal endothelium, because the intact anterior capsule prevents the nucleus from rubbing against the cornea. The capsule has a smooth surface and will not damage the endothelium so easily.

The technique of expressing the nucleus is as follows:

1. Fill the anterior chamber with visco-elastic fluid or a small air bubble (fig. 5.30).
2. Place a lens expressor at the lower limbus (fig. 5.30 and 31).
3. Put counter-pressure usually with a lens loop well above the upper limbus about 3 mm on the scleral side of the incision (fig. 5.30 and 31).
4. Press gently but firmly with the lens expressor and the lower pole of the nucleus will tilt back so that the upper pole of the nucleus tilts forwards. Gentle pressure with the lens loop on the posterior lip of the wound will now open up the incision and push the upper pole of the nucleus forward into the incision. The black arrows in fig. 5.30 show where the expressor and the lens loop press into the eye. If the lens loop is too near the edge of the incision, then pressure with it will press the upper pole of the nucleus backwards and so stop it coming out of the eye. It is very important to have both the lens loop and the expressor in the right place to slide the nucleus out of the eye. The pressure with

expressor at A should be a little more than that with the loop at B. The upper pole of the nucleus should now appear between the lips of the incision. By moving the lens expressor upwards a little over the lower part of the cornea and continuing with gentle pressure from the lens loop, the nucleus will be pushed further out of the eye. Do not let the expressor come right up over the central cornea as it will press the cornea against the lens and damage the endothelium.

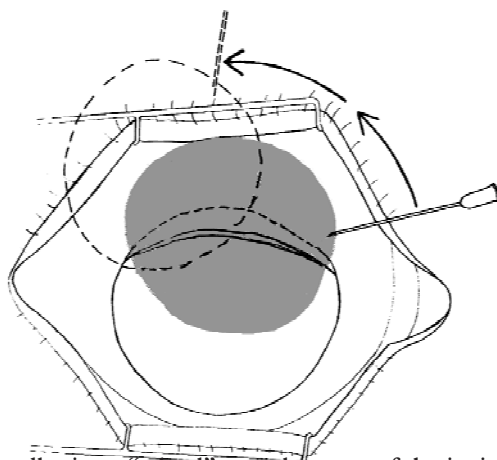
### ***Difficulties during the expression of the nucleus***

If the nucleus is reluctant to emerge from the eye it may be held up in 3 possible places:

1. The incision may be too small so the nucleus is trapped inside the anterior chamber. *This is the usual reason why the nucleus will not come out.*
  - Make the incision larger. It is important to remember with the shelved incision that its internal size is smaller than its external size, because of the shelf. Therefore a very shelved incision may need to be enlarged.
2. The iris sphincter may be too small so the nucleus is trapped behind the pupil.
  - Do a sphincterotomy of the iris to enlarge it. To do this a vertical cut is made in the upper part of the iris starting at the pupil margin. The iris can be resutured after the IOL has been inserted using 10“0” polyester suture, but that is not essential. (Sometimes a sphincterotomy can be avoided. It may be enough to grasp the iris with forceps and just place the upper part behind the upper pole of the lens as it is trying to come out of the eye.)
3. The capsulotomy may be too small so the nucleus is still trapped inside the lens capsule
  - Enlarge the capsulotomy with radial incisions at 10 and 2 o'clock.

Sometimes the lens nucleus may be particularly large and hard. This is found especially in “black” nuclear cataracts.

Once the nucleus is half out of the eye it can be wheeled out using a lens loop, or the tip of a needle (fig. 5.32). It can be squeezed right out of the eye using the expressor but this tends to rub the endothelial cells of the cornea against the lens.



*Fig. 5.32 Using a needle tip to “wheel” a nucleus out of the incision*

There are other ways of removing the nucleus from the eye. Some surgeons place an irrigating lens loop (sometimes called an irrigating Vectis) inside the eye, behind the nucleus but in front of the posterior capsule (see page 125). This is connected to a syringe or the infusion bottle and hydrostatic pressure will then force the nucleus out of the eye. Great care must be taken to avoid scooping the nucleus upwards against the corneal endothelium, and thus damaging it.

### ***Removing the lens cortex by irrigation and aspiration***

This may be easy or difficult depending mainly on the consistency and transparency of the lens cortex. If the cataract is almost intumescent, the cortex is white and opaque and semi-fluid. It breaks up easily and therefore it is both easy to see and to remove. If the lens cortex is fairly transparent, as it is in most nuclear cataracts or in less mature cataracts, it can be difficult both to see and remove. It is difficult to see because it is transparent, and difficult to remove because it will not break up and sticks to the capsule. For these cases an operating microscope with co-axial illumination makes all the difference. The almost transparent cortical lens matter and the edge of the lens capsule can only be seen against the red fundus reflex with co-axial illumination (see plate 1 and plate 2).

The best way of removing the cortical lens matter is with a two-way cannula which will both irrigate and aspirate (fig. 5.33). The irrigation is attached to an infusion line so that there is a constant gentle flow of fluid which keeps the anterior chamber formed. The aspiration is attached to a 5 ml syringe. Make sure that the cannula is connected the right way round as shown in fig. 5.34. If a two-way cannula is not available it is possible to irrigate any white, opaque and degenerate



*Fig. 5.33* A two-way irrigating/aspirating cannula

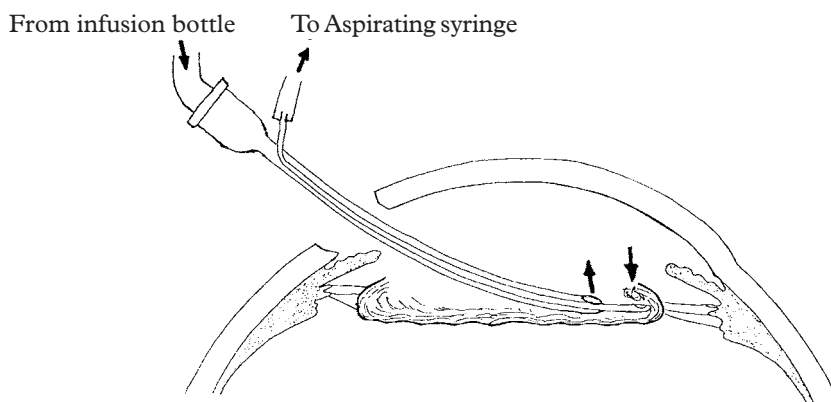


Fig. 5.34 To show the lens cortex being aspirated whilst maintaining the anterior chamber with irrigation

cortical lens matter out of the eye with a simple cannula. However this will not be effective for a nuclear cataract, where the lens cortex is transparent and much harder to break up.

### *The Epinucleus.*

Some cataracts have a layer of lens cells around the nucleus called the epinucleus. This is softer than the nucleus but harder than the cortex. The epinucleus may come out with the nucleus or it may be left behind in the eye. It can be removed by irrigation and aspiration but this can be very time consuming. It is more easily removed by injecting irrigating fluid through a blunt cannula into the anterior chamber which will wash it out of the eye in one piece.

### *The Technique of Irrigation and Aspiration.*

Removing the cortical lens matter without damaging the posterior capsule is probably the hardest part of an extracapsular cataract extraction. It is made easier by a good hydrodissection, which helps to separate the cortex from the capsule. Here is a list of helpful tips to assist this delicate part of the operation.

- Before starting the aspiration, it is often a good plan to just wash out the anterior chamber with irrigating fluid in a 10 ml syringe and a cannula. This will wash away any large fragments of lens cortex and any epinucleus, and the last pieces can be removed with irrigation and aspiration.
- Maintain a constant gentle, continuous flow of irrigating fluid. Keep watching the tip of the cannula. The aspirating port hole at the tip of the cannula should be facing forwards (fig. 5.34). It may be necessary to turn it so the hole is facing side-ways to remove lens cortex which is caught under the iris or stuck to the posterior lens capsule. It should never face backwards or it will suck in the posterior capsule and rupture it. If the two-way cannula has been sterilised by chemical methods or by boiling, make sure that all the chemical and the water has been very thoroughly washed out of it so that only pure irrigating fluid enters the eye.

- Keep the tip of the cannula in the plane of the pupil or just behind it. Do not press on to the posterior capsule or it may rupture. Place the cannula so that the tip is close to the lens cortex to be removed.
- Now apply gentle suction on the syringe, and the lens cortex should be sucked into the tip of the cannula and strip away from the lens capsule. As a general rule do not move the tip of the cannula in the eye while applying suction with the syringe. However, if the lens cortex is firmly attached to the lens capsule, it may help to move the cannula tip very slowly whilst aspirating to help strip the lens cortex from the capsule. When doing this always move the cannula tip from the edge of the pupil towards the centre—not the other way. Try to peel away all the lens cortex starting at the bottom of the eye at 6 o'clock, then at the sides and finally from the top.
- As well as watching the position of the tip of the cannula, also watch where the cannula enters the eye through the lips of the wound. If the shaft of the cannula is not resting gently between the wound edges but is either pressing upwards or downwards it will keep the wound open so the anterior chamber will not remain full of fluid. This makes the aspiration more difficult and the cannula is more likely to damage the corneal endothelium or rupture the posterior lens capsule.

### ***Difficulties during irrigation and aspiration of the lens cortex.***

**1. Failure to remove all the lens cortex.** It is important to remove as much lens cortex as possible. However if there are a few pieces still attached to the capsule which are reluctant to emerge, it is best to leave them as long as the centre of the pupil is clear of lens cortex and continue with the operation. Once the IOL is in place and the wound closed with sutures, a further irrigation/aspiration should be performed by passing the two way cannula between two sutures. The anterior chamber will then deepen when the irrigating cannula is placed in the eye because the wound is almost closed. The IOL will act as a splint holding the posterior capsule in place, and the haptics will help dislodge some of the peripheral pieces of lens cortex, and these last few pieces will then be aspirated out of the eye more easily.

Lens cortex at the 12 o'clock position under the upper iris may be particularly difficult to remove because the tip of the cannula cannot easily reach there. Some surgeons make a small separate incision in the side of the cornea at the beginning of the operation. The cannula can be inserted through this to remove the cortex at 12 o'clock and the incision is small enough to be self sealing.

**2. A poorly dilated pupil.** If the pupil is not well dilated, it is difficult to aspirate cortical lens matter which is hidden behind the iris. A poorly dilated pupil is best avoided by taking all the steps described on pages 58–59 to make sure that the pupil is well dilated. If the pupil is not well dilated the tip of the cannula must be passed behind the iris and suction applied without being able to see the tip. If it is obvious that the iris has become caught in the aspirating port hole, then release the suction and move the point of the cannula very slightly. Once it seems that the tip



of the cannula has engaged cortical lens matter then maintain gentle suction with the syringe and very gently withdraw the cannula to the centre of the pupil. Usually the lens cortex will strip away from the lens capsule. One helpful tip with a constricted pupil is to pass the tip of the cannula behind the iris, and then use the syringe to squirt a small amount of irrigating fluid under the iris which may dislodge pieces of lens cortex that cannot be seen.

**3. The tight eye or the eye under pressure.** If the eye is tight or under pressure it becomes very difficult to maintain the depth of the anterior chamber, and the posterior capsule appears to be pushing forwards the whole time. In this situation it is very likely that the tip of the irrigating cannula will rupture the posterior lens capsule, and vitreous loss will then occur. The other signs of a tight eye are that the wound may gape a little or there may be a small horizontal fold across the centre of the cornea (fig. 5.35). A tight eye and forward pressure on the open eye may have four basic causes (see fig. 5.36):

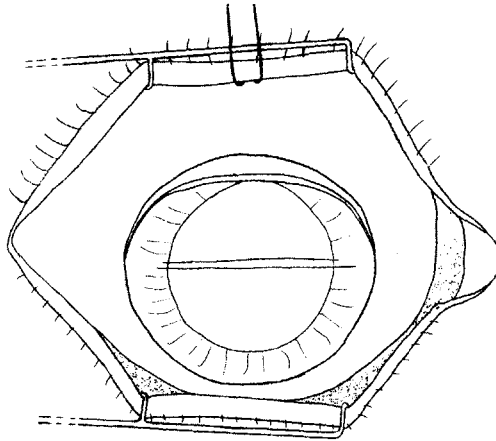


Fig. 5.35 A horizontal fold across the cornea with slight gapping of the wound

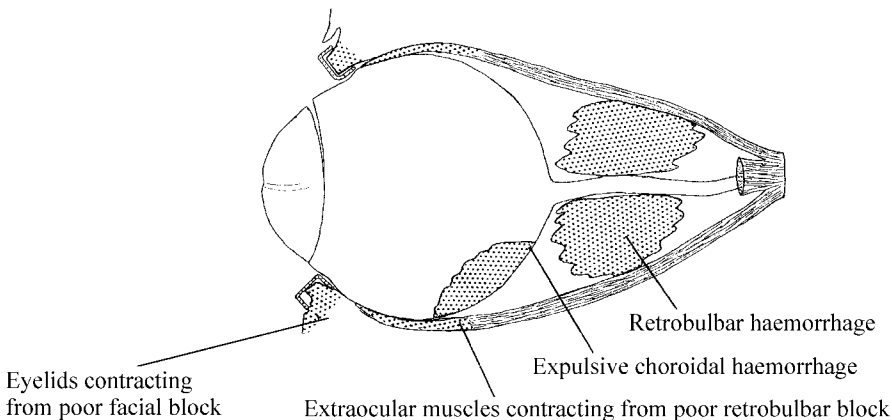


Fig. 5.36 The causes of a tense or tight eye



1. *An incomplete facial block.* This is the most common cause and the eye-lids will tend to squeeze shut. The speculum may also be pressing slightly on the eye. Ask the assistant to lift the speculum gently, and bring the two limbs of the speculum together a little, and usually the signs of pressure on the eye will disappear and the anterior chamber will become more deep. The operation can proceed, but the assistant will need to hold the speculum up until the wound has been closed with sutures.

2. *An incomplete retrobulbar block.* This will cause pressure on the open eye because the extraocular muscles are still contracting. This should have been identified before reaching this stage. If this is causing a serious problem and the operation has already started, a sub Tenon's block using a blunt curved cannula can be safely given, as this has very little risk of rupturing or damaging a blood vessel behind the eye (see page 69).

3. *A retrobulbar haemorrhage.* This is a complication of the retrobulbar block and causes pressure on the open eye. A severe retrobulbar haemorrhage should have been identified before the operation begins, but a small or delayed retrobulbar haemorrhage may not be noted until this stage.

4. *An expulsive haemorrhage.* This is an extremely rare but disastrous complication causing forward pressure of the lens and the posterior capsule. This is caused by a ruptured choroidal artery causing bleeding into the choroid and forcing all the intraocular contents out of the eye. With a severe haemorrhage first the lens, then the vitreous and finally the choroid and retina will be progressively extruded from the eye. This very rarely happens. With less severe choroidal haemorrhage the eye will just appear very tight for no obvious reason.

*Treatment.* The best treatment for a choroidal haemorrhage is to sew up the eye as quickly and securely as possible. This restores the intraocular pressure and acts as a tamponade stopping the haemorrhage and in this way the eye may be saved. After a few weeks, the haemorrhage will absorb and any further surgery can be safely performed.

### *The management of a tight eye and a shallow anterior chamber*

If the anterior chamber is still rather shallow despite lifting up the speculum, the surgeon will rightly be worried about rupturing the posterior lens capsule with the irrigating cannula when trying to remove the last pieces of lens cortex. The best thing to do is to try to insert the IOL with the help of visco-elastic fluid and sew up the wound (see page 120). With a closed wound the anterior chamber will deepen with irrigation/aspiration, and the last pieces of lens cortex can be removed much more easily. With a very tight eye it may not be possible to insert an IOL at all.

### ***Posterior capsule rupture and vitreous loss***

The most common complication of extracapsular extraction is that the posterior capsule ruptures and vitreous starts to emerge from the wound. It can happen for various reasons. The eye may be tight, or there may be external pressure on the eye so the anterior chamber is very shallow. Sometimes there may not be sufficient care taken during irrigation and aspiration of the lens cortex, and the two-way cannula may catch and rupture the posterior lens capsule. Most cases of posterior capsular

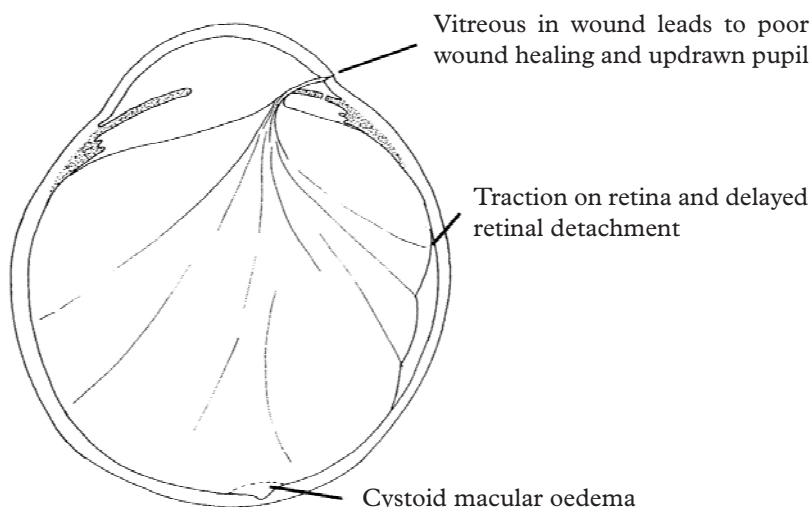


Fig. 5.37 To show the complications of vitreous loss

rupture cause a loss of vitreous through the wound as well, but in some cases no vitreous loss occurs. Even the best surgeons experience vitreous loss, but with care and foresight it should not happen frequently.

A vitreous loss rate of 5% or less is acceptable. Any complication rate will depend both on the ability of the surgeon and whether the cases are straightforward or not.

Vitreous loss can cause serious complications, but they are not common if managed correctly. The vitreous is a gelatinous substance containing protein fibrils and tends to stick to anything solid that it touches. Therefore if the vitreous prolapses through the wound it will stick to the wound edges. This may prevent the wound healing well, and it may cause the iris and pupil to be drawn up into the wound post operatively. The posterior surface of the vitreous is attached to the retina, especially to the peripheral retina. If the anterior part of the vitreous becomes trapped in the wound, there is traction on the posterior part of the vitreous. This will pull on the peripheral retina and may cause a retinal detachment. Severe cystoid macular oedema is also much more common after vitreous loss. The four main complications of vitreous loss are therefore:- (fig. 5.37)

- *a retinal detachment*
- *cystoid macular oedema*
- *poor wound healing*
- *an updrawn pupil*

### *Management of Vitreous Loss*

The correct management of vitreous loss is to cut and clear all the vitreous from the wound and the anterior chamber. Ideally no vitreous should be left touching the wound or the anterior chamber, and removing the vitreous in this way is called an *anterior vitrectomy*. The best way of performing this is with a vitrectomy machine, which slowly aspirates the vitreous while chopping and dividing it. If a

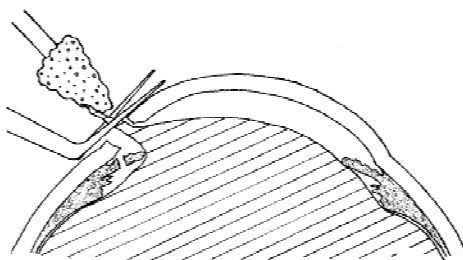


Fig. 5.38 The technique of sponge vitrectomy

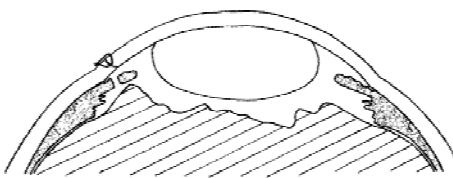


Fig. 5.39 The end result of sponge vitrectomy with an air bubble in the anterior chamber

vitrectomy machine is not available the recommended method is to use a small cellulose sponge and a pair of iris scissors, “the sponge and scissors vitrectomy” (fig. 5.38). A small dry cellulose sponge is inserted into the wound edge where it will adhere to the vitreous, and as the sponge is gently lifted from the wound scissors are used to cut the attached vitreous. The surgeon will need to put the sponge repeatedly into the lips of the wound, lift it up and cut the vitreous to which it is attached. If the assistant lifts the speculum at the same time this may help to reduce any pressure on the eye, and help the vitreous to fall back from the wound. A “sponge and scissors” vitrectomy should continue until there is no formed vitreous left in the anterior chamber or in front of the pupil (fig. 5.39). If vitreous is still present in the anterior chamber, each time the sponge is inserted into the wound edge and gently withdrawn it will be seen to have gelatinous strands of vitreous attached to it. A “pupil tug” will also be noticed so that as the sponge is withdrawn slightly the vitreous pulls on the pupil margin and slightly distorts it. When there is no “pupil tug” and no strands of vitreous attached to the cellulose sponge, then the anterior chamber is clear of vitreous and this can be confirmed by inserting a small air bubble into the anterior chamber. If vitreous is still present the air bubble will be distorted.

Do not suck the vitreous out of the eye with a syringe as this risks pulling on the posterior vitreous and causing a retinal detachment. There is always a temptation when vitreous loss occurs not to clear away all the vitreous from the wound and anterior chamber. *However it is much better to remove too much vitreous rather than leave it trapped in the wound.* Sometimes the vitreous is fluid and degenerate and it may keep coming forward into the anterior chamber as fast as it is excised. This type of fluid vitreous is less likely to stick to the wound edges or the iris and so cause significant traction on the retina. Therefore the complications of leaving degenerate fluid vitreous in the anterior chamber are much less. Remember that a rapid, continuous and unexplained loss of vitreous could be caused by an expulsive haemorrhage, but fortunately this is very rare.

When vitreous loss has occurred the surgeon must decide whether to implant a posterior chamber lens, an anterior chamber lens or no IOL at all. If there is only a very small rupture in the posterior capsule, it is reasonable to implant a posterior chamber lens but to position the haptic loops where the posterior capsule is intact.

If the cataract extraction has been done by the endocapsular method so that the anterior capsule is still present, it may be best to insert the lens in front of both the anterior and the posterior capsule rather than into the capsular bag.

If the posterior capsule has ruptured extensively and it does not seem possible to insert a posterior chamber lens, then an anterior chamber lens may be inserted (see page 153). In that case the capsule remnants are not serving any useful function and it may sometimes be better to remove them. If the surgeon decides to convert from a posterior chamber lens to an anterior chamber lens implant, then it is best to perform a peripheral iridectomy as well to prevent any risk of blocking the flow of aqueous (see page 139).

### ***Inserting a posterior chamber intraocular lens***

It is very much easier to insert the intraocular lens if the anterior chamber is deep. Visco-elastic fluid should be used to fill up the anterior chamber. If this is not available irrigating fluid or an air bubble must be used, and it may be helpful to put 2 interrupted sutures at each edge of the wound just leaving a 7 mm gap through which the intraocular lens can be inserted. This will help to maintain the air bubble or irrigating fluid in the anterior chamber and prevent it collapsing. Make sure that the orientation of the intraocular lens is correct (see fig. 5.41). The tip of the lower haptic should be pointing towards the left. Also make sure that as the intraocular lens goes into the eye it does not brush against the eyelids or eyelashes and so risk becoming contaminated with skin bacteria. If the “can-opener” anterior capsulotomy technique was used, then insert the lower haptic so that it goes behind the pupil. If the endocapsular anterior capsulotomy technique was used, insert the lower haptic so that it goes behind the anterior capsule and into the capsular bag. (This may be a little bit difficult if an air bubble is being used to maintain the anterior chamber depth, as the air bubble will tend to press the anterior capsule back onto the posterior capsule.) Once the first haptic is in place and the optic of the lens is in the anterior chamber, the second haptic must be inserted into the eye. This is done by rotating or “dialling” the lens through 90 degrees so that the haptics lie transversely in the eye at 3 and 9 o’clock. There are three methods for doing this:

1. *Using the lens dialler with a pointed tip and the dialling holes at the edge of the optic of the IOL* (see fig. 5.40 and 5.41). The tip of the dialler engages the upper dialling hole and moves down and to the left. This pushes the intraocular lens into the centre of the eye and also rotates it at the same time. As it rotates the upper haptic should naturally pass into the capsular bag in the case of the “endocapsular technique”, or behind the iris into the ciliary sulcus in the case of the “can opener” technique.
2. *Using the dialler with a groove at the tip at the junction of the optic and upper haptic* (fig. 5.42 and 5.43). Some lenses do not have dialling holes. With this type of lens the dialler can be placed where the upper haptic is attached to the optic and in the same way the lens can be “dialled” or rotated into the eye.

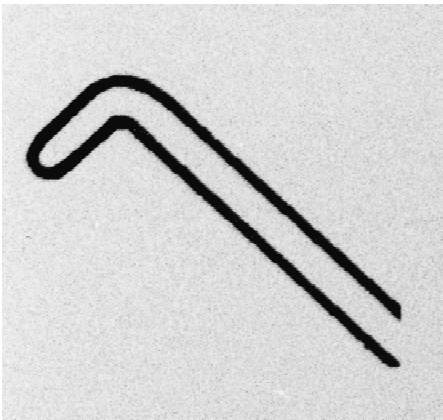


Fig. 5.40 Enlarged view of the tip of the Dialler for use with lenses with dialling holes

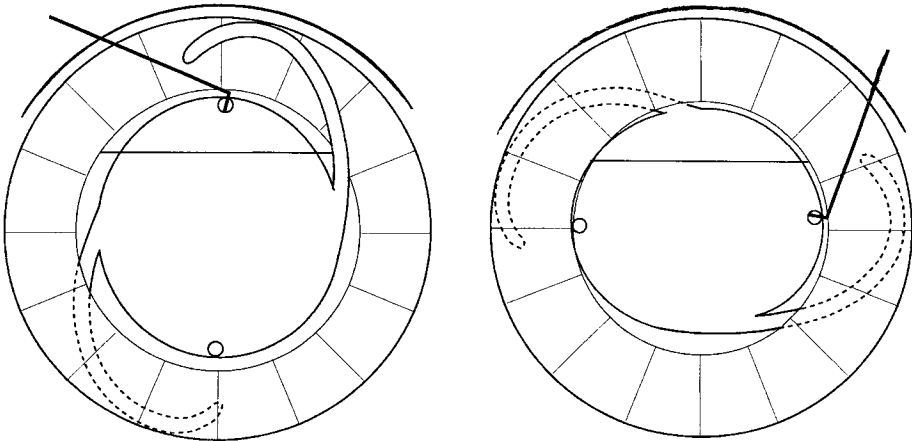


Fig. 5.41 To show the action of the Dialler for IOLs with dialling holes

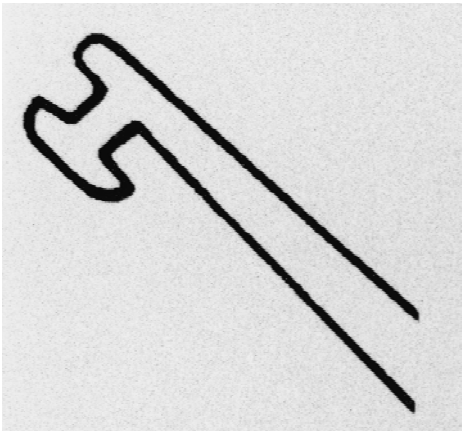
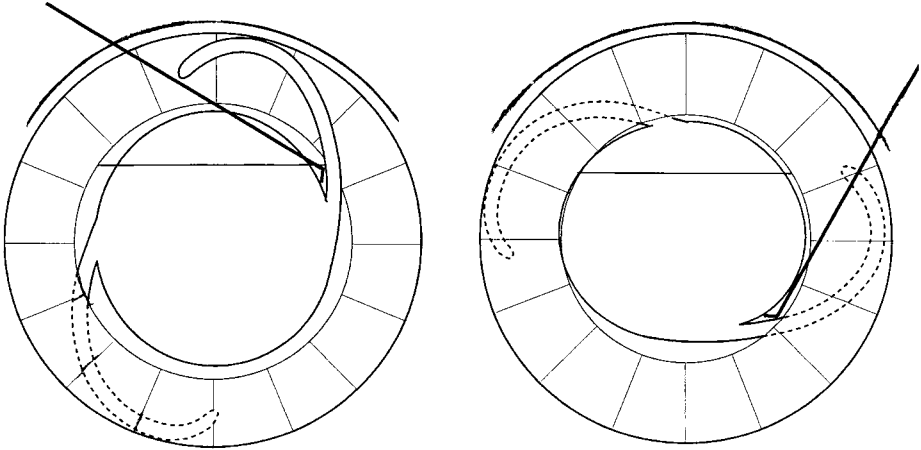


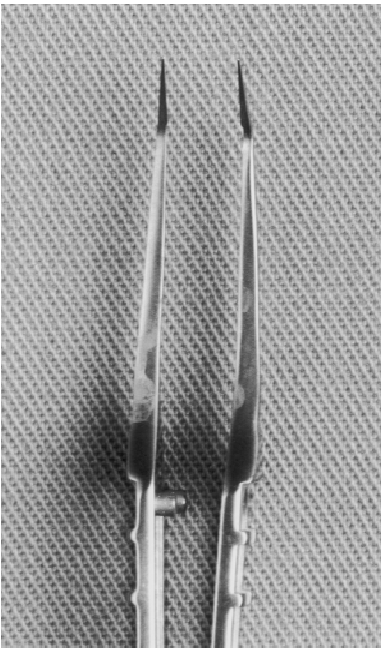
Fig. 5.42 Enlarged view of the tip of the Dialler used for lenses without dialling holes



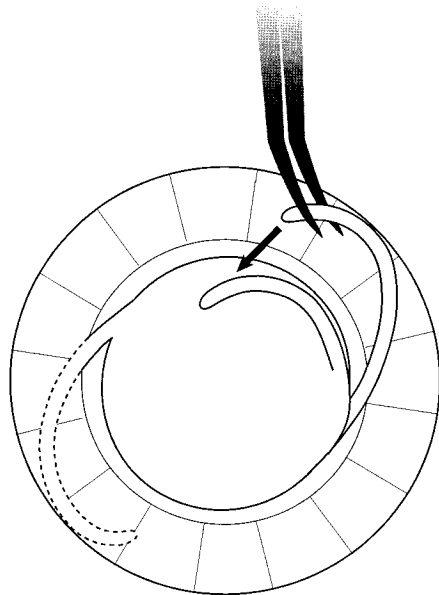
*Fig. 5.43 To show the action of the Dialler for IOLs without dialling holes*

3. Using the fine intra-ocular Kelman-McPherson capsule forceps (fig. 5.44) gently grasp the upper haptic and flex it towards the centre of the eye downwards and to the right (fig. 5.45). The grip on the upper haptic is then released so that it springs back into place behind the iris or in the capsular bag.

Once the IOL is in place, the anterior capsule is removed if the endocapsular technique was used. With the anterior chamber full of viscoelastic fluid, the

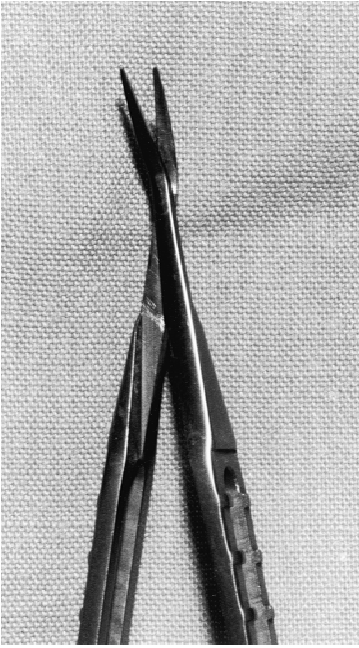


*Fig. 5-44 Kelman-McPherson capsular forceps*

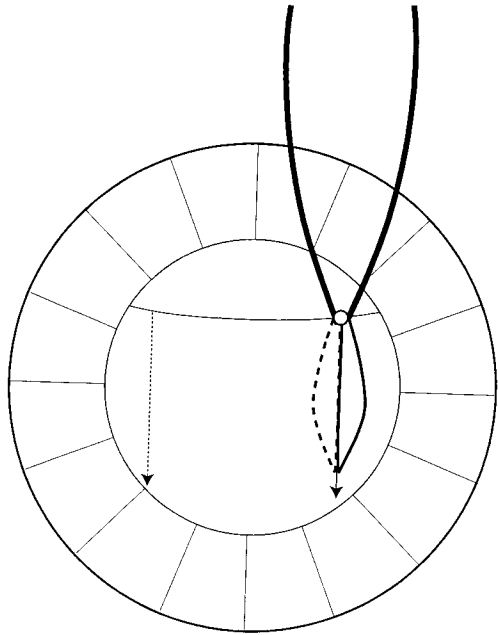


*Fig. 5.45 Inserting an IOL using Kelman-McPherson capsular forceps*

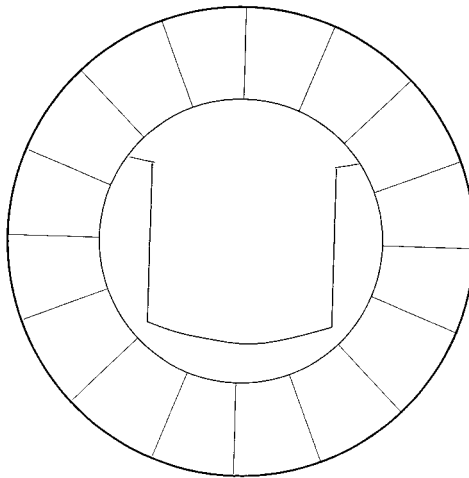
capsular scissors (fig. 5.46) are used to make two vertical cuts at either side of the anterior capsule (fig. 5.47) The central flap is then grasped with the Kelman-McPherson capsular forceps shown in fig. 5.44 and torn off at its base (fig. 5.48) Alternatively the central flap can be left in the eye until the wound is sutured and closed, and then grasped and torn off with the two way cannula during the final irrigation/ aspiration.



*Fig. 5.46* Capsular scissors



*Fig. 5.47* Making two vertical cuts in the anterior capsule with capsulotomy scissors



*Fig. 5.48* The central piece of anterior capsule has been removed with Kelman-McPherson capsular forceps



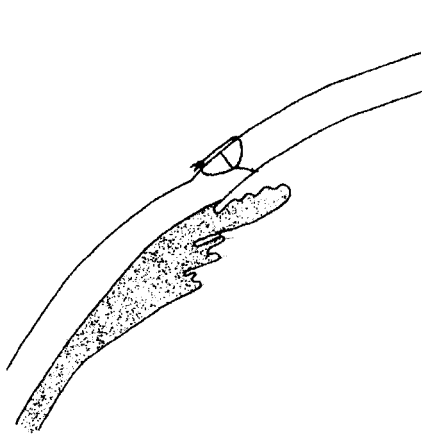
### ***Difficulties in inserting the IOL***

Sometimes if the eye is rather tight or the anterior chamber is shallow, it may be difficult to get the IOL into the eye. In some cases the second haptic will not go behind the iris, but in really difficult cases it may be difficult to get the second haptic even to stay in the anterior chamber, and it keeps coming out of the eye. In this situation it is best just to leave the IOL where it is, either in the anterior chamber or with the second haptic of the IOL outside the eye, and sew up the wound completely and tightly. The anterior chamber is then filled with fluid, preferably visco-elastic but failing that with irrigating fluid. This will deepen the anterior chamber and create downward pressure on the posterior capsule and the IOL. This makes it very much easier to dial the IOL into place by inserting the dialler between two sutures.

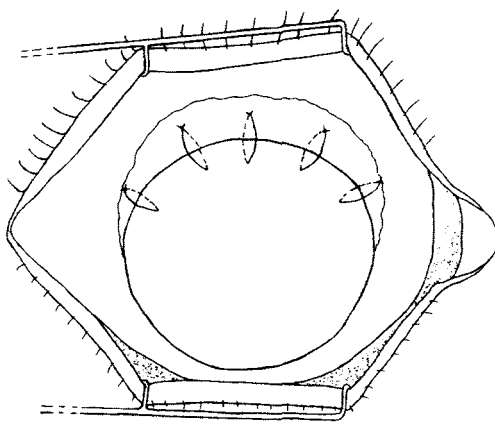
### ***Wound closure***

The methods of wound closure have already been described on pages 30–36. The basic rules are:

- Place the suture at the right depth (fig. 5.49); too shallow causes poor wound healing and too deep causes a “wick” from the anterior chamber to the outside, and a possible route of infection into the eye.
- Have the suture at the right tension; too tight causes astigmatism, and too loose causes poor wound healing and astigmatism in the opposite direction.
- With virgin silk or absorbable suture material, 4 to 5 interrupted sutures should be used. The knots should be placed at the scleral end of the wound where they will be covered by conjunctiva (fig. 5.50).
- With monofilament nylon (9“0” or 10“0”) or polyester(10“0” or 11“0”) it is much better to bury the knots (see pages 31–2). For sutures on the cornea the knots **must** be buried.

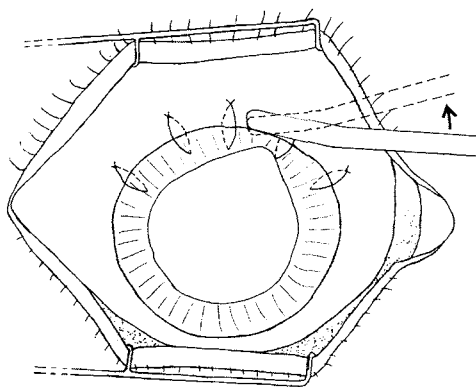


*Fig. 5.49* The closed wound

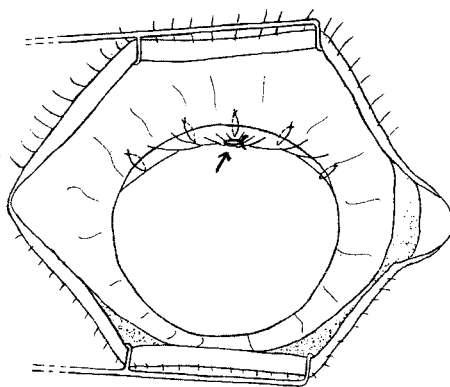


*Fig. 5.50* The position of the knots when closing the wound





*Fig. 5.51* The use of the iris retractor to replace the iris and free it from the lips of the wound



*Fig. 5.52* A small suture (arrowed) to bring down the conjunctiva to cover the incision

- A continuous “bootlace” nylon or polyester suture with a single buried knot at one end gives a very quick, secure and neat wound closure (see page 32).
- Make sure the knots are properly tied (see pages 35–36)
- Make sure that the iris is neither adherent to the wound nor trapped in it. This is done by gently inserting an iris retractor between the lips of the wound in between the sutures. If the iris has actually prolapsed from the wound it is better to use the side of the iris retractor to stroke it back into the eye (see fig. 5.51) rather than the tip to poke it back in.

When the wound has been closed or almost closed there should be a final irrigation of the anterior chamber, using the two-way cannula. The cannula can be inserted into the eye between two of the sutures. If a continuous suture is used for wound closure, then the first half hitch of the knot can be tied, the cannula placed between the sutures, and when the cannula is finally removed the suture can be tightened and the second half of the knot completed.

This final irrigation and aspiration of the anterior chamber will wash out all the viscoelastic fluid and also any last pieces of lens cortex which may have been dislodged by the IOL. ***It is a very important step and will help to prevent post-operative uveitis.*** The IOL acts as a splint keeping the posterior capsule in place, and the sutured wound means that the anterior chamber stays very deep. Therefore this final irrigation and aspiration can be more easy and effective.

It is not essential to suture the conjunctiva if a fornix based conjunctival flap has been used, but some surgeons like to place a “purse-string” suture to tighten the conjunctiva and bring it down to cover the wound giving extra protection. (see fig. 5.52). This suture can either be placed at the 12 o’clock position or at one or other end of the conjunctival incision. If a nylon suture is used for this, again make sure that the knot gets buried under the conjunctiva and is not on the surface.

## Small incision, sutureless cataract surgery

The idea of small incision sutureless cataract surgery has developed from phakoemulsification, and has been pioneered in developing countries. Cataracts can be removed without phakoemulsification through an incision which is self sealing and therefore sutureless. The incision is not all that small although it is smaller than for a conventional cataract extraction. However the name has stuck and the technique is sometimes called SICS (Small Incision Cataract Surgery). Because no suturing is needed, this saves both time and money, and because the incision is watertight the eye is more stable during the operation. The main disadvantage is that the operation is harder to perform than a standard operation particularly if the nucleus is fairly large. Small incision cataract surgery requires 3 separate steps, each one must be completed successfully to enable the next one to be performed.

- The incision needs to be self-sealing and yet large enough to allow the entire lens nucleus to be removed in one piece. This can be achieved with a tunnel shaped incision.
- The nucleus is then mobilised inside the eye, and inside the lens, to enable it to be removed.
- The nucleus is then removed without damaging either the cornea or the posterior lens capsule.

### 1. The incision

There are three parts to this. The opening into the sclera, the tunnel and the opening into the cornea.

#### *a) The opening into the sclera* (see fig. 5.53a)

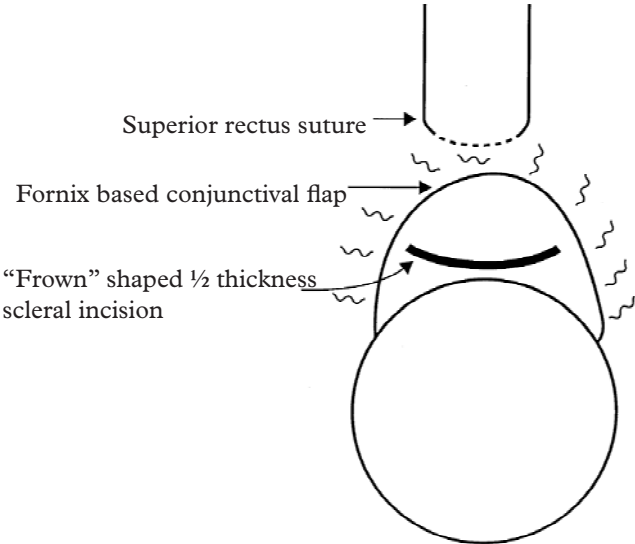
A superior rectus suture is inserted and a fornix based conjunctival flap dissected. The incision into the sclera is about 8 mm long and usually shaped like a “frown”. It can be slightly smaller (6–7 mm), especially if the nucleus is small or the surgeon is very skilled. It can be even larger. The incision goes halfway through the sclera and can be made with any sharp knife or razor blade fragment. Because it is a little way from the limbus, it is quite vascularised and the blood vessels will need gentle cautery or diathermy first. At its closest point, it should be 2 mm from the clear cornea. The incision can be made straight across rather than frown-shaped but the frown incision is said to produce less astigmatism.

The incision doesn’t need suturing because the large distance of at least 4mm between the internal and external opening (see fig. 5.53d) makes the wound self-sealing as the intraocular pressure rises. Therefore the width of the incision from side to side does not really matter. The post operative astigmatism is usually about 1 dioptre. It will be greater if the incision is nearer to the limbus or if it is larger. However larger incisions make the operation easier, and the astigmatism can always be reduced by a single suture in the middle of the wound.

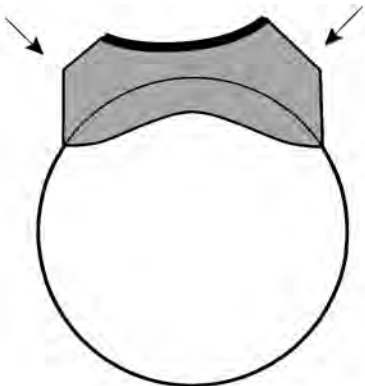
#### *b) Making the tunnel* (fig. 5.53b)

This is the most critical part of the incision, and for it a standard crescent knife is used. Since the coming of Phako emulsification, these knives are readily available and usually “disposable”. However, with care between cases and sterilising the

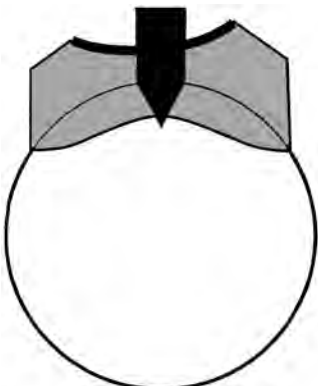
Fig. 5.53



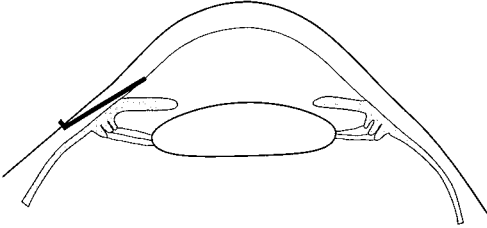
a. The Incision



b. The Tunnel (shaded), note its shape and size



c. Completing the incision into the eye



d. To show the profile of the scleral tunnel

blade in spirit based povidone-iodine solution or autoclaving at a lower temperature ( $115^{\circ}\text{C.}$ ), one knife and handle may remain sharp for a whole operating list or more.

First establish a plane of cleavage about half the thickness of the sclera and then enlarge by making sweeping movements with the crescent knife, both downwards 2 mm into clear cornea, and then sideways at the edge of the incision, to make a tunnel which stretches from limbus to limbus at the ten o'clock to two o'clock position (see fig. 5.53b). The tunnel must be **long** and enter the eye well into clear cornea in order to be self-sealing and free of the risk of iris prolapse. It must be **wide** in order to accommodate the entire nucleus. Make sure that the incision is wide enough throughout the length of the tunnel, especially in its outer part as shown by the arrows in fig. 5.53b.

### **c) Completing the incision into the anterior chamber** (fig. 5.53c)

This is done with a sharp pointed Phako keratome knife which can be re-sterilised in the same way as the crescent knife. Advance the tip of the keratome to the end of the tunnel and then point it sharply backwards so that it will enter the cornea. It is much easier and safer to cut against a firm eye than a soft eye, so once the first opening into the anterior chamber has been made the anterior chamber should be filled with visco-elastic solution like methylcellulose. It is usually easier to make the cut with the sharp edge of the keratome as it goes into the eye rather than as it comes out of the eye. Having a firm eye also lessens the risk of creating a rip of the corneal endothelium or Descemet's membrane, which is a possible complication of cutting obliquely through the cornea. In particular, the internal opening into the anterior chamber must be wide, reaching all the way to the limbus at each end of the incision. The tip of the keratome should disappear beyond the margin of the clear cornea at each end of the internal opening. If the keratome is getting blunt, it may fail to cut the full width of the incision. The profile of the completed incision is shown in fig. 5.53d.

Once the internal opening is complete, many surgeons use the same keratome knife to make an incision at the top of the lens capsule, known as the endocapsular or "envelope" technique (see fig. 5.24). This can alternatively be done with a cystitome, but the incision in the lens capsule must be from pupil margin to pupil margin and big enough to allow the nucleus to come out easily. Some surgeons prefer a complete  $360^{\circ}$  "can opener" capsulotomy (see fig. 5.25). This makes it easier to mobilise the nucleus into the anterior chamber, but it risks damaging the corneal endothelium from the nucleus rubbing against it. The endocapsular method is probably safer.

## **2. The Mobilisation of the Nucleus**

The nucleus must first be separated from the capsule. This is done by hydrodissection. It is then mobilised by rotating it. Once fully mobile an instrument can be passed behind the nucleus without any risk of rupturing the posterior capsule. *A well dilated pupil is absolutely essential for a satisfactory mobilisation of the nucleus.* It enables the surgeon to see what he or she is doing, and allows the mobilised nucleus to come forwards either wholly or partly into the anterior chamber. The best way to ensure that the pupil is well dilated is described on page 58–9.

Hydrodissection is described on page 105 and fig. 5.27 and is done using the infusion fluid and a blunt cannula such as a lacrimal cannula. This can be mounted on a syringe or connected to the drip bottle. (It may help to raise the drip bottle a little to get more pressure.) The hydrodissection fluid should pass around the nucleus both behind and in front of it. Some surgeons like to hydrodissect in two planes, one just under the capsule and the other deeper into the lens between the nucleus and the epinucleus. This is to make the nucleus as small as possible so it will come out of the tunnel more easily. However this second hydrodissection is not really necessary. When the nucleus passes out through the tunnel, the epinucleus strips itself off and stays behind in the anterior chamber.

Once the nucleus has been separated from the capsule by hydrodissection, it must be mobilised by rotation. The blunt cannula tip is used as a lever to spin it round. For this the cannula is placed at the side of the nucleus. Once it has rotated through 180 degrees it is well mobilised. If it is difficult to rotate, the sharp tip of an irrigating cystitome can be placed in the nucleus and will give better leverage.

Very mature cataracts with fluffy white cortex are usually fairly easy cases. The fluffy cortex can easily be washed out of the eye during hydrodissection, and there is often a fairly small nucleus and no obvious epinucleus. First wash out the cortex in front of the nucleus, then at the side of the nucleus. Sometimes this loose cortex can be removed from behind the nucleus as well, but always maintain a flow of fluid in the cannula, especially if the tip is behind the nucleus, as this protects the posterior capsule. Also press the *shaft* of the cannula very gently backwards on to the posterior side of the wound, as this keeps the wound open and helps the cortex come out.

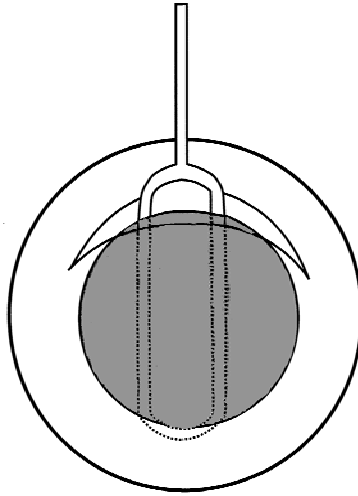
### 3. The Removal of the Nucleus

This is the hardest and most critical part of the operation but there should be no problem if:

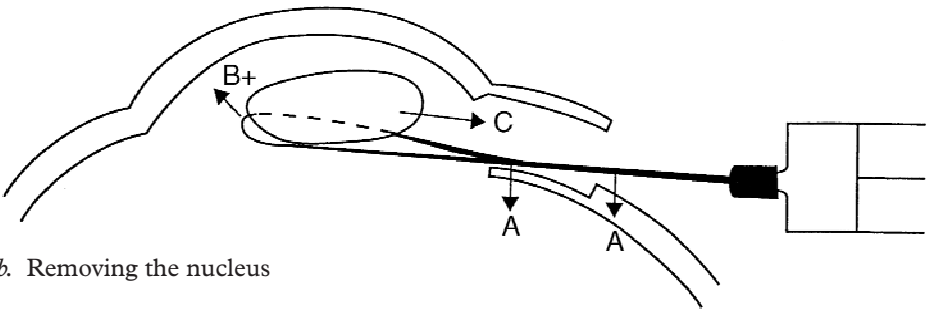
1. The incision has been properly constructed,
2. The pupil is well dilated,
3. The lens nucleus has been fully mobilised,
4. The nucleus is not excessively large.

Various instruments have been described for removing the nucleus. The easiest is probably the irrigating lens loop, or vectis.

- First inject some visco-elastic fluid, both between the nucleus and the corneal endothelium to help preserve the corneal endothelium, and also just behind the upper tip of the nucleus to help insert the lens loop behind the nucleus without damaging the posterior lens capsule. *The cannula should be used at the same time to check the two sides of the tunnel to make sure that the whole length of the tunnel is wide enough.*
- The irrigating loop **must** be at the correct angle to open the tunnel by pressing **backwards** on the posterior lip of the incision (see fig. 5.54b). This can be achieved in different ways.



a. A small lens loop is inserted behind the nucleus



b. Removing the nucleus

*Fig. 5.54* Removing the nucleus, to show the position of the lens loop.

- i. Strong traction on the superior rectus suture will rotate the eye downwards so that the loop is at the correct angle.
  - ii. Alternatively a toothed forceps can grasp the eye at the limbus and rotate it down.
  - iii. If the patient has a rather sunken socket it also helps to have a backward curve on the shaft of the irrigating loop, so that the shaft is pressing backwards on the posterior lip of the tunnel.
  - iv. A slightly different way of putting backward pressure on the posterior lip of the wound is to do the entire operation at the side of the eye rather than at the top. This is called a temporal approach. From this direction it is very easy to put backward pressure on the wound. The main disadvantage is that the wound is not covered by the upper lid at the end of the operation
- The lens loop, mounted on a 5 ml syringe, is now inserted through the incision into the eye. The loop is advanced so its tip is just under the upper pole of the nucleus (this is why the previous injection of visco-elastic is helpful), and it is

then slowly advanced further into the eye just behind the lens nucleus. It helps at this stage to inject fluid very gently through the loop as this keeps the posterior capsule well clear of the loop. Once the tip of the loop has reached the lower pole of the lens nucleus, then the nucleus can be extracted (fig. 5.54 a).

- It is particularly important to have both the *shaft* and the *tip* of the lens loop in the correct position. The *shaft* should be pressing *downwards* (fig. 5.54b) on the posterior lip of the incision (as shown by the arrows A). This opens up the tunnel. However the *tip* of the loop should be resting just behind the nucleus. It should not press downwards or it might rupture the posterior capsule, nor should it press upwards or it might rub the nucleus against the endothelium
- There is always a great temptation to lift the tip of the loop forwards towards the cornea to “scoop” the nucleus out of the eye. This temptation must be resisted. It will rub the nucleus against the corneal endothelium and permanently damage the endothelium. It will also close off the tunnel instead of opening it. Instead, the nucleus comes slowly out of the eye because of the hydrostatic pressure created by more forceful pressure on the plunger of the syringe (see B in fig. 5.54b). This raises the pressure in the anterior chamber, and this pushes the nucleus into the tunnel (see arrow C).
- Once the nucleus has started to enter the tunnel, then the lens loop is gently withdrawn whilst maintaining the hydrostatic pressure of the injection (B in fig. 5.54b) and also maintaining the downward pressure on the posterior part of the wound (A in fig. 5.54b). As the loop is gently withdrawn it will help to drag the nucleus through the tunnel and out of the eye.
- Once the nucleus is properly in the tunnel and no longer in the anterior chamber, the lens loop can, of course, be used as a kind of scoop because upward pressure now can no longer damage the corneal endothelium and the nucleus itself will keep the tunnel open. Once the nucleus is almost out of the eye, the pressure on the syringe should be released.
- When the nucleus has been removed, the rest of the operation is the same as for a standard extracapsular extraction. The epinucleus is usually removed in one piece by forceful irrigation and the cortex is removed by irrigation combined with aspiration using a Simcoe cannula. The IOL is then inserted, the anterior capsule excised and the anterior chamber very thoroughly washed out.

### ***Wound closure***

There should be no need to suture the sclera, unless the tunnel is very wide. Some surgeons like to close the conjunctiva with one suture at the corner of the conjunctival flap, or the conjunctiva can be sealed with a cautery tip which acts like a “spot weld”. If the conjunctiva is left unsutured it always seems to adhere very rapidly to the sclera probably because of the slight inflammatory reaction from the cautery or diathermy.

## Difficulties and complications

The most common problems encountered are:

1. The nucleus enters the tunnel but will not come out through the external opening. There are several possible solutions to this.
  - The keratome can be used to widen the external opening of the tunnel.
  - There is a simple manoeuvre which may help to remove a nucleus which has definitely entered the tunnel but has become stuck in it. A lens dialler can be passed along the tunnel in front of the nucleus and the pointed tip of the dialler then turned down into the front of the nucleus. This with the lens loop which is behind the nucleus will act as a “sandwich” enabling the nucleus to be pulled out through the tunnel.
  - The lens loop can be pressed forward into the upper pole of the nucleus to chip off its upper part. If the nucleus is then rotated round through 90 degrees using a cannula with visco-elastic, the nucleus diameter will be less and it should now come out through the tunnel.
2. The iris keeps prolapsing through the wound. The reason for this is either that the tunnel does not go far enough into the clear cornea, or else the pupil is not well enough dilated.
3. The nucleus may remain posterior to the iris or it may not be possible to mobilise it at all into the anterior chamber. The usual reason is that the pupil is too constricted or possibly the capsulotomy hole is not large enough.
4. If the nucleus is particularly large and hard it will not enter the tunnel at all. This should have been recognised before the beginning of the operation.

The best solution to problems 2, 3, and 4 is to convert to a standard sutured extracapsular extraction. The incision in the sclera is extended right along the edge of the shaded area in fig. 5.53 and the incision can be further enlarged around the limbus with corneal scissors or a blade.

There are some skilled surgeons who use techniques and instruments to divide a particularly large nucleus into two or more fragments inside the eye, and in this way can still remove a large nucleus using a sutureless tunnelled incision.

5. Bleeding from the incision may occur especially if the tunnel is very wide. If the bleeding is into the eye, patience is usually the best treatment and it should stop. The blood can then be washed out. A small limbal puncture will enable the anterior chamber to be filled with irrigating fluid under slight pressure, and this should prevent any further bleeding by compressing the bleeding point (tamponnade).

For the expert, sutureless cataract surgery is an extremely quick and effective operation which can be performed in almost every patient. For the beginner, it is definitely harder than the standard extracapsular technique. Apart from obtaining some “hands on” training, it is best to wait until one feels entirely confident with



routine extracapsular surgery, and to choose easier cases. These are younger patients, those with posterior subcapsular cataracts and mature cataracts with white, fluffy cortex. Hard cases are those with dense nuclear sclerosis and those with partially dilated pupils. It is also essential to have a really sharp crescent knife and keratome to make the incision, and a well-manufactured lens loop – preferably one with more than one irrigation hole at the tip. Grooves in the front surface of the loop will also help it to pull the nucleus through the tunnel.

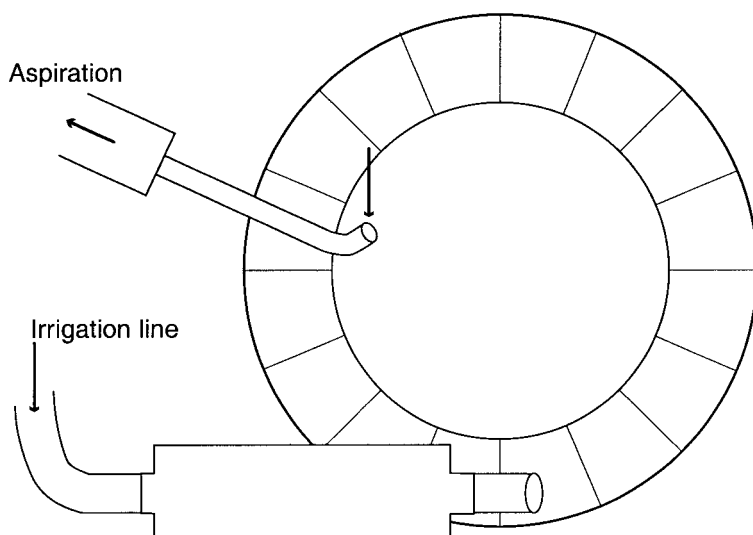
## Alternative methods.

There are various alternative ways of removing the nucleus.

The technique pioneered by Dr Henig from Nepal uses a small, sharp hook made from a hypodermic needle rather than a lens loop to remove the nucleus. It is passed behind the nucleus in the same way as the loop and then the tip is rotated into the lower part of the nucleus, and the nucleus then drawn out through the tunnel.

The technique pioneered by Professor Blumenthal from Israel uses an anterior chamber maintainer (see fig. 5.55). This is inserted at the lower part of the cornea to maintain the hydrostatic pressure throughout the operation. A plastic lens glide (see fig. 5.81) is used to open the tunnel and remove the nucleus.

Videos describing the techniques are also available (see end of chapter for details).



*Fig. 5.55* An anterior chamber maintainer inserted through the lower part of the cornea. There is also an aspiration cannula inserted into the anterior chamber.

## Cataracts in Children

Cataracts in children are a special problem. It is often difficult to decide what is the best operation and when to do it. If the operation has complications, the vision of the patient may be affected for their entire life. ***It is best for children with cataracts to be treated by experienced surgeons with special training in paediatric eye surgery.*** This however may not always be possible. This section is obviously for those who do not have a special paediatric training.

Even amongst experts there is considerable disagreement about some aspects of treatment of paediatric cataract. The following rules are generally accepted by all paediatric cataract surgeons:

1. Dense or mature bilateral congenital cataracts should be operated on as soon as possible. The definition of a dense or mature cataract is when the cataract is completely white and no red reflex at all can be seen even after pupil dilatation. If surgery is delayed macular fixation is impaired and the eyes will develop nystagmus. This means that the child will never see well in spite of successful surgery later. Rubella infection in pregnancy is a common cause of bilateral congenital cataract. These children sometimes have retinal damage or microphthalmos as well as cataracts, and even with a successful operation may have poor vision. They may also suffer from deafness and congenital heart defects.
2. Partial or immature cataracts should have surgical treatment postponed until the child is older, and even then should only have an operation if the vision is getting worse. A partial or immature cataract is one in which some red reflex can still be seen when the pupil is fully dilated. These are usually lamellar cataracts when just one layer of the lens is affected with the central part of the lens and the peripheral part of the lens being fairly normal. Alternatively the cataract may affect just the very centre of the lens or the anterior or posterior pole of the lens just under the capsule, and there are other patterns of partial congenital cataract.
3. Unilateral congenital cataract with the other eye normal should not normally be treated. These eyes are nearly always very amblyopic. Trying to treat the amblyopia by putting an occlusive patch over the good eye is very disturbing for the child and the family and the benefit is uncertain. Some paediatric experts do however treat unilateral cataracts and claim limited success in some cases.
4. The aphakia must be corrected without delay either with spectacles or IOLs. Contact lenses in children are not usually possible unless there are expert contact lens fitting services available. The use of IOL's in children is particularly controversial. Until a few years ago IOL's were only inserted in adults. However in the last few years they have been inserted in children as well with encouraging results. Also there is the problem in less developed countries of getting small children to keep and wear aphakic spectacles. For these reasons IOLs are now recommended for young children as well. There remain however several problems with the use of IOL's in children:
  - The posterior capsule will always become thickened and will require a posterior capsulotomy, which may need to be repeated.

- The age at which IOLs can be implanted is constantly being reduced. Nowadays most experts would recommend that IOL's should not be inserted in children under 2 years, although this is being done in some specialist centres. The eye is not fully grown until after the age of 2. It is extremely difficult to insert an IOL and the correct power will change as the child's eye grows.
- IOL's are harder to insert in children than in adults.
- Damage to the eye from a poorly inserted IOL can affect the child for the rest of their life. There is a very slight risk of causing sympathetic ophthalmia which will damage the other eye as well.

Foldable acrylic lenses are considered by many to be very suitable for children, because they can be inserted through a much smaller incision. Anterior chamber lenses **must never** be inserted in children.

Traumatic cataracts should if possible be given IOL implants. The other eye will be normal and the full vision from the injured eye will not be used without an implant. However, if the eye has inflammation or scarring from the injury it is better to be safe and not insert an implant.

Surgeons with special paediatric training are inserting IOLs more and more frequently nowadays. If a surgeon without paediatric training has to operate on a child because there is no possibility of referral, the decision about IOLs is very difficult. A successful result is so much better for the child, but complications can leave the child blinded for life. *For a non-expert, it is probably better to be "safe than sorry" and a cataract extraction without an IOL is a much simpler and safer option. There is no reason why an IOL cannot be inserted later when the child is older or improved facilities or expert treatment are available.*

### ***The Surgical Treatment of Congenital and Juvenile Cataracts***

Both the lens and the eye of a child differs in several ways from an adult.

1. *The eye is smaller, especially in children under two, and the anterior chamber is more shallow.* Because the orbital bones of a child are not fully grown, there is much less space in the orbit for the eye. Therefore as soon as the eye is incised, it is very difficult to maintain the anterior chamber depth. This makes surgery much harder and risks damaging the corneal endothelium. Therefore all surgery in children should be done through very small oblique incisions so that the instrument seals off the incision.

One very helpful instrument for this is an anterior chamber maintainer (see fig. 5.55). This is inserted obliquely into the anterior chamber through a small bevelled incision at the lower limbus. It is anchored at the lower limbus and attached to a drip bottle. It gives constant irrigation into the anterior chamber and maintains it at full depth. It also keeps the posterior capsule and vitreous well back throughout the operation.

It is particularly useful when operating on children with either congenital, developmental or traumatic cataracts. With an anterior chamber maintainer providing irrigation, the aspiration can be done through a single one way

cannula rather than a two way Simcoe cannula. This is also inserted into the anterior chamber through a small oblique incision to maintain a full depth anterior chamber (see fig. 5.55).

2. *The anterior capsule is very elastic.* Once it has been punctured it tears very easily towards the equator of the lens. The ideal method of anterior capsulotomy in children is the continuous capsulorexis (see page 104 and fig. 5.26) This removes the central part of the capsule and leaves intact the peripheral capsule attached to the suspensory ligament. Unfortunately capsulorexis is extremely difficult to perform in children as the capsule usually tears outwards towards the equator once it has been incised. Another problem in performing the anterior capsulotomy is that with white opaque cataracts the tear in the capsule is very difficult to see. Therefore in practice the most appropriate type of capsulotomy is to try to do a small “can opener” capsulotomy which will make a small tear in the centre of the anterior capsule (see page 104). The only way to actually remove any of the capsule is with a vitrectomy machine which takes very small “bites” from the anterior capsule.
3. *A child’s lens does not have a hard nucleus.* Therefore irrigation/aspiration alone is required to perform extracapsular extraction in children.
4. *Posterior capsular thickening and opacification occurs in almost all cases.* Therefore making a hole in the posterior capsule at the time of operation (a primary posterior capsulotomy) is recommended providing that the circumstances for this are suitable. Unfortunately new lens fibres grow very vigorously in young children. Even after a primary posterior capsulotomy new lens fibres may often grow across the anterior face of the vitreous, thus forming a new opaque posterior capsule. It is therefore much better to remove part of the posterior capsule and the anterior vitreous at the same time as the cataract extraction.
5. Just as in adults, cataracts in children can become degenerate. The capsule may be calcified, and the lens may liquefy or absorb by itself.

For all these reasons cataract extraction in a child can be performed much better with a vitrectomy suction cutter if it is available. Obviously general anaesthetic is essential. If Ketamine is used as an anaesthetic agent, a local anaesthetic block should also be given to control eye movements. A superior rectus stitch makes the exposure easier.

### ***Method for Congenital or Juvenile Cataract Extraction using a Vitrectomy Suction Cutter***

The only reliable way of removing some of the anterior capsule, some of the posterior capsule and the anterior vitreous is with a vitrectomy cutter. It can also remove the opaque lens matter itself. The operation is sometimes called a *lensectomy*.

1. The anterior chamber maintainer is inserted.
2. The vitrectomy probe is inserted through a small tunnelled incision at the upper limbus. Both these incisions should be self-sealing and not leak excessively during the operation nor require sutures post-operatively. If they do leak

they can be sutured. Some vitrectomy machines have an irrigation sleeve if an anterior chamber maintainer is not available.

3. The vitrectomy cutter is used to “nibble” a hole in the centre of the anterior capsule, and through this hole the lens matter itself is then cut and aspirated. Finally a small hole is made in the centre of the posterior capsule and the anterior part of the vitreous also removed with the vitrectomy probe.
4. Alternatively the vitrectomy cutter can be inserted into the lens from behind the iris. The incision should be only 2 mm from the limbus. (Babies do not have a pars plana of the retina and so the incision must be close to the limbus to avoid the retina.) In this case the lens cortex is removed first, then the posterior capsule and the anterior vitreous and finally the anterior capsule.

### ***Method for Congenital or Juvenile Cataract Extraction using Conventional Instruments***

1. Insert the anterior chamber maintainer if available.
2. Make another very small bevelled incision at the limbus and through this carry out a small can opener capsulotomy (see page 104).
3. Through this same incision, aspirate the lens cortex with a single port aspirating cannula (see fig. 5.55).
4. If an anterior chamber maintainer is not available, the irrigation and aspiration must be done with a two way Simcoe cannula. This should be inserted through a very small bevelled incision at the limbus just large enough to fit the cannula. It is easier for the surgeon and safer for the eye if the anterior chamber remains full throughout the operation. An incision which makes a small tunnel will ensure this, and is also self-sealing so does not require sutures. The external opening is just in the sclera, and the internal opening just in the cornea. After light cautery or diathermy to the superficial scleral vessels, a knife is used to start the incision in the sclera. A tunnelling knife or a small angled keratome is then used to make the tunnel which enters the anterior chamber about 2 mm inside the limbus. (See fig. 5.53d for the profile of a tunnelled incision.) The incision need only be large enough for a two way cannula. Whether using a one way or a two way aspirating cannula try to keep the anterior chamber deep all the time, and try to remove as much cortical lens matter as possible. If there are some hard pieces that will not be aspirated the incision may have to be slightly enlarged to wash them out of the eye by forceful irrigation.
5. *The Posterior Capsulotomy.* Because of the high risk of posterior capsular thickening, many surgeons would recommend making a small hole in the posterior capsule at the time of cataract extraction. The posterior capsulotomy can be done with the point of the cystitome, By making a small cut in the centre of the capsule. Unfortunately if the anterior vitreous is not removed, posterior capsular thickening may still occur even after a posterior capsulotomy, because the lens fibres of children can grow across the anterior vitreous face to form another opaque membrane.

If a primary posterior capsulotomy is done the vitreous must not come forward into the anterior chamber. Therefore the incision must be watertight and the anterior chamber must be maintained at full depth all the time. The use of visco-elastic fluids or an anterior chamber maintainer may be very helpful for this. If the vitreous does come forward into the anterior chamber, the eye may develop *pupil block glaucoma* (see page 139). This may occur immediately after the operation or a long time later.

Sutures are not usually needed after cataract surgery in children, because a small tunnelled incision should be self sealing. If there is any doubt that the wound is water-tight, one or more sutures should be used to secure the wound.

## **Intraocular Lens Implants in Children**

If it has been decided to implant an IOL, these must be posterior chamber implants. The basic method is the same as for an adult. Because of the small eye and the difficulty in keeping the anterior chamber deep, various other steps may be helpful.

- Always use a tunnelled incision to insert the lens, and try to use an anterior chamber maintainer as well. These both help to keep the anterior chamber deep.
- Foldable acrylic lenses are recommended because they can be inserted through a smaller incision and are said to cause less postoperative capsular opacification.
- It is often helpful to insert the lens dialler through a very small separate incision rather than the main incision. This helps to keep the anterior chamber deep.
- If a primary posterior capsulotomy and anterior vitrectomy has been done, some people advise placing the lens optic behind both the anterior and posterior capsule. The haptics of course should be in the ciliary sulcus or the capsular bag. This is said to further reduce the risk of posterior capsular thickening.
- An alternative way is to insert the IOL with the posterior capsule intact. The vitrector is then used to carry out an anterior vitrectomy and a posterior capsulotomy through a pars plana incision.

### *Postoperative care*

This is basically the same as for an adult, but special precautions must be taken and much longer and more intensive follow-up care given.

- Posterior capsular opacification. This is extremely common after an ordinary extra-capsular extraction and may occur even after a primary posterior capsulotomy. It is obviously very unlikely following a lensectomy. If the capsule is thickened a capsulotomy should be done.
- Pupil block glaucoma. This is a particular risk after a posterior capsulotomy. Mydriatic drops may lessen the risk, and if it occurs an iridectomy may be needed.

- Retinal detachment. There is a risk of this occurring at any time in the child's future.
- Refraction and vision testing. This should be done every year. If the child does not develop good vision, educational advice and low visual aids may both be very helpful.

## Cataracts and Glaucoma

Sometimes patients may require treatment for both cataract and glaucoma. When both cataract and glaucoma are present in the same eye it may be difficult to decide the best plan for the treatment. It is very important to assess how much of the visual loss is from the cataract, and how much from glaucoma. In each case a very careful clinical examination is absolutely essential to avoid performing an unnecessary or harmful operation. As well as a careful examination of the eye, helpful clues may come from the history, from examining the other eye, from gonioscopy etc.

Both cataract and glaucoma cause loss of vision. Cataract causes a loss of visual acuity, and the vision will be restored after successful surgery. Glaucoma causes a loss of the visual field and the sight that is lost will not be restored even with successful surgery.

The pupil reaction is normal in cataract but patients with glaucoma have an afferent pupil defect. The most valuable clinical sign of glaucoma is the appearance of the optic disc, but this may be difficult or impossible to see in an eye with cataract.

Sometimes an eye with an advanced cataract may develop secondary glaucoma as a complication. This may be *phakomorphic glaucoma* when the lens enlarges and causes secondary angle closure glaucoma, or it may be *phakolytic glaucoma* when fluid lens protein leaks out and obstructs the trabecular meshwork.

Sometimes patients who have had successful glaucoma surgery may subsequently develop a cataract in the eye.

The following are some general principles in helping to decide how to treat a patient with both cataract and glaucoma:

1. In all cases of cataract with glaucoma an extracapsular extraction is preferable to an intracapsular extraction. Glaucoma surgery has a much higher rate of failure after intracapsular extraction, because there is no physical barrier to stop the vitreous becoming incarcerated in the glaucoma drainage operation.
2. Always try to reduce the intraocular pressure to normal before the start of the operation. Operating on an eye with raised intraocular pressure risks causing an expulsive choroidal haemorrhage.
3. In certain cases it may be best to operate only on the cataract and leave the glaucoma untreated:-
  - If there is a risk of angle closure glaucoma this is prevented by cataract extraction.
  - If there is open angle glaucoma but it is only mild, the intraocular pressure may often fall just from removing the cataract.
4. If a cataract extraction is performed on a patient who may later need a trabeculectomy operation for glaucoma, a corneal incision is best. This leaves



the conjunctiva unscarred, which makes any subsequent glaucoma operation more likely to succeed.

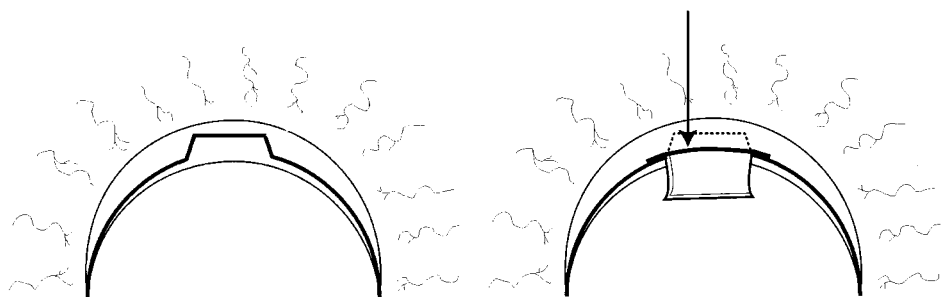
If a cataract extraction is performed in an eye which has previously had a successful glaucoma operation, the incision should be through the cornea so not to disturb the successful glaucoma drainage procedure.

5. In some cases the surgeon may decide to operate on the glaucoma and the cataract at the same time. This has obvious practical advantages for the patient by avoiding two operations, and in most cases the results are good.

### *Cataract Extraction Combined with Trabeculectomy*

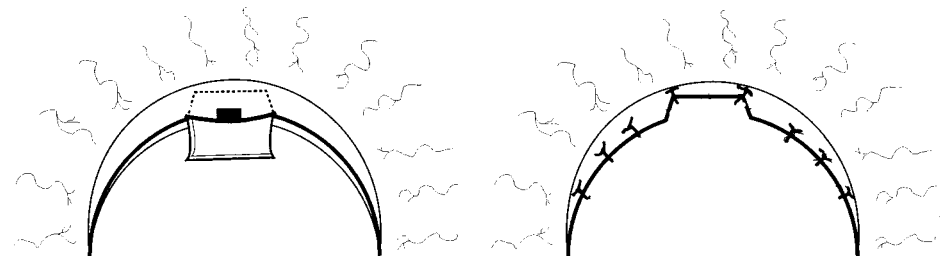
This may be planned in several different ways.

1. A standard trabeculectomy may be performed (see page 187). On completing the operation the cataract is then extracted through a corneal incision in front of the trabeculectomy and without disturbing it. This is probably the simplest method.
2. A standard extracapsular cataract extraction may be performed but with an alteration to the shape of the incision in the sclera (fig. 5.56). A partial thickness flap of sclera is made, the anterior chamber entered in the usual way, and the cataract removed and the IOL inserted. Then a peripheral iridectomy is performed, and a small piece of deep corneo-scleral tissue excised just as for a trabeculectomy. The incision in the sclera is then sutured, and then the conjunctiva is sutured very tightly. Finally the test described on page 194 should be done to confirm that the aqueous is draining satisfactorily.



Line of incision in the superficial Sclera

The arrow shows the line of incision into the Anterior Chamber



Piece of Corneo Scleral tissue excised

Resuturing of the Corneo Scleral wound

*Fig. 5.56* The incision for combined cataract extraction and trabeculectomy



3. The technique of small incision cataract surgery can be very easily modified to function as trabeculectomy as well. The tunnel is constructed, but a small horizontal slit is made into the posterior wall at the limbus, before opening the tunnel into the anterior chamber. After the lens has been removed and the IOL inserted, this slit is enlarged to remove a piece of trabecular tissue. Through this hole an iridectomy is done. The scleral incision and the conjunctiva should be sutured just as for a trabeculectomy.

An alternative method is to place the incision for small incision cataract extraction in one part of the eye, and the incision for the trabeculectomy in another part.

For all combined cataract and trabeculectomy procedures the conjunctiva must be tightly sutured down to make sure that the aqueous does not leak out of the subconjunctival space. Testing that the trabeculectomy is draining and the conjunctival flap is watertight as described on page 201 and fig. 6.18 is also very helpful.

## Intracapsular Cataract Extraction

*(Authors note. Intracapsular cataract extraction is no longer being taught in nearly all teaching institutions. However there are still many places where it is being carried out, and it does not require an operating microscope. Results comparing the results of the two different techniques sometimes show only a slight benefit from extracapsular extraction especially where YAG lasers are not available. There are also a few cases which have subluxated lenses or calcified capsules where intracapsular extraction is best. I have therefore decided not to delete this section.)* With an intracapsular extraction, the entire lens is removed by rupturing the attachment of the lens capsule to the suspensory ligament.

### 1. The incision

The principles of the incision are basically the same as for extracapsular extraction but the incision needs to be larger because a larger space is needed to remove the entire lens within its capsule. The size of the incision needs to be just less than half way round the limbus, about 170 degrees in all (see fig. 5.57).

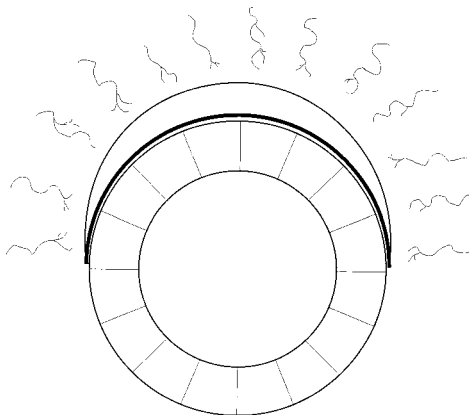
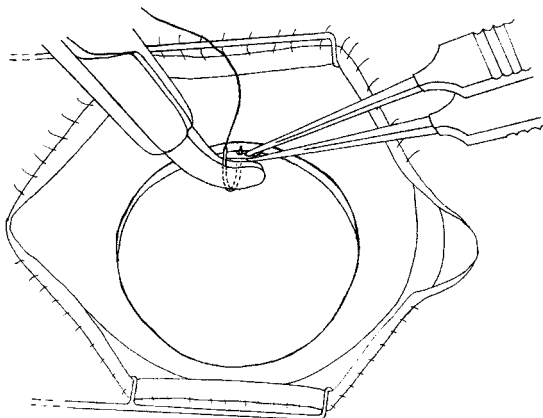
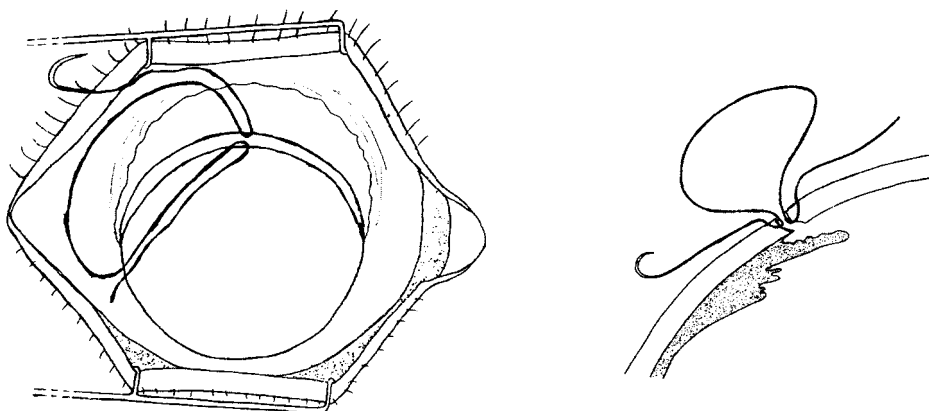


Fig. 5.57 To show the size and position of the incision for intracapsular extraction

### Inserting the pre-placed suture



*Fig. 5.58a* Starting to insert the pre-placed suture



*Fig. 5.58b and 5.58c* The suture is then looped well clear of the wound

## 2. *Pre-placed Sutures*

Once the incision has been completed most surgeons place one or more sutures in the wound at this stage, but of course these sutures are not tied. The reason for inserting sutures at this stage is that the eye is more stable with the lens in place. Once the lens has been removed, manipulations on the wound edge while inserting the sutures may press on the eye and force some vitreous into the wound or even out of the eye. If one or more sutures are in place before the lens is extracted these sutures can be tied immediately after the lens has been removed. This secures the wound, allowing further sutures to be inserted without disturbing the wound edge very much. The only problem caused by placing sutures before removing the lens is that these sutures may get in the way when trying to remove the lens. Therefore only one or at most two pre-placed sutures should be used. The sutures should be inserted to about half the depth of the cornea and once inserted they should be looped out so that they do not get in the way when the cornea is lifted (figs. 5.58).

A pre-placed suture has another advantage. The assistant can use fine forceps to hold the loop of the suture which goes through the cornea, and in this way open up the eye for the surgeon. Otherwise the assistant has to grasp the cornea itself with forceps which is harder to do and may damage the corneal endothelium.

### 3. The Iridectomy

There are two reasons for doing an iridectomy:

1. *To prevent pupil block glaucoma.* After an intracapsular extraction the vitreous face may rest against the pupil and stick to the pupil margin. This can stop aqueous circulating into the anterior chamber and cause a condition known as pupil block glaucoma (fig. 5.59). This can be prevented by making a small hole in the iris. This may be a peripheral iridotomy when a small slit is made in the iris, or a peripheral iridectomy (fig. 5.60) when a small hole is made in the iris.
2. *To make the cataract extraction easier.* The iris is a sphincter lying in front of the lens. If this sphincter is divided the lens will come out more easily. A full or broad iridectomy divides the iris sphincter (fig. 5.61). This makes removing the cataract easier especially if the pupil is not well dilated. After a full iridectomy, grasping the lens with the cryoprobe or the capsule forceps is easier. Therefore a full iridectomy is recommended for intracapsular extraction if the pupil will not dilate well or the surgeon is very inexperienced.

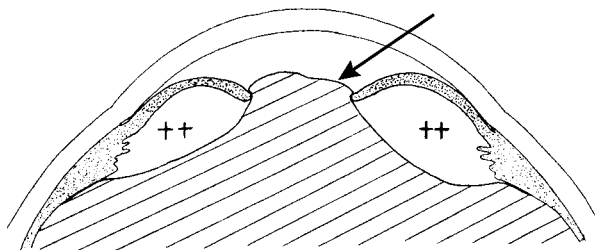


Fig. 5.59 Pupil block glaucoma. A knuckle of vitreous (see arrow) blocks the pupil and prevents circulation of the aqueous

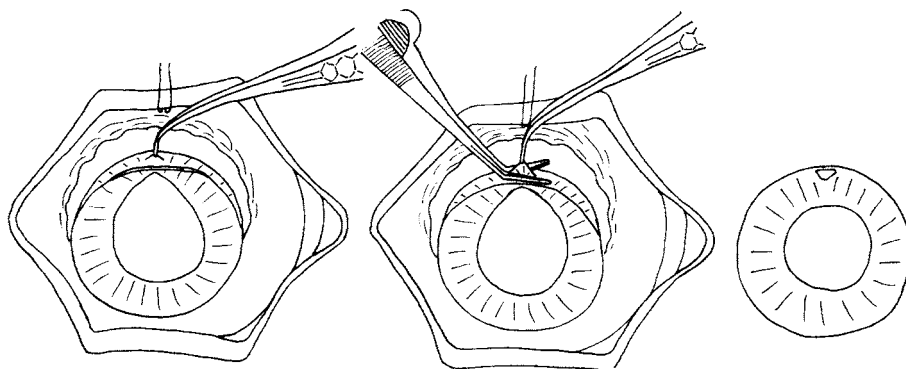


Fig. 5.60 A peripheral iridectomy

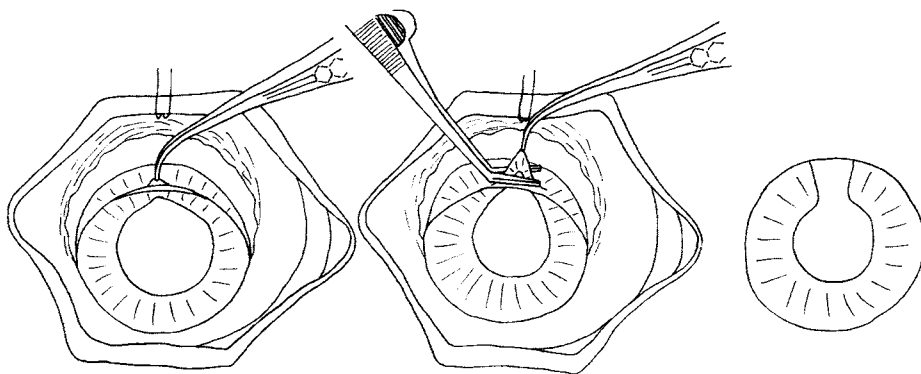


Fig. 5.61 A full or broad iridectomy

There are however three advantages of a peripheral iridotomy or iridectomy over a full iridectomy:

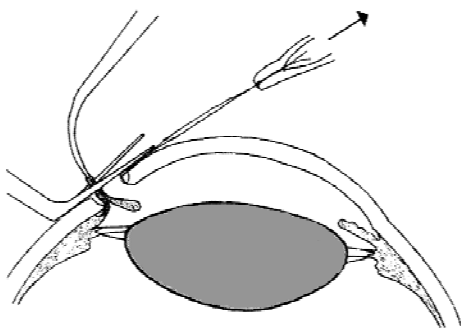
- With a peripheral iridectomy the iris sphincter is intact. An intact iris sphincter means that the pupil will constrict in bright light and on accommodation. This improves the visual acuity and depth of focus of the eye and prevents glare. However in most cases patients do not seem to have any problems with their vision after a full iridectomy, as the iridectomy is usually hidden by the upper eye-lid.
- An intact iris helps to prevent vitreous loss by holding the vitreous back.
- If an IOL is planned, then a full iridectomy makes IOL fixation very difficult.

### *Technique of iridectomy*

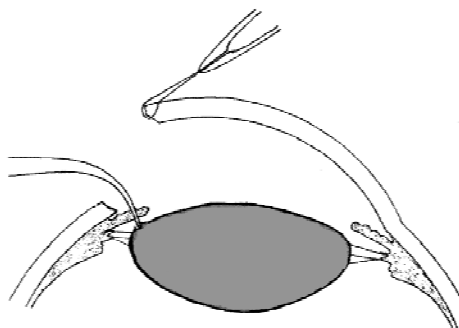
1. The assistant gently lifts the cornea at 12 o'clock preferably by traction on the pre-placed corneal suture (fig. 5.62).
2. For a *peripheral iridectomy*, grasp the iris fairly near its root with fine iris forceps. Lift it very gently and gradually, then using deWecker's scissors excise the small portion of iris tissue held in the iris forceps (fig. 5.60 and 5.62).
3. For a *peripheral iridotomy*, the scissors cut into the iris without excising any tissue.
4. For a *full iridectomy*, the iris is grasped about half way between its root and pupil margin and a slightly larger segment of iris including the pupil margin is excised with deWecker's scissors (fig. 5.61).
5. Take great care not to touch the lens capsule with the iris forceps (fig. 5.63).

### *Bleeding into the Anterior Chamber*

Sometimes the view of the lens is obscured by bleeding into the anterior chamber. This may come from the incision into the eye or from the iridectomy. Blood usually clots quite quickly in the anterior chamber. A few tiny blood clots on the surface of



*Fig. 5.62* Performing the iridectomy



*Fig. 5.63* Damage to the lens capsule from the iris forceps

the iris do not matter. However if they obscure the view of the lens they should be removed. This is best done with a cellulose sponge or with gentle irrigation using balanced salt solution or normal saline. All is now ready to remove the lens.

#### ***4. The Extraction of the Lens***

First check the eye is suitable to proceed with an intracapsular extraction. For this there should be no evidence of pressure on the open eye. The lens should be resting, without forward pressure, slightly behind and clear of the cornea. If the lens is coming forwards and pressing against the cornea, and especially if the wound is gaping a little or there is a small horizontal fold across the centre of the cornea (fig. 5.35), it is likely that something is pressing on the open eye. Therefore the vitreous is likely to prolapse out of the eye when the lens has been removed.

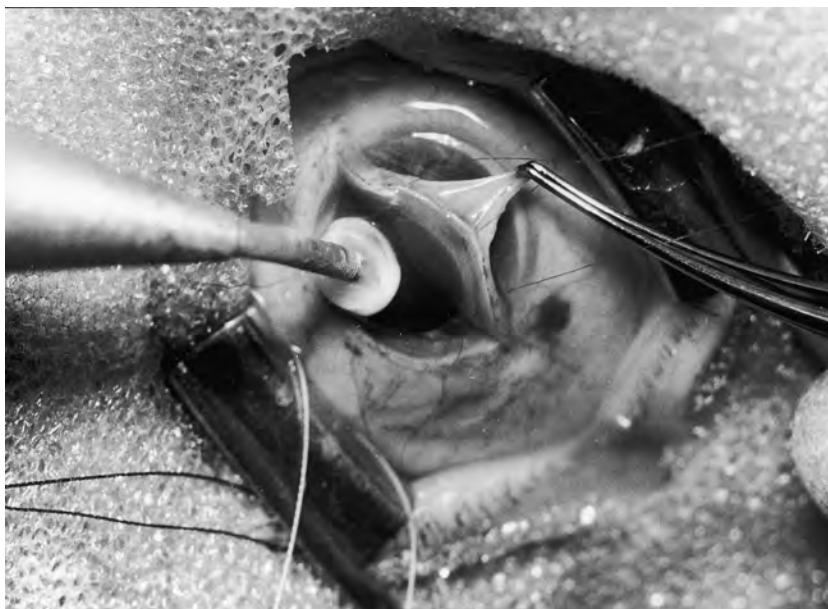The causes of pressure on the eye and how to manage it have already been described on page 112–3. The assistant should lift up the speculum and if there is still pressure on the open eye despite lifting up the speculum, it is best to change plans from an intracapsular to an extracapsular cataract extraction. If you are satisfied that you can proceed with an intracapsular extraction, then lift the edge of the cornea to check that the incision is both complete and big enough to allow the lens to be removed.

#### ***Methods of Intracapsular Extraction***

There are several different instruments used for intracapsular extraction. Only 3 of these will be described here: the cryoprobe, capsule forceps and the lens loop (sometimes called the “Vectis” loop). The cryoprobe is the best method, but the other methods will be described in case a cryoprobe is not available or not functioning

##### ***The Cryoprobe***

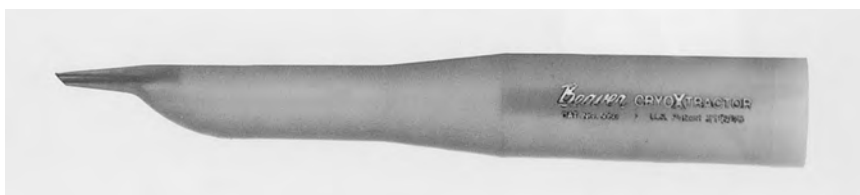This is a small probe which can be cooled so that it forms an ice-ball at its tip which adheres to whatever the tip of the probe is touching. If it is in contact with the lens it will adhere to it and so it can be lifted out of the eye. The most sophisticated cryoprobes work off nitrous oxide or carbon dioxide gas. The gas is released under




*Fig. 5.64* A photograph of cryo-extraction of the lens with a carbon dioxide probe

some pressure through a very fine jet at the probe tip and this cools the temperature of the tip down to  $-50^{\circ}\text{C}$ . This then forms an adherent ice-ball in the tissues on which it is resting (fig. 5.64). The main disadvantage of the cryoprobe is that it will stick very firmly to whatever it touches. It can cause serious intraocular damage if it sticks to the iris or the endothelial cells lining the inside of the cornea. Most cryoprobes therefore have a rewarming circuit so that the tip can be rapidly rewarmed to melt the ice-ball if it is sticking to the wrong tissue. The greatest advantage of this type of cryoprobe which gets very cold is that the ice-ball forms inside the lens capsule in the substance of the lens and so sticks to it very firmly and securely. The disadvantages are that the machine is expensive and the probe is difficult to sterilise. The recommended method of sterilisation is a formalin cupboard or careful autoclaving. The probe can be disinfected by immersing the tip in methylated spirits, acetone or a similar disinfecting solution which will evaporate. Unfortunately these fluids do not kill all micro organisms and the cryoprobe tip must be thoroughly rinsed before use inside the eye.

A more simple cryoprobe is formed by a plastic cylinder with a silver rod at its tip (figs. 5.65, 5.68 and 5.69). Freon gas from a small pressurised container is injected



*Fig. 5.65* A hand held cryoprobe which uses freon gas



*Fig. 5.66* Capsule forceps for intracapsular extraction

under pressure into the cylinder and the gas liquefies. This liquid rapidly evaporates and as it does so becomes cold. The plastic cylinder is held with the tip down, so that the low temperature of the boiling freon is transmitted along the silver rod and forms an ice-ball at its tip. The sides of the silver rod are insulated with plastic so that only the tip gets cold. This type of cryoprobe is cheap and easily portable and can be boiled or carefully autoclaved, but has some disadvantages. It does not get as cold as a cryoprobe which works off carbon dioxide or nitrous oxide gas, and so the ice-ball is not as adherent. There is no rewarming apparatus, so if the probe sticks to the iris or cornea, the only way of separating it is to irrigate the eye with balanced salt solution or normal saline to melt the ice-ball.

### *Capsule Forceps*

Capsule forceps (figs. 5.66 and 5.71 to 5.74) are delicate forceps with smooth rounded cups which can grasp the lens capsule. In this way the lens can be pulled out of the eye. There are 2 different methods of doing this. The lens may be grasped at its lower end and somersaulted or “tumbled” out of the eye. Alternatively the lens may be grasped at its upper pole and lifted or “slid” out of the eye. The sliding technique is generally considered easier to learn than the tumbling one so will be described.

There are several disadvantages of capsule forceps:

- The grip on the lens capsule is a delicate one, so the capsule can easily tear. Some capsules are relatively tough while others are very fragile.
- If the cataract is intumescent the lens capsule is swollen and tense, and it is then very difficult or impossible to grasp the lens capsule with forceps at all.
- Because forceps do not grip the lens as securely as a cryoprobe, the lens has to be pushed out of the eye with the help of the lens expressor as well as being pulled by the capsule forceps. This increases the risk of vitreous loss.
- The technique of extraction with capsule forceps is harder to learn than the cryoprobe.

For all these reasons the use of capsule forceps has declined since the introduction of cryoprobes. However capsule forceps have certain advantages. They can be easily and effectively sterilised. They are not expensive, do not require expendable gases, nor is there any equipment that can go wrong at the vital moment. Also the part played by the assistant is not so critical. It is however very important that the





*Fig. 5.67* The lens expressor (above) and the lens loop (below)

forceps are in good condition. The ends should meet along their length and they must not be damaged. Damaged forceps are more likely to rupture the capsule.

*The Lens Loop (figs. 5.67 and 5.75 to 5.79)*

This is a small metal loop, which is used to “tumble” or somersault the lens out of the eye. It can also be used to scoop out the lens if it has dislocated downwards into the vitreous.

*The Expressor (fig. 5.67)*

With all three methods of extraction a lens expressor is held in the other hand, and placed near the lower limbus. In this way the lens is both “pushed” and “pulled” out of the eye at the same time. Careful use of the expressor is absolutely essential when using the forceps or the loop to extract the lens. It is not so essential with the cryoprobe.

*Alpha-chymotrypsin*

Alpha-chymotrypsin (Zonulysin) is an enzyme which dissolves the suspensory ligament of the lens. It does not seem to harm any of the other intraocular structures but it may cause a slight rise in intraocular pressure for 1–2 days post operatively. It is irrigated into the eye under the iris usually with a lacrimal cannula placed in the iridectomy. Only about 0.5 cc of appropriate solution is required. After about 3 minutes the suspensory ligament of the lens should be dissolved. Some people like to irrigate the eye with balanced salt solution or saline after the chymotrypsin has worked, but many surgeons think this is unnecessary. Alpha-chymotrypsin makes intracapsular cataract extraction easier by dissolving the suspensory ligament so that the lens can just be lifted out of the eye. It is not essential. It is especially helpful for an inexperienced surgeon using forceps, or in a middle-aged patient whose suspensory ligament may be quite tough. There is much less of a commercial market for it now because intracapsular extraction is so rarely performed in the Western world, and it is not so easy to obtain.



### ***The General Principles of Intracapsular Extraction***

The aim of the operation is to remove the entire lens intact in its capsule from the eye. Obviously the suspensory ligament of the lens must either be broken mechanically or dissolved with alpha-chymotrypsin. Using the cryoprobe or capsule forceps, there are three manoeuvres which will help to break the suspensory ligament:

1. Pulling on the lens with the cryoprobe or the capsule forceps. The main complication of excess pulling is that the lens capsule may rupture before the suspensory ligament does.
2. Pushing the lens out of the eye with the lens expressor. The main complication of excess pushing is that the suspensory ligament will break and the vitreous will be pushed out of the eye rather than the lens.
3. Rotating the lens. This provides a shearing force on the suspensory ligament and in this way helps to rupture it.

Using the capsule forceps, it is usually necessary to carry out all three manoeuvres at the same time, pulling, pushing and rotating. Using the cryoprobe a much firmer grip on the lens is achieved. Therefore the lens can be pulled from the eye with much less rotation or pushing.

If alpha-chymotrypsin is used, the suspensory ligament is weakened to such a degree that the lens can be simply lifted from the eye with minimal pulling and little or no pushing or rotation. The main disadvantage of alpha-chymotrypsin is the risk of chemical or bacterial contamination when it is injected into the eye. It is also quite expensive, and may not be easily available now that intracapsular extraction is not performed in the developed world.

For an intracapsular extraction using the lens loop, the principle is slightly different, because the lens is “tumbled” or somersaulted out of the eye so that the lower pole of the lens comes out first.

### ***The Technique of Intracapsular Extraction Using the Cryoprobe***

1. The assistant must lift the edge of the cornea preferably by gentle traction on the pre-placed suture at 12 o'clock (figs. 5.68 and 5.69). Lifting the cornea the right way is very important. Do not allow the assistant to touch the corneal endothelium with the forceps. Lift up the edge of the cornea enough to insert the cryoprobe into the eye without it touching the back of the cornea or iris. The cornea must only be lifted and not folded right over.
2. The surface of the lens must next be dried by mopping away any aqueous from it. If it is wet the ice-ball will not form easily at the tip of the cryoprobe, and instead it will spread to the iris and cornea causing damage. The aqueous is mopped away using small cellulose sponges which also should not touch the back of the cornea. If the assistant has a spare hand he can carry out this drying, but if his other hand is holding the speculum to stop any pressure on the eye, then the surgeon himself will have to dry the eye. If the pupil has contracted down a little or a peripheral iridectomy has been done, it may be necessary to retract the iris in order to make enough room to apply the

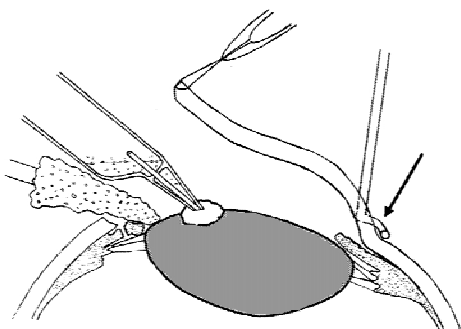


Fig 5.68

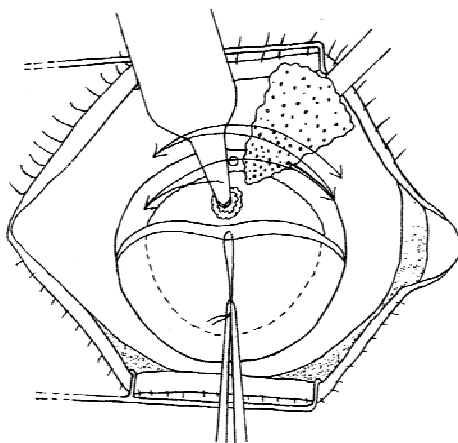


Fig 5.69

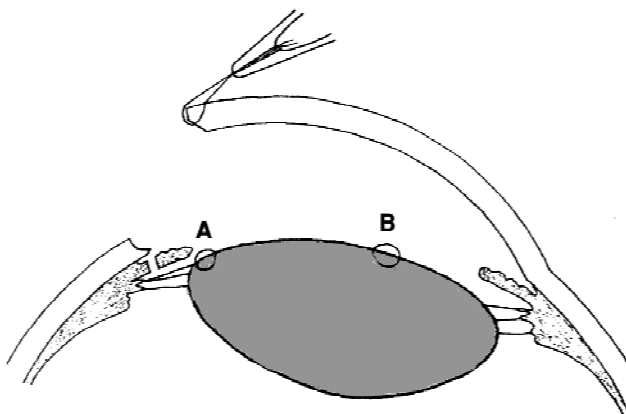
*Figs. 5.68 and 5.69* Intracapsular extraction with a freon gas cryoprobe. The assistant is retracting the cornea

Note:

- i. the position of the sponge swab to retract the iris as well as drying the lens.
- ii. the use of the expressor at the lower limbus in Fig. 5.68 to tilt the upper part of the lens forward.
- iii. rocking the cryoprobe from side to side to help rupture the suspensory ligament (zonules)

cryoprobe to the surface of the lens. This can be done by retracting the iris at the 12 o'clock position with the same small cellulose sponge or using a metal iris retractor. If a full iridectomy has been done or the pupil is well dilated there is no need for iris retraction.

3. Now rest the cryoprobe on the surface of the lens half-way between its centre and upper equator (fig. 5.68), and wait for a few seconds so that it is frozen not just to the surface of the lens, but also causes an ice-ball to form inside the lens. This will happen very quickly with a cryoprobe that runs off carbon dioxide or nitrous oxide. It may take 10 seconds or more with a cryoprobe which uses freon gas.
4. Sometimes it is easier to apply the cryoprobe to the cataract if a lens expressor is placed at the lower limbus and pressed very gently on the eye (fig. 5.68). This presses the lower pole of the lens back and so pushes the upper pole of the lens forward. This makes it easier to apply the cryoprobe and to get it to stick to the lens. However the surgeon may not have a spare hand free to use a lens expressor in this way. Pressure with a lens expressor is not often needed to help extract the lens when a sophisticated cryoprobe is used, because the cryoprobe gets such a good grip of the lens. The small cryoprobe which uses freon gas does not become so cold and so does not adhere so well to the lens. Therefore some expression of the lens is often required as well.



*Fig. 5.70* Wrong positions to apply the cryoprobe. At “A” it is likely to stick to the iris, at “B” it is likely to stick to the back of the cornea. Compare with Fig. 5.68.

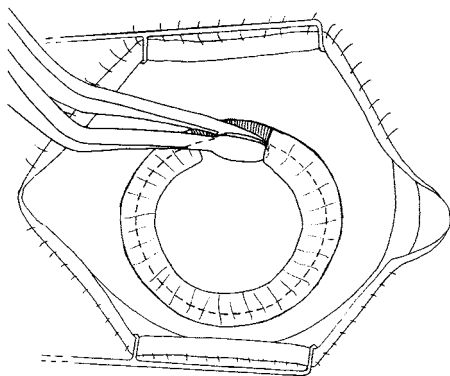
5. Once the cryoprobe has adhered firmly to the lens, start lifting it very gently out through the wound, while at the same time rocking it from side to side to apply a slight rotational force to the lens (fig. 5.69). This helps to rupture the suspensory ligament. As the upper pole is lifted forwards by the cryoprobe, the iris retractor or cellulose sponge being used to retract the iris can be removed. The lens should peel away from the suspensory ligament and can be lifted completely out of the eye. If the suspensory ligament is particularly tough or if a cryoprobe using freon gas is being used, then gentle pressure at the lower limbus with the lens expressor may help to extract the lens.
6. As soon as the lens starts coming out of the eye and the tip of the cryoprobe is clear of the wound, the assistant should release the traction which is holding open the corneal edge of the wound.

The most common complication of cryo-extraction is that the probe adheres to the iris or the back of the cornea (fig. 5.70). If this happens the probe should be rewarmed as quickly as possible if it has a rewarming device, if not the eye must be irrigated with balanced salt solution or saline to melt the ice-ball. The lens should then be dried and the cryoprobe reapplied in the correct position.

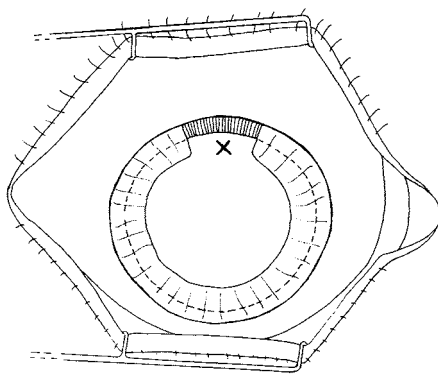
The other two possible complications of extraction with a cryoprobe are capsule rupture described on page 152 and loss of vitreous described on page 113–5.

### ***The Technique of Intracapsular Extraction with the Capsule Forceps***

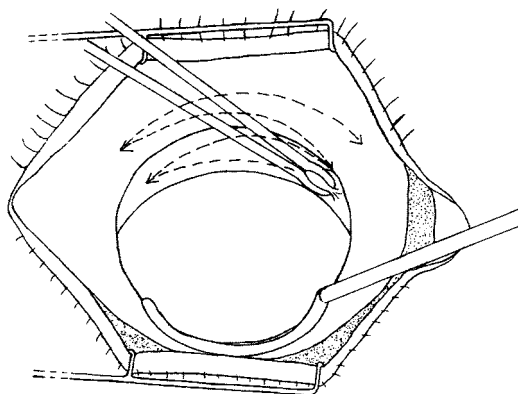
This requires a more delicate touch from the surgeon, especially if alpha-chymotrypsin is not being used. However there is less need of skilled assistance because it is not necessary to dry the eye, and the forceps are less likely to damage the cornea or the iris. Indeed it is possible to do a forceps lens extraction without any assistance at all. There are 3 secrets to success when using capsule forceps and the sliding method:



*Fig. 5.71* The correct way to apply the capsule forceps. Try to take a large “bite” of capsule



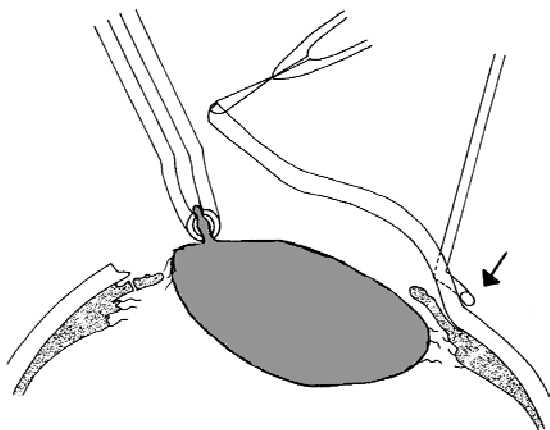
*Fig. 5.72* The correct position to apply the capsule forceps



*Fig. 5.73* Applying a rotation movement to the lens with capsule forceps

- The lens capsule must be grasped correctly. This should be done with the forceps “side on” or transversely rather than “end on” or vertically (fig. 5.71). The forceps should take a large bite of lens capsule rather than a small one, and the lens should be grasped as near to the equator as possible rather than at the anterior pole where the capsule is thinner (fig. 5.72).
- For a successful forceps extraction there must be a balance between pulling the lens out of the eye with the forceps and pushing the lens out of the eye with the expressor. If it is all “pulling” and no “pushing” the capsule is likely to rupture. On the other hand if there is excessive pushing then the vitreous may prolapse before the lens.
- Applying a rotatory force to the lens helps to rupture the suspensory ligament (fig. 5.73). This may be more effective than trying to pull or push the lens out of the eye.

If alpha chymotrypsin has been used the lens can be virtually lifted out of the eye with only very slight rotation and expression.



*Fig. 5.74* Pressure with the expressor at the lower limbus tilts the lower pole of the lens backwards and the upper pole of the lens forwards. This helps the capsule forceps to grasp the lens more securely

A right-handed surgeon usually prefers to hold the capsule forceps in his right hand and the lens expressor in his left, but some people prefer the other way round.

1. The assistant should first lift the edge of the cornea a little.
2. The surgeon should then press gently at the lower limbus with the lens expressor. This will push the lower part of the lens slightly backward and so tilt the upper part of the lens slightly forward (fig. 5.74).
3. The forceps should now be applied at the top of the lens near the equator. A broad iridectomy or a very well dilated pupil both help to get a good grasp of the lens in the correct place. It is quite a common mistake to catch the iris as well as the lens capsule in the forceps especially if the pupil is not very well dilated. The surgeon must make sure he has a good view of exactly what the forceps is grasping. The assistant can help by retracting the iris with a small cellulose sponge. Once a good grip has been secured the forceps should be rotated first towards the 10 o'clock position and then towards the 2 o'clock position (fig. 5.73). The gentle pressure should be maintained all the time at the lower limbus of the eye with the lens expressor. Some people like to keep the pressure point on the lower limbus exactly opposite the forceps so that when the forceps are rotated to 10 o'clock the tip of the expressor is at 4 o'clock. When the forceps are rotated to 2 o'clock the expressor is at 8 o'clock.
4. As the suspensory ligament begins to rupture, the lens can be lifted very slowly out of the eye. All the time the capsule forceps should be slowly rotated from the 2 o'clock position to the 10 o'clock position and back again. Gentle pressure should be maintained on the lower limbus with the lens expressor.

Some surgeons use even more rotation to break the suspensory ligament. Using this technique the capsule forceps are applied at the 2 o'clock position rather than at the 12 o'clock position and they are then rotated to the 10 o'clock position. Whilst maintaining very gentle pressure with the lens expressor, the

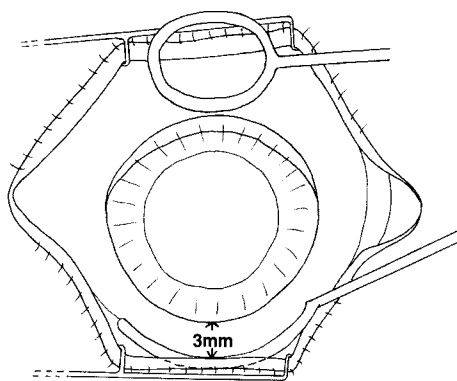


Fig. 5.75 To show the position of the lens loop and the lens expressor for expressing an intumescent cataract

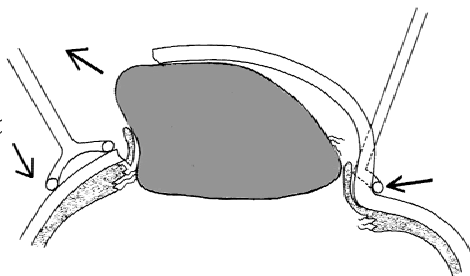


Fig. 5.76 Gentle pressure with the lens loop and pressure and massage with the expressor

forceps are opened to let go of the lens which is grasped again at 2 o'clock and rotated once more to 10 o'clock. In this way the lens is "wheeled" out of the eye.

### ***The Technique of Intracapsular extraction with the lens loop***

When using the lens loop much firmer pressure must be applied with the lens expressor. Instead of being placed at the lower limbus it is placed about 3 mm below the lower limbus.

*For intumescent cataracts.* The lens loop can be used for intracapsular extraction of intumescent cataracts if a cryoprobe is not available. (Obviously capsule forceps will not grip the capsule of an intumescent cataract.) The technique is as follows:

1. Place the lens loop on the posterior scleral lip of the incision and press very gently back into the eye (fig. 5.75). This has two effects. It slightly opens up the lips of the wound. It also presses back the upper pole of the lens.
2. Now rest the lens expressor 3 mm below the lower limbus (not at the limbus) and apply gentle pressure and massage to it. This pressure which is behind the lens will tend to push the lower pole of the lens forwards.

An intumescent cataract contains fluid and so the shape of the lens will be moulded by this pressure. The lower (inferior) fibres of the suspensory ligament will be stretched and will rupture, and the lens will "somersault" or "tumble" out of the eye (fig. 5.76).

If an extraction with the lens loop is planned the iridectomy should not be done until after the lens has been extracted. For this technique it is vital that the lower (inferior) fibres of the suspensory ligament rupture before the upper (superior) fibres so that the lens somersaults out of the eye. An intact iris helps to keep the upper pole of the lens and the upper fibres of the suspensory ligament intact.

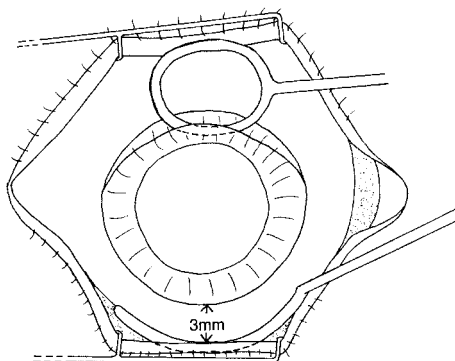


Fig. 5.77

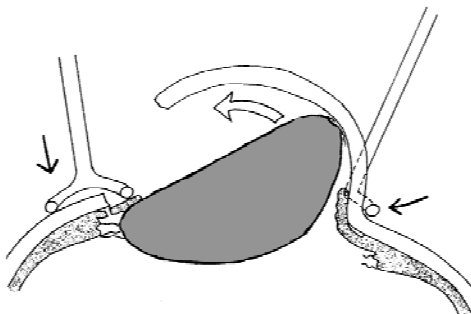
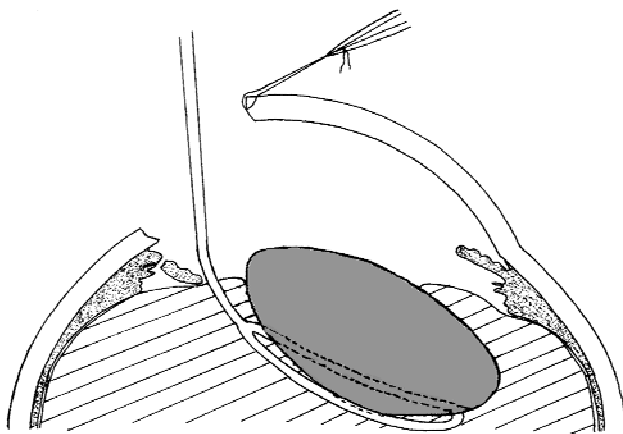


Fig. 5.78

*Fig. 5.77 and 5.78* To show the position of the lens loop and lens expressor for expressing a solid cataract. Note that the lens loop is actually inside the eye and is in a different position from Figs. 5.75 and 5.76

*For other cataracts.* This same technique of using the lens loop and the expressor to “somersault” the lens out of the eye can be used for intracapsular extraction of any cataract and not just an intumescent cataract. However solid cataracts will not mould as easily as intumescent ones, so the lower fibres of the suspensory ligament will not be stretched or ruptured so easily. The lens expressor is placed in just the same place, but the lens loop must be placed actually in the eye and pressing down on the upper pole of the lens (figs. 5.77 and 5.78). Quite a lot of pressure may be necessary and the suspensory ligament may suddenly rupture causing vitreous loss or dislocation of the lens backwards into the vitreous. With skill and training it can become a very effective technique where only basic facilities are available.

*For a dislocated lens.* If the lens has dislocated into the vitreous, the loop is used to get right under the lens so that it can be scooped out of the eye (fig. 5.79). Inevitably some vitreous will be lost. Sometimes the lens is only partially dislocated



*Fig. 5.79* The use of the lens loop for a subluxated or dislocated lens

or sub-luxated. This means that some but not all of the suspensory ligament fibres have ruptured. Always insert the loop where the fibres of the suspensory ligament have ruptured and make sure that the loop gets right under the lens before scooping it out of the eye. With a partially dislocated lens a cryo-extraction is a possible alternative to the loop.

### ***Complications of Intracapsular Extraction***

The two main complications of intracapsular extraction are rupture of the lens capsule and vitreous loss.

#### ***Rupture of the lens capsule***

This is more common using capsule forceps than the cryoprobe, because the cryoprobe gets a much better grip on the lens. Capsule rupture may occur for several reasons:

- The lens capsule is sometimes very weak.
- The capsule forceps may be applied incorrectly or may be in poor condition.
- The surgeon may try to pull the lens from the eye before the suspensory ligament has ruptured.
- If using a cryoprobe, it usually occurs because the probe has only frozen to the capsule and not formed an ice-ball inside the lens.
- If the incision is too small, there may not be enough room for the intact lens to be removed from the eye.

If the capsule rupture is small, it may be possible to reapply the cryoprobe or the capsule forceps and to get another grip of the lens so that an intracapsular extraction can be completed. However, often this is not possible because the rupture is too large.

If the capsule breaks when the suspensory ligament is still intact, the best way to proceed is as follows:

1. Express the nucleus of the lens from the eye in the same way as for an extracapsular extraction (see page 106–9).
2. The surgeon may then choose to convert to an extracapsular cataract extraction by irrigating and aspirating the remaining cortical lens material from the eye, and just leaving the posterior capsule intact.
3. Alternatively the intracapsular extraction may be completed by removing the rest of the capsule and cortical lens remnants. The assistant should lift the corneal flap to allow a good view of the anterior chamber. Then grasp the edge of the ruptured capsule with capsule forceps and gently pull the capsule containing the remaining pieces of lens cortex out of the eye (fig. 5.80). It is best to do this with a capsule forceps in each hand. Use the first capsule forceps to grasp the edge of the ruptured capsule, and then the other capsule forceps to get a more secure grip of the capsule. In this way the ruptured capsule containing cortical lens remnants can be very gradually pulled out of the eye “hand over hand”.



Occasionally the capsule ruptures after the suspensory ligament has been broken, and then the surgeon is faced with a difficult situation as to how best to remove the lens. If the lens is almost out of the eye it may be possible to express the lens nucleus from the eye and then using the capsule forceps pick out of the eye any fragments of capsule and lens cortex that remain. If both the capsule and the suspensory ligament have ruptured and the lens is still in the eye do not try to express the lens or the nucleus. Almost certainly vitreous will come out through the wound and the lens or its nucleus may well be pushed down deeply into the vitreous. If any lens matter ends up deep in the vitreous it will set up a chronic and persistent inflammatory reaction in the eye. Instead use the lens loop, identify where the suspensory ligament has broken and place the lens loop through the gap in the ligament so that it lies behind the lens. Then scoop the lens out of the eye.

### *Vitreous Loss*

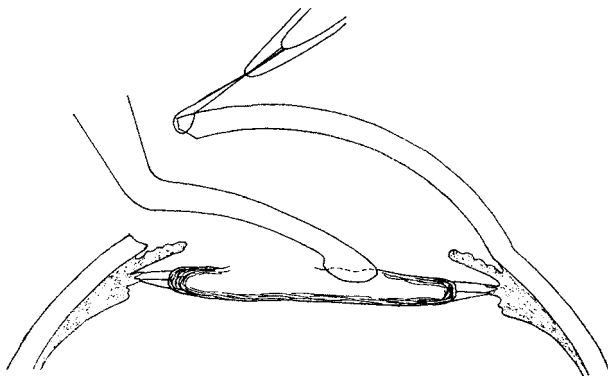
There are usually two reasons for vitreous loss during intracapsular extraction:

- From some external pressure on the eye (page 112–3). Either the assistant should have lifted the speculum to overcome this pressure or the surgeon should have planned an extracapsular and not an intracapsular extraction.
- From too much pressure on the lens expressor by the surgeon during the extraction, which pushes the vitreous out of the eye.

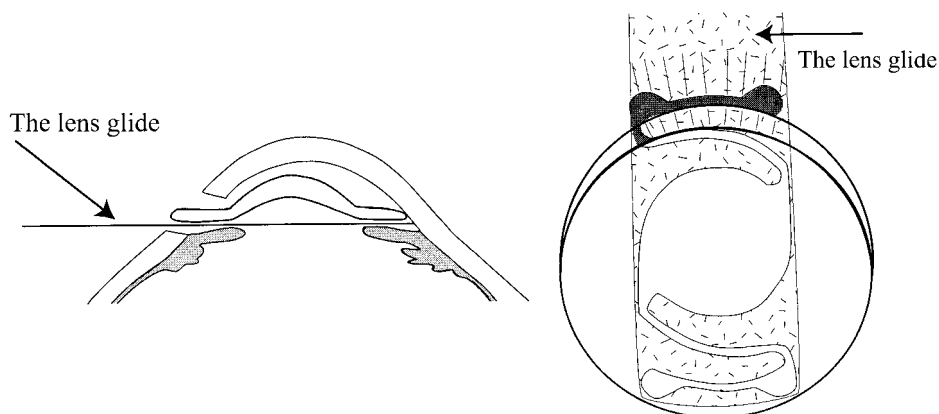
The management of vitreous loss has already been described on page 114–5.

### ***Insertion of Anterior Chamber Intraocular Lenses***

When inserting an anterior chamber intraocular lens the haptics need to be the right size (diameter), as well as the optic power of the lens being correct. The standard lens is designed so that it has a four point contact in angle of the anterior chamber between the back of the cornea and the front of the iris (see fig. 5.8, page 85). If the size is too small the lens will move in the anterior chamber. This will cause chronic uveitis and in particular it will damage the endothelial cells of the cornea causing corneal oedema. If the size of the haptics is too large, they will cause pressure in the anterior chamber angle and this causes persistent tenderness



*Fig. 5.80* The use of the capsule forceps to remove capsule remnants



*Fig. 5.81* Inserting an anterior chamber intraocular lens. To show the position of the lens glide and how the IOL slides on the surface of it

and pain in the eye. The normal way of sizing the intraocular lens is to measure the horizontal corneal diameter (white sclera to white sclera) and add 1 mm to give the correct size (diameter) for the haptics. Recently an anterior chamber lens has been introduced with three point contact in the angle which is more flexible so that there is only one size of haptic. It has two point contact inferiorly and only one superiorly. The anterior chamber depth must be maintained with either viscoelastic fluid, air or irrigating fluid. When using air or irrigating fluid, it is very helpful to partly close the incision with two interrupted sutures leaving a gap of 7 mm through which to insert the intraocular lens.

Inserting an IOL in the anterior chamber is made much easier if a small sheet of plastic called a “lens glide” is first inserted into the anterior chamber right down to the bottom of the anterior chamber angle between the iris and the cornea (fig. 5.81). The intraocular lens can then slide down the front surface of the lens glide, so that the lower haptics of the lens rest nicely in the lower part of the anterior chamber angle. Without a lens glide, the lower haptics may catch against the lower iris rather than sliding into the anterior chamber angle. Once the lower haptics are well placed in the angle, the lens glide is removed and the superior haptics are tucked under the scleral lip of the incision so as to lie in the upper part of the anterior chamber angle. At this stage the pupil should be round and central, confirming that the haptics of the lens have not got caught in the iris. Care must be taken that the intraocular lens does not touch the eyelashes or skin and so become contaminated with skin bacteria, and also that it does not touch the posterior surface of the cornea and cause damage to the corneal endothelium. It is often quite difficult to prevent the haptics from catching on the iris and so causing a distorted pupil, especially if the anterior chamber is shallow. Many surgeons like to constrict the pupil at this stage with pilocarpine or acetyl choline (Miochol), because it makes the insertion of the IOL easier. Any drop used when the eye is open must be sterile and non toxic to the corneal endothelium, and free of preservatives. The use of these miotic drops is not essential. When using an anterior chamber lens the surgeon must check that the iridectomy or iridotomy is patent.

### ***Wound closure***

Once the lens is in place then the wound can be sutured. The preplaced sutures should now be tied, unless this has already happened.

Usually a total of five interrupted sutures is enough to secure the wound. Wound closure has already been described on pages 30–33. If viscoelastic fluids have been used, they should be washed out of the eye once the wound has been closed.

### **Post-operative Care**

The routine post-operative care for all different types of cataract surgery is essentially the same. Modern cataract surgery is both safe and effective. Serious post operative complications are not common but may occur even with the very best of care. Different surgeons have different ideas about post operative care and management, and the care that is given will depend upon the circumstances and treatments available. Therefore basic principles will be discussed here rather than rigid rules.

#### ***Routine post operative examination of the eye***

The eye must be examined from time to time to make sure that there are no complications. Ideally it should be examined on the first and second postoperative days, then after one week and finally about one month after the operation. However all this may not be possible.

#### ***Mobilising the patient***

Early mobilisation is probably the biggest change in recent years in the post operative care of eye patients. Some years ago patients were kept in bed and carefully rested after an eye operation. Nowadays most patients are mobilised immediately after the operation, which can be done as an out patient. The main reason for this change is improved suture techniques. The wound is now closed securely so it is no longer necessary to immobilise the patient's head and eye waiting for the wound to heal. Early mobilisation has many advantages. It lessens the risk of post operative venous thrombosis, urinary retention, chest infection and constipation. It is much more pleasant for the patients themselves, they can be discharged from hospital sooner, and nursing care is easier. Indeed many surgeons are quite happy to operate on patients as outpatients and allow them to walk off the operating table and go straight home. This may not be practical in rural situations or where the patient's understanding is poor.

#### ***Protecting the eye***

Although the wound is closed securely, the eye must still be protected from the patient rubbing it or from something or someone else knocking or hitting it. It is therefore routine practice to apply a shield to the eye immediately after the operation. Applying a sterile pad also helps the corneal and conjunctival epithelium to heal by preventing movements of the eyelid against the eye. The pad also keeps flies off the eye.

The main disadvantage of a pad is that bacteria multiply more rapidly in the conjunctival sac when the eye is padded. Most surgeons would not keep the eye padded for more than one, or at most two days post operatively. If some protection

is still required this can be given by placing a shield across the eye but leaving it unpadded.

### ***Prevention of infection***

Post operative infection in the eye is a disaster. Sometimes with prompt and energetic treatment some or all the sight may be saved, but frequently the eye is lost. ***The only way to avoid post operative infections is by keeping strictly to the rules of good theatre procedures and by good surgical technique. Nearly all infections enter the eye at the time of surgery.*** Hygiene and cleanliness in the post operative environment is much less important. Giving lots of antibiotics pre- and post operatively is no way to cover up for bad theatre procedures or surgical techniques. They do not usually prevent post operative infections in any case. In spite of this fact nearly all surgeons do use topical antibiotics routinely after intraocular operations.

Antibiotic ointment is applied at the end of the operation, and then either drops or ointment are given 2 or 3 times a day for another 2 to 4 weeks post operatively. Chloramphenicol is the most widely used topical antibiotic but others such as Neomycin, Gentamicin or Tetracycline may be used.

If there is any concern about contamination of the eye during the operation, then the best way of preventing post operative infection is to give a subconjunctival antibiotic injection at the end of the operation. Subconjunctival antibiotics give a high level of antibiotic in the aqueous and conjunctiva for about 24 hours and are more effective than systemic antibiotics. The most popular subconjunctival antibiotics are Cefuroxime 100 mg or Gentamicin 20 mg ( If there is a very severe risk of contamination it may be appropriate to inject both antibiotics at different sites, but do not give Cefuroxime to patients with penicillin allergy.) Most surgeons routinely give subconjunctival antibiotics post operatively to every case.

Some surgeons recommend adding antibiotic to the infusion bottle during extra capsular extraction, however the benefit of this is uncertain and there is a great risk of damaging the eye if the wrong concentration is given.

### ***Suppressing inflammation in the eye***

There is always some inflammation in the eye after an intraocular operation. In particular this inflammation will occur in the iris and ciliary body which are the most vascular structures in the eye, causing an irido-cyclitis. There will also be some inflammation in and around the wound at the corneo-scleral junction. This inflammation will be slight if the eye is otherwise healthy and the operation has been performed neatly and with minimal intraocular manipulation. Poor surgical technique or excessive intraocular manipulation will obviously increase the severity of iridocyclitis.

Iridocyclitis is more common after extracapsular than intracapsular extraction. Firstly, there is more manipulation inside the eye, and secondly, any lens cortex left in the eye will slowly dissolve in the aqueous causing an inflammatory reaction. The use of intraocular lenses will also cause some inflammation in the eye, although with good technique and a good quality lens this should only be slight. The Afro-Caribbean eye may be more susceptible to post-operative inflammation.

The standard way to reduce inflammation in the eye is to use mydriatics and corticosteroids.

*Mydriatics.* As modern surgical techniques are improving, some surgeons no longer routinely use mydriatics postoperatively. However if there is any inflammation, mydriatics should be given post operatively for a few days. Mydriatics paralyse the iris sphincter muscle and the ciliary muscle. In this way the inflammation in the iris and ciliary body is suppressed and the pupil is kept dilated. This also lessens the risk of adhesions developing between the pupil margin and the IOL or the posterior lens capsule in an extracapsular extraction, or the anterior vitreous face in an intra capsular extraction.

Atropine 1% drops or ointment given daily is the most effective mydriatic. Occasionally it causes an allergic reaction, or it can be absorbed and cause a dry mouth, tachycardia and even mental confusion in elderly patients. Homatropine, Tropicamide and Cyclopentolate 1% are alternative mydriatics which have fewer side-effects, but are less powerful and should be given twice daily.

*Corticosteroids.* Corticosteroids are the standard drug used to suppress post-operative inflammation, and most surgeons use them routinely after any intraocular operation. They can be given as drops, ointments or by subconjunctival injection. They suppress iridocyclitis and also suppress inflammatory reaction in the wound, cornea and conjunctiva caused by surgical trauma. There are many different steroid preparations; Hydrocortisone (the weakest), Prednisolone, Betamethasone or Dexamethasone (the strongest). Topical steroids are often combined with an antibiotic so that the 2 medications can be given at the same time. In an uncomplicated case it is usual to give steroid drops or ointment 3 times a day for about a month post operatively. If there is severe inflammation the drops or ointment should be given more frequently (up to every hour) and for longer.

A subconjunctival injection will deliver high levels of drug to the eye, and most surgeons routinely give a subconjunctival steroid injection (about 10 mg of prednisolone) following extracapsular extraction and especially with a lens implant. This is usually given together with the sub-conjunctival antibiotic.

### *Complications of Steroid Use*

Steroids are very effective drugs but they may cause side-effects in the eye. They can also cause systemic side-effects, but the dose given topically to the eye is too small for this. The local side-effects in the eye are:

- *Delay in wound healing.* Steroids suppress the inflammatory reaction of the body to injury, so wound healing is delayed. In practice if the wound has been carefully sutured this does not create any significant problems.
- *Increased risk of infection.* Steroids suppress the reactions of the immune system to infection. There is an increased risk of post operative infection occurring in an eye if steroids are used. Such post operative infections are fortunately rare. If the organism is a virulent one the infection is so severe that stopping local steroids will not make much difference (see page 163). However much less virulent organisms which are usually only slightly pathogenic, for example fungi or commensal skin bacteria, may enter the eye. The steroids may encourage the growth of these organisms by suppressing the natural defences of the body, and so produce a chronic but mild endophthalmitis. These

infections are rare but they are difficult to both diagnose and treat. It may be necessary to identify the organism by taking a culture of the vitreous.

- *Steroid-induced glaucoma.* In a few patients steroids can cause the intraocular pressure to rise. Exactly why this happens is not understood. However if a steroid sensitive patient is given prolonged local steroid treatment, loss of vision from steroid-induced glaucoma can occur. There is neither pain nor discomfort and the patients may not be aware that their vision is gradually fading. Usually steroids are only given for a few weeks post operatively and so steroid induced glaucoma is not a significant problem. However the intraocular pressure should be checked routinely before final discharge at one month.
- *Steroid-induced cataract.* Excessive and prolonged use of topical steroids can also cause cataract. This obviously does not matter after cataract extraction, but it can be important after other intraocular operations which do not involve removal of the lens.

### ***Prescribing spectacles***

If a lens implant has not been used, the patient will require spectacles of about +10 diopters to restore vision in the eye. With patients who are blind or almost blind pre-operatively these should be given as soon as the eye pad is removed. In ideal circumstances the patient should also have a refraction and the correct prescription lens prescribed. As the wound heals the curvature of the cornea will alter and this will affect the refraction. Ideally a final prescription for spectacles is not given until 4-6 weeks post operatively. If the patient still has quite good sight in the other eye aphakic glasses should not be given. However for patients living in isolated places, it may be sensible to give them a pair of aphakic spectacles (with a careful explanation about how and when to use them) in case the other eye develops a cataract over the next year or so.

Even after lens implant surgery some patients may want spectacles to improve their near or distance vision. These can be given as soon as the refraction is stable. This is very soon after surgery with a well sutured wound. If the sutures are too tight, there will be excessive astigmatism with the plus axis of the cylinder at 90 degrees. It may then be advisable to remove the sutures after about 3 months. If there is excessive astigmatism with the plus axis at 180 degrees, this means that the wound has not been sutured tightly enough. Either the patient must accept this or the wound must be resutured.

### ***Instructions to the Patient***

It always helps if the patient and their attendant understand the importance of postoperative treatment and exactly how to apply drops or ointment to the eye. Compliance is the word used to describe whether the patient takes the treatment correctly. Compliance is always much better if the nursing staff spend a little time helping the patient and the attendant to apply medication correctly.

## **Post Operative Complications**

Post operative complications can be divided into two groups:-

1. Early complications presenting during the first few days after the operation.

2. Late complications presenting at least a month or even years after the operation.

### ***Early complications***

Poor wound closure  
Aqueous leakage  
Iris prolapse  
Striate keratopathy  
Hyphaema  
Infection  
Iridocyclitis  
Pupil block and malignant glaucoma

### ***Late complications***

Retinal detachment  
Cystoid macular oedema  
Corneal oedema and bullous keratopathy  
Thickening of the posterior lens capsule  
Glaucoma  
Chronic uveitis  
Infection

Serious complications should be rare, but anyone responsible for the care of eye patients should know how to recognise and treat them. Most early complications can be seen with a good light and magnifying spectacles, a slit lamp is helpful but not essential. For delayed complications which involve the retina, ophthalmoscopic examination is also needed. The table on page 175 lists what to look for at a post operative eye examination and what each abnormal finding might signify.

*Post-operative complications can often lead to total or partial loss of sight. Often this can be prevented by the right treatment given promptly. Nearly all the colour plates are to show what these complications look like, so as to help identify the problem.*

## ***Early Complications***

### **Poor wound closure**

If the wound is not properly closed 2 possible complications may develop, either a leak of aqueous from the wound or an iris prolapse through the wound.

***Aqueous leakage*** (see plate 3 and 4 and 18–21)

*Symptoms and signs:*

This is usually apparent on the first post operative day. The anterior chamber will be flat or, in less severe cases, very shallow. The iris will appear to be resting up



against the cornea or very close to it. A useful way of detecting a small aqueous leak is to apply fluorescein drops to the conjunctiva. The aqueous will be seen diluting the fluorescein dye and so the site of the leak is detected. This is called Seidel's test. If a blue light is used, the leak is much more obvious. A flat anterior chamber due to wound leakage must be distinguished from a flat anterior chamber due to pupil block or malignant glaucoma (see the table on page 174).

#### *Treatment:*

Unless there is a very obvious gape in the wound, apply a firm pad and bandage for 24 hours and then examine the eye again. In many cases the wound leak will seal off and the anterior chamber will reform. If after a day the anterior chamber is still completely flat then the leak should be identified and the wound re-sutured.

### ***Iris prolapse***

#### *Symptoms and signs:*

This is usually fairly obvious. The pupil will be distorted and the iris will be seen coming out through the wound edge (see plate 5). In mild cases the iris may be trapped or incarcerated in the wound edges but not actually prolapsed out of the eye. The anterior chamber may be flat as well if the aqueous is also leaking out, but the iris tissue may plug the hole so the anterior chamber may be formed.

#### *Treatment:*

Nearly every case of iris prolapse should be treated surgically. However if a small prolapse of the iris is covered by the conjunctiva this is not absolutely necessary. The wound will eventually heal and the iris will be protected by the conjunctiva. However, if the iris is not covered by conjunctiva, it must be treated surgically.

The aims of surgical treatment for an aqueous leak or an iris prolapse are essentially the same:- to close the wound properly.

*Local anaesthetic* is sometimes difficult in these cases. Most people do not recommend retrobulbar anaesthesia in the early post operative period. If a retrobulbar haemorrhage occurs it may have disastrous consequences on a recently operated eye. If the patient is co-operative, surface anaesthesia with drops and some local anaesthetic injected into the surrounding conjunctiva will be adequate. A facial block to stop the patient squeezing is helpful. However a full nerve block may be necessary for an unco-operative patient if general anaesthesia is not available. The best way to give this is by a "sub Tenon's" injection (see page 69). This uses a blunt needle and so there is less risk of causing a retrobulbar haemorrhage.

If there is an iris prolapse it can be either excised or replaced in the eye. If seen within 24 hours and in a clean eye replacement is better, but if there is any suspicion of infection excision is safer. The iris will often have stuck to the wound edges and must first be mobilised. This is done by holding the lips of the wound and gently sweeping an iris repositor between the wound edge and the iris. Once mobilised the prolapsed iris can either be excised or replaced.

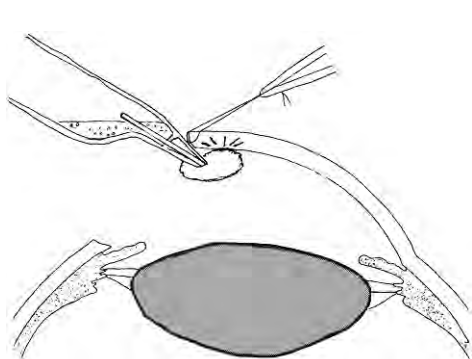
*Excision.* Grasp the prolapsed iris with forceps and cut it off with de Wecker's scissors flush with the surface of the eye.



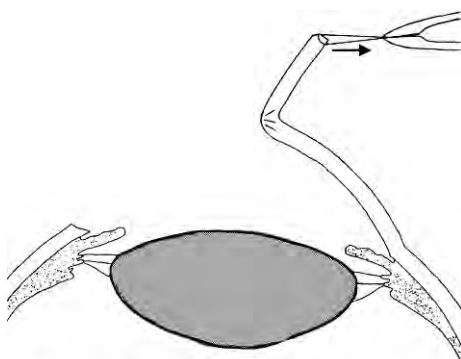
**Replacement.** Use an iris retractor to gently replace the iris back into the eye. The aqueous will usually drain from the anterior chamber whilst this is being done. The gap in the corneo-scleral wound should be repaired securely with sutures. It may be helpful if a small flap of conjunctiva is mobilised and used as an extra covering for the wound. Because of the risk of infection it is usual to give a subconjunctival antibiotic injection.

## Striate keratopathy

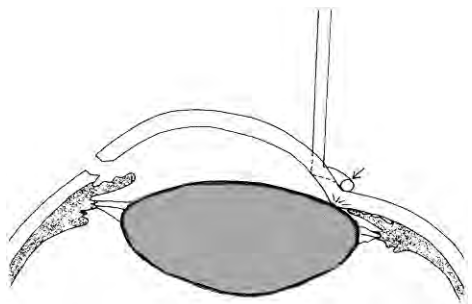
This is the name given to the appearance of the cornea post operatively if the endothelial cells have been damaged by physical or chemical injury during the operation. fig. 5.82 shows some of the different ways this can happen.



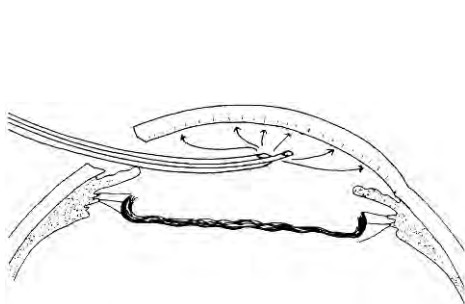
*Fig. 5.82a* Touching it with an instrument. The cryoprobe is particularly dangerous because it can damage the corneal endothelium cells by freezing as well as by touch



*Fig. 5.82b* Deforming the cornea



*Fig. 5.82c* Rubbing the lens against the cornea with external pressure



*Fig. 5.82d* Damage from faulty irrigation fluid. This is the most serious damage because it will affect the entire endothelium

*Fig. 5.82* Different ways of damaging the corneal endothelium

*Signs and symptoms:*

Irregular white opaque lines and folds appear in the deeper corneal layers and in Descemet's membrane (see plates 6 and 11). The cornea will appear hazy particularly near the incision. Striate keratopathy is always caused by damage to the corneal endothelial cells and is evidence of excessive trauma to the eye or poor surgical technique.

*Treatment:*

There is no specific treatment, although steroids may help it to clear. Damaged or destroyed endothelial cells do not regenerate but in most cases the undamaged endothelial cells compensate, and after 1–2 weeks the cornea gradually becomes clear. In severe cases striate keratopathy progresses to irreversible corneal oedema (see below, page 171).

**Hyphaema**

This means blood is present in the anterior chamber (see plates 3, 8 and 11). There may be a small amount of bleeding in the anterior chamber from the wound or the iridectomy at the time of the operation. This blood will be absorbed in a few days and does not usually cause any complications.

Rarely there may be fresh bleeding into the anterior chamber post operatively. This nearly always occurs because of poor wound closure. Delicate capillaries bridge the gap in the wound. If the sutures are not secure and the eye is rubbed or knocked, these fragile blood vessels rupture and bleed into the anterior chamber.

*Signs and symptoms:*

Recent slight bleeding will cause the anterior chamber to appear cloudy. Soon the red blood cells settle with gravity to form a layer of blood (plate 3). In severe hyphaema the whole anterior chamber becomes filled with dark blood so no iris details are visible (plate 8).

*Treatment:*

Hyphaemas will absorb in time and usually no treatment is necessary, but with a total hyphaema, the intraocular pressure may rise. It is then best to milk out the blood clot and reform the anterior chamber with saline or air. Otherwise there is a risk of developing secondary glaucoma, or the cornea becoming stained with blood pigments. It is very difficult to decide when to intervene surgically with a postoperative hyphaema. If there is *both* a complete hyphaema so the iris cannot be seen *and* a rise in intraocular pressure then surgery is essential, for most other cases it is best to wait.

*Method:*

Apply local anaesthetic blocks as described for iris prolapse or wound repair. Use an iris repositor to open up a space in the wound between 2 sutures. The thick, treacle-like fluid blood should be massaged or irrigated out of the eye, and visco-elastic fluid may help. It may be necessary to remove a corneo-scleral suture to do this. Do not try with forceps to remove formed solid blood clot which is stuck in the anterior chamber as it will probably make the bleeding start again.

## Infection

This is the most serious post operative complication and is known as acute endophthalmitis. The severity of the infection may vary according to the virulence of the organism and the number of infecting micro-organisms. Mild infections may be difficult to recognise and may not appear till some time after the operation, but a severe infection will completely destroy an eye in 24 hours. Most infections will cause blindness if left untreated, and must therefore be treated extremely seriously. Almost always the infection enters the eye at the time of surgery. Any of the pyogenic bacteria can cause endophthalmitis. Staphylococcus, Streptococcus and Pseudomonas are probably the most common species. The bacteria multiply very rapidly in the vitreous and aqueous and their toxins will quickly destroy the delicate intraocular structures. Only very rapid and very specific treatment can save the eye from total destruction and blindness.

In good eye units the incidence of endophthalmitis is about one case in a thousand. If infections are occurring much more frequently than this, the entire surgical arrangements should be carefully examined.

Obviously medical science has tried hard to think of ways of preventing postoperative infection. These include giving antibiotics prophylactically before, during or after the operation in the hopes that this will kill any bacteria.

Preoperative antibiotics are usually given as topical drops or ointment. At the time of operation antibiotics are usually given by sub-conjunctival injection. Both these methods probably help a little. There is not much evidence that giving postoperative antibiotics either topically or systemically makes much difference. Excess use of antibiotics can even be harmful by encouraging resistant bacteria to grow. Antibiotics applied topically can cause allergies and may be toxic to the conjunctiva and cornea. Systemic antibiotics can have all sorts of side effects, both minor and life-threatening.

***It cannot be emphasised too much that the only effective way to prevent postoperative infection is reliable sterilisation, excellent surgical technique and careful skin and eyelid preparation.***

### *Signs and symptoms:*

The signs of infection develop rapidly (see plates 9 and 10). They are sometimes present on the first post operative day and are usually obvious by the second day. Rarely the infecting micro-organisms may be less virulent and then the signs of infection appear very gradually after a week or two. The following are the typical features of an eye with acute endophthalmitis:

1. Pain. There is pain, tenderness and often photophobia.
2. The vision is usually affected.
3. The eyelids are often swollen.
4. There is vasodilation of the ciliary vessels around the cornea especially in the area of the incision, and the conjunctiva is often swollen (chemosis).
5. There may be mucopurulent conjunctival secretions.

6. The cornea is often hazy.
7. The anterior chamber is turbid and cloudy, containing protein exudate and circulating white cells. Later these cells settle with gravity to form a hypopyon.
8. There is sometimes a collection of pus around the incision, or one of the sutures.
9. An afferent pupil defect is a sign of retinal and optic nerve damage and that the vision will not recover to normal.

#### *Treatment:*

Intensive and urgent antibiotic treatment is necessary to save the eye but even with the most vigorous treatment the eye is often lost.

The antibiotics can be given in 4 different ways:

1. By injection into the vitreous.
2. Systemically.
3. Topically.
4. By sub conjunctival injection.

#### **1. Intravitreal injection of antibiotics**

***There is now no doubt that an intravitreal injection of antibiotic is by far the best way of saving an eye with suspected or confirmed endophthalmitis, and it is much more effective than all the other routes.*** Without an intravitreal antibiotic the eye is very likely to become blind. However the injections **must** be given **exactly** the right way and with **exactly** the right amount and concentration. Even when properly given there is a slight risk of toxicity or damage to the eye, and so they should only be given if there is little doubt that the eye is infected.

At the same time as the injection is given, there is an opportunity to remove a very small sample of vitreous for Gram stain and culture to try to identify the bacteria. It usually takes 48 hours to get a result but the injection can be repeated then, and there may then be some bacteriological information to help decide which antibiotic to give if a second injection is necessary.

#### *Choice of antibiotics.*

It is usual to give **both** an antibiotic which is effective against Gram positive bacteria **and** an antibiotic which is effective against Gram negative bacteria. Choosing which antibiotics to give may be difficult, and will also depend on what is available locally.

**Vancomycin** is thought to be the best choice for Gram positive infections. (Teicoplanin or the earlier cephalosporin antibiotics such as Cephazolin or Cefuroxime are alternatives.)

The choice for Gram negative infections is a little more complicated. Until recently the aminoglycoside antibiotics Gentamicin or Amikacin were thought to be the best. However there have been several reports that Gentamicin can be toxic to the retina, and possibly this is true of Amikacin as well. If available, the newer cephalosporin Cefazidime has a good spectrum of action against Gram negative

bacteria. Therefore the choice at present is either **Amikacin** or **Ceftazidime**, but if neither are available, Gentamicin.

### *Preparation of the injection*

Note that the volume of each injection is 0.1 ml and the antibiotic must be diluted with preservative free normal saline. If possible the dried antibiotic powder or solution should be free of preservative as well. The solution is prepared so that 10 times the amount to be given is dissolved in a one ml syringe. 0.9 ml of this is discarded, leaving just 0.1 ml to be injected.

Here are some examples of how to prepare the injections:

**Vancomycin** (or *Cefuroxime* or *Cephazolin* if *Vancomycin* is not available) – Dose 1.0 mg in 0.1 ml. Therefore 10 mg must be prepared in one ml and 9/10 of it discarded.

1. Reconstitute a 500 mg vial with 8 ml of normal saline.
2. Withdraw entire contents and make up to 10 ml with normal saline = 50 mg/ml.
3. Inject 1 ml back into vial and add 4 ml of normal saline = 10 mg/ml.
4. 0.1 ml of this solution = 1.0 mg.

**Amikacin** – Dose: 0.4 mg in 0.1 ml Therefore 4 mg must be prepared in one ml and 9/10 of it discarded.

1. Take 2.0 ml from a vial of amikacin at 250 mg/ml (contains sodium citrate and bisulphite).
2. Make up to 10 ml with normal saline = 50 mg/ml.
3. Discard 9 ml and make up remaining 1 ml to 12.5 ml with normal saline = 4 mg/ml.
4. 0.1 ml of this solution = 0.4 mg.

**Ceftazidime** – Dose 2.0 mg in 0.1ml. Therefore 20 mg must be prepared in one ml and 9/10 of it discarded.

1. Reconstitute a 500 mg vial with 10 ml of saline (beware some vials may contain 250 mg or some 1.0 gm) to make 50 mg /ml and then withdraw entire contents of the vial.
2. Inject 2 ml back into the vial and add 3 ml of normal saline = 20 mg/ml.
3. 0.1 ml of this solution = 2 mg.

**Gentamicin** – (Only give gentamicin if amikacin and ceftazidime are unavailable.) Dose 0.1mg in 0.1ml. Therefore 1.0 mg must be prepared in 1.0 ml and 9/10 discarded.

1. Take 0.5ml from an vial of gentamicin containing 40mg/ml = 20 mg.
2. Make up to 20 ml with normal saline in a syringe = 1.0 mg/ml.
3. 0.1ml of this solution = 0.1mg.

The two injections should be given through the same needle using different syringes.

### *Technique of Intravitreal Injection*

The smallest and the sharpest needle available should be used. It should be inserted directly into the centre of the vitreous through the pars plana, 4 mm posterior to the limbus in the infero-temporal quadrant. The needle is inserted up to 1 cm into the eye. Alternatively after intracapsular extraction, the needle can be inserted directly through the incision. With these very small amounts for injection, try to avoid having any air making a “dead space” in the base of the needle. It may help to have the bevel of the needle pointing forward, and to inject slowly so that the antibiotics aren’t pushed back on to the retina. A small swab soaked in topical anaesthetic drops will help to anaesthetise the area, and a subconjunctival injection of local anaesthetic will also help. Even then the injection will be somewhat painful. Intravitreal injections can be repeated after 48 hours.

### *Identifying the organism*

In acute cases the priority is to get some antibiotics into the eye and not worry too much about identifying the organism. So the first injection will be given without knowing the cause of the infection.

If a reliable bacteriological service is available, a Gram stain or culture may be very helpful for chronic cases or cases which have not responded to treatment. The laboratory must be used to handling tiny specimens from the eye. However it needs a good microbiologist to grow bacteria from the very small sample that is available, and in most cases the services of a skilled microbiologist will not be available.

If a vitrectomy kit is available a tiny amount of vitreous can be obtained before giving the injection. Some surgeons try to aspirate a tiny bit of vitreous just by using the same needle to inject the antibiotic. It is probably best not to use a needle to obtain a vitreous sample because it can cause traction on the vitreous. Alternatively there may be some pus from the wound to examine and culture.

*It is best for a hospital to be prepared, so that some vials of antibiotic powder are always available with detailed instructions of how to dilute the solution so that the right amount is given.* Patients with endophthalmitis have a habit of arriving in the evening or at weekends when nobody is prepared, the antibiotics cannot be found and the correct dose is not known.

***Postoperative infection is an emergency. Prompt and effective treatment can save the eye, but delay of even a few hours or ineffective treatment may result in blindness.***

## **2. Systemic**

Systemic antibiotics should also be given, but they are not nearly as effective as intravitreal. They should be started by injection and then by mouth. Ciprofloxacin and the Cephalosporins have good tissue penetration and a good spectrum of activity. Ampicillin and Flucloxacillin combined are a good alternative.

## **3. Topical**

Topical antibiotics probably help a little but are not really effective for infections inside the eye. Chloramphenicol drops have a good spectrum and penetrate a little

into the eye. Alternatively a combination of Gentamicin and a Cephalosporin can be given. Gentamicin has a good range of action against Gram negative organisms and the Cephalosporins such as Cephazolin or Cefuroxime have a good range of action against Gram positive organisms. Topical drops should be given every hour.

#### **4. Sub-conjunctival Injection**

This produces good levels of antibiotic in the anterior chamber, but is less effective for the vitreous. It is recommended as the best alternative if an intravitreal injection cannot be given. Gentamicin together with a Cephalosporin again make a good broad spectrum combination and are probably the treatment of choice.

The table below shows the doses of subconjunctival antibiotics as well as other drugs which can be given subconjunctivally.

#### **Sub-conjunctival Injections**

##### *Antibiotics*

These are usually made up to 0.5 ml with water for injection. A small injection of lignocaine should first be given if the injection is painful. Antibiotics which are particularly painful by subconjunctival injection are indicated with an asterisk.

Ampicillin	125–250 mg
Benzylpenicillin*	500,000 units with 0.5 ml lignocaine
Carbenicillin	100 mg
Cefuroxime	100 mg
Cephazolin	125 mg
Chloramphenicol*	100 mg with 0.5 ml lignocaine
Cloxacillin	100 mg
Gentamicin	20 mg
Methicillin	125–500 mg
Streptomycin*	100–250 mg with 0.5 ml lignocaine
Vancomycin*	25 mg with 0.5 ml lignocaine

##### *Anti-inflammatory*

Betamethasone	2–4 mg
Cortisone	20 mg
Hydrocortisone	20 mg
Depomedrone	20–40 mg

##### *Mydriatic*

Atropine	0.6 mg
----------	--------

##### *Anti-fungal*

Amphotericin*	0.15–0.3 mg with 0.5 ml lignocaine
---------------	------------------------------------

#### *Technique of sub-conjunctival injection*

The injection is fairly easy and if done carefully should not cause excessive pain.

- Anaesthetise the conjunctiva. A small swab should be soaked in a topical anaesthetic drop, and left in the lower fornix for 2–3 minutes.



- The lower lid is then pulled down and a fine needle inserted through the conjunctiva and advanced for 2-3 mm under the conjunctiva.
- The injection is then given slowly. Multiple injections can be given through the same needle with a change of syringe.

### ***Steroids***

As well as antibiotics most people also recommend intensive steroid treatment for acute endophthalmitis. As a general rule steroids should never be used for treating infections, however they are used in the treatment of endophthalmitis. The damage to the eye from an acute infection is caused by bacterial toxins, which produce an inflammatory reaction in the delicate intraocular tissues. Even if the bacteria are all destroyed the inflammation caused by the toxins can still blind the eye. Therefore this inflammation must be suppressed as well as destroying the bacteria with antibiotics. Steroids are usually given as hourly topical drops and most surgeons would give a short course of systemic steroid treatment as well, starting with a high dose (60 mgm of prednisolone daily) and tapering this off very rapidly over the next few days according to response.

### ***Mydriatics***

These should also be given to all cases of endophthalmitis.

### **Acute iridocyclitis**

Sometimes there may be an acute inflammatory reaction in the eye which is not caused by an infection, particularly after extracapsular extraction. Pieces of lens cortex may dissolve in the aqueous and cause iridocyclitis, or alternatively there may be chemical impurities in one of the solutions used to irrigate the eye.

#### ***Signs and symptoms:***

A non-infective iridocyclitis is often very hard to distinguish from endophthalmitis caused by infection. In non-infective iridocyclitis pain is usually less, and the eyelids and conjunctiva are much less inflamed. However there may be many inflammatory cells in the anterior chamber. The pupil is often constricted and irregular. An inflammatory reaction from cortical lens material usually occurs a few days later than acute infective endophthalmitis.

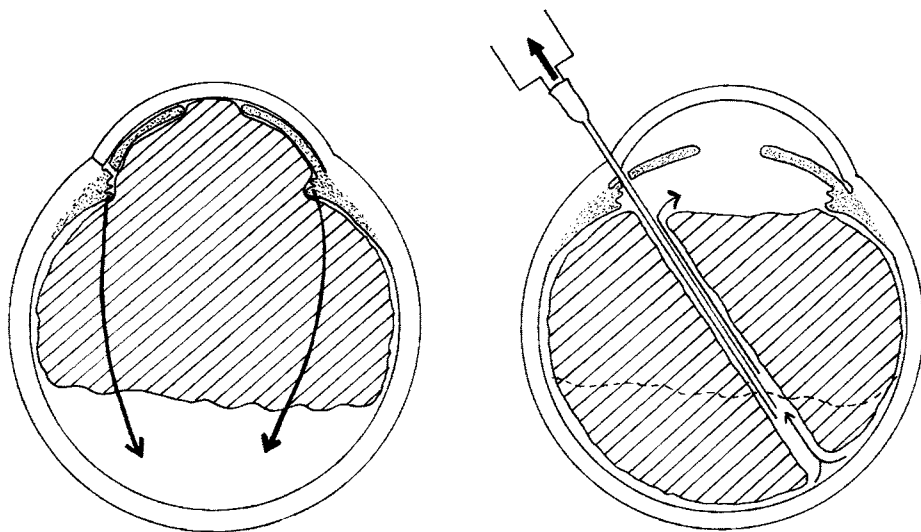
#### ***Treatment:***

The basic treatment is steroids and mydriatics. If there is uncertainty about infection, antibiotics may be given as well. For mild cases topical steroid drops (e.g. Prednisolone drops 2 hourly) are appropriate, more severe cases should be given subconjunctival injections and/or systemic treatment. Mydriatic drops should also be given.

### **Pupil block and malignant glaucoma**

Both of these are fortunately very rare complications, especially malignant glaucoma. They usually develop within a week or two of operation but may come on later. The intraocular pressure rises because the aqueous fails to circulate from the





*Fig. 5.83* Malignant glaucoma. To show how the aqueous passes backwards pushing the vitreous forwards and a diagram of the treatment.

ciliary processes where it is produced, to the trabecular meshwork where it is absorbed. In pupil block glaucoma following intracapsular extraction the anterior face of the vitreous becomes adherent to the pupil, in this way blocking the aqueous circulation. This is the main reason for doing an iridectomy in an intracapsular extraction. For pupil block glaucoma to develop, the iridectomy must have closed off for some reason (see fig. 5.59 and page 139). It may also occur following extracapsular extraction if the pupil adheres to the lens capsule.

In malignant (or ciliary block) glaucoma the aqueous passes backwards into the vitreous, forcing the vitreous forwards against the iris, so that the aqueous cannot reach the anterior chamber (fig. 5.83). The exact mechanism for ciliary block glaucoma is not fully understood.

#### *Signs and symptoms:*

The clinical appearance of both conditions is similar. The cornea is usually hazy. The anterior chamber is very shallow or flat, and the intraocular pressure is very high. However the most common cause for a shallow anterior chamber is a leaking wound, in which the intraocular pressure is low (see table on page 174).

#### *Treatment:*

The patient should be given treatment to lower the intraocular pressure (Acetazolamide tablets or preferably by injection and beta-sympathetic blocking drops) and strong mydriatics to dilate the pupil (Cyclopentolate 1% and Phenylephrine 10% hourly). Mydriatics also cause the ciliary muscle to relax and so may relieve the malignant glaucoma. If the anterior chamber deepens and the intraocular pressure falls, no further treatment is necessary, but if possible the mydriatics should be continued for some months.

If there is no improvement urgent surgery is needed. The aim of surgery is to restore the normal aqueous circulation. Pupil block should be treated by an iridectomy to make a hole in the iris to by-pass the block. Ideally this is done with a Yag laser but if this is not available a surgical iridectomy should be done. If the anterior chamber still does not deepen, this confirms the cause as malignant (ciliary block) glaucoma.

The recommended treatment for malignant glaucoma is to insert a vitrectomy probe or a wide bore needle through the pars plana (fig. 5.83). (After intracapsular extraction this can be done through the incision and the iridectomy). The needle is passed deep into the eye and a small amount of vitreous is aspirated. This should allow the aqueous to circulate again and cure the malignant glaucoma. Vitrectomy instruments are ideal for this procedure if they are available. Unfortunately these eyes are difficult to treat surgically. It is always very risky to operate on an eye with raised intraocular pressure, and yet it is often impossible to bring the pressure down without an operation. The main complication is a disastrous haemorrhage as the pressure in the eye suddenly falls.

## ***Delayed complications***

### **Retinal detachment**

This is particularly common after vitreous loss or in a myopic patient. It is extremely rare after an uncomplicated extracapsular extraction.

#### *Signs and symptoms:*

There is loss of vision, often spreading like a curtain across the patient's field of vision. On examining the retina with an ophthalmoscope the characteristic changes are seen. Notably the red reflex is grey and the retina appears folded.

#### *Treatment:*

Urgent surgical treatment is required. If treated quickly and correctly the results are good.

With delay in diagnosis or treatment the results of surgery become progressively worse. The surgical treatment of retinal detachment is outside the scope of this book and will not be described.

### **Cystoid macular oedema**

In this condition oedema fluid collects around the macula probably as a result of a protein leak from the surrounding retinal blood vessels. The macula develops cystic changes and the visual acuity falls to around 6/60. It usually develops 1-6 months post operatively and is probably quite common in a mild form which usually recovers. Only a few patients progress to develop permanent central visual loss. The cause of cystoid macular oedema is not known, but it is more common after intracapsular than extracapsular extraction. Vitreous loss and post operative iridocyclitis both increase the risk of cystoid macular oedema. No treatment is

known, but if it can be detected in the early stages a course of systemic steroids for a few weeks may be beneficial, and some surgeons advise a course of acetazolamide.

## Permanent corneal oedema

This is the end-stage of severe striate keratopathy. The endothelial cells of the cornea are very active metabolically and transfer fluid from the cornea to the aqueous. If too many of these are destroyed excess fluid collects in the cornea, which becomes hazy so the patient cannot see properly (see plate 7). Small blisters containing fluid constantly form on the anterior epithelial surface of the cornea. These are known as bullae and when they rupture there is pain and inflammation of the eye. The condition is sometimes called ***bullous keratopathy***.

Bullous keratopathy is a particularly distressing complication of cataract surgery because it is almost always due to poor surgical technique. It has unfortunately become more common with the introduction of intraocular lenses, particularly anterior chamber lenses. An eye with a cataract is blind but painless, but an eye with bullous keratopathy is blind and continually painful as well.

### *Treatment:*

The only treatment that can restore the vision is a full thickness corneal graft, and often the corneal graft fails or rejects after some years. If a graft is not possible the pain will be relieved by bringing down a conjunctival flap to cover the cornea (see page 258). The conjunctiva contains lymphatics which will drain the fluid away and prevent the recurrent blisters and ulcers on the cornea that cause so much discomfort. However this will not restore the vision. Treatment with an excimer laser, a very expensive laser used to correct myopia, can also relieve the pain by limiting the recurrent ulcers that form on the cornea. Multiple needle punctures to the surface of the cornea may also help.

## Thickening of the posterior lens capsule (see plates 12–15)

This only occurs after an extracapsular cataract extraction. With extracapsular extraction becoming more popular, especially with lens implants, this is becoming a more common complication. The thickening of the lens capsule usually develops after one or two years but may happen at any time. It is more common in younger patients than older, but can occur at any age. Some slight thickening occurs after most extracapsular extractions, but only causes significant loss of vision in about 25% of cases. It is more common in young patients. The posterior capsule itself is transparent but there are two ways in which it can thicken and become opaque.

- Fibroblasts may grow on its front surface to make a thin opaque membrane.
- New lens cells may grow and spread on the front surface of the lens capsule so that its surface becomes irregular and scatters the light entering the eye. Very careful removal of all the lens cells at the time of surgery, sometimes called polishing the posterior capsule, will lessen the risk of this happening.
- Often both fibroblasts and new lens cells grow together on the posterior capsule.

### *Signs and symptoms:*

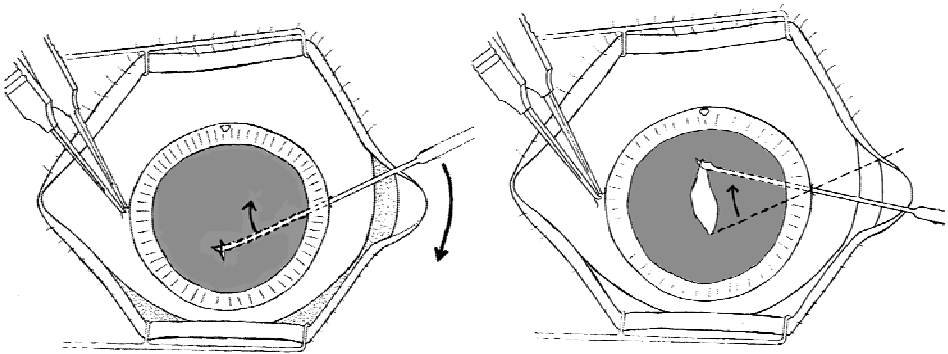
As the capsule opacifies the visual acuity falls. The thickened capsule is best seen by examining the red reflex of the eye through a dilated pupil with an ophthalmoscope using a lens of about + 5 and viewed from approximately 20 cms (see plates 14 and 15).

### *Treatment:*

Slight thickening of the posterior capsule requires no treatment, but if the capsular thickening causes significant blurring of vision a capsulotomy should be performed. If available an Nd:YAG laser is the best way to perform a capsulotomy, it is a painless, safe and simple procedure. Where lasers are not available a surgical capsulotomy should be performed.

### *Method for eyes without an intraocular lens:*

1. Anaesthetic. Usually just topical local anaesthetic drops provide adequate anaesthesia, but for an anxious patient or an inexperienced surgeon a retrobulbar and facial block may be required. A small sponge is soaked in topical anaesthetic and left on the surface of the eye provides better anaesthetic than just a drop.
2. The pupil should be dilated and a speculum used to retract the eye-lids.
3. Steady the eye with fine toothed forceps at the medial limbus. Then make a puncture wound at the lateral limbus with the capsulotomy knife, so as to enter the anterior chamber obliquely to form a self sealing opening.
4. Pierce the capsule and make a short linear cut in it at the centre of the pupil. This is done by moving the handle of the capsulotomy knife and using the entry point at the limbus as the fulcrum of a lever (fig. 5.84). Only a relatively small hole in the capsule is necessary and with skill the aqueous should not drain out of the eye. If the capsule is very thick it may be necessary to make a cross shaped incision with one horizontal and one vertical cut. If during the capsulotomy the anterior chamber does drain away it will reform very quickly and usually no stitches are necessary to close the tiny puncture wound.



*Fig. 5.84* Posterior capsulotomy

5. If a capsulotomy knife is not available the capsulotomy can be performed with an irrigating cystitome. First make a small incision at the limbus using a scalpel or razor blade fragment, but not the full depth of the cornea. Then introduce into the anterior chamber an irrigating cystitome mounted on a syringe full of balanced salt solution or normal saline. If this is pushed through the groove of the incision it will make a self sealing wound. Use the tip of the cystitome to pierce the capsule whilst the anterior chamber is maintained by irrigation. If the wound does leak, a single suture may be required to close it.
6. Very rarely the capsule is a very thick fibrous membrane. This may occur following a penetrating injury to the eye or a badly performed extracapsular extraction. In these cases the pupil is often constricted and adherent to the capsule. Very thick capsule remnants may require more extensive surgery. After a full local anaesthetic block a small incision is made in the limbus. Intraocular scissors are passed into the eye and used to cut a hole in the capsule, and sometimes to free synechiae. Visco-elastic fluids are very helpful in these cases. A full iridectomy may also be necessary.

#### *Method for eyes with an intraocular lens:*

If the eye contains an intraocular lens, changes in the technique may be needed. If the pupil is well dilated, it may be possible to perform the capsulotomy through the limbus by passing the cystitome or the capsulotomy knife behind the optic of the lens and in front of the capsule. Because it is curved and not straight, a cystitome is easier than a capsulotomy knife to manoeuvre between the IOL and the capsule. When the tip has reached the centre of the capsule, it can be rotated so that the tip points backwards and makes a small cut in the centre of the capsule.

Very often a limbal approach and cutting the capsule from in front will not be possible because of adhesions between the lens and the capsule, or the pupil will not dilate enough. In such cases it is better to perform the capsulotomy through the pars plana, and cut the capsule from its posterior surface rather than its anterior surface. For a pars plana incision, a small injection of local anaesthetic subconjunctivally is helpful. The entry point is 4 mm behind the limbus. It is best to insert the capsulotomy knife in the infero temporal or superotemporal quadrant. (at 1.30 , 4.30 , 7.30 or 10.30 o'clock positions). This avoids the anterior ciliary vessels which enter the eye near the lateral rectus muscles.

#### *Preventing posterior capsular thickening:*

The risk of capsular thickening postoperatively is lessened by a careful removal of all the cortical lens fibres at the time of cataract extraction. Another possible way is to make a *primary posterior capsulotomy* at the time of the cataract extraction. Most people do not recommend this , but if a patient has cataract extractions in both eyes and lives far from medical care, it may be a useful technique:-

At the end of the cataract extraction, when the IOL is in place and the wound sutured, the irrigating cystitome can be inserted between two of the sutures and then gently advanced behind the IOL and in front of the posterior capsule. It is then rotated so the tip points backwards into the posterior capsule, and a small tear made in the centre of the posterior capsule. If this is done in one eye, it means that the patient will not get posterior capsular thickening in both eyes.

A primary posterior capsulotomy may also be helpful if during the extraction there is a posterior capsular opacity which will not “rub off” during irrigation and aspiration, and YAG lasers are not available.

## **Glaucoma**

A few patients develop chronic glaucoma after cataract surgery. The usual reason for this is the delayed effect of a leaking wound. The mechanism is as follows:-

The leaking wound post operatively causes a delayed reformation of the anterior chamber. This causes much of the periphery or base of the iris to adhere to the periphery of the cornea, thus closing off the trabecular meshwork. These adhesions are called peripheral anterior synechiae. The leaking wound eventually seals itself and the anterior chamber reforms, but the aqueous is prevented from reaching the trabecular meshwork because of these adhesions, and chronic glaucoma develops.

If the eye is blind no treatment is possible. If there is still useful sight the treatment is the same as that for chronic glaucoma, a trabeculectomy operation. Unfortunately the results of trabeculectomy are rather uncertain in a patient who has had a previous cataract extraction, particularly an intracapsular extraction.

### **MANAGEMENT OF A FLAT ANTERIOR CHAMBER**

Cause	Symptoms and Signs	Treatment	
		Medical	Surgical
Excess aqueous leakage (common)	Painless. Intraocular pressure low or normal. Seidel's test positive	Mydriatics and a pressure pad.	Find and close the leak and reform the anterior chamber.
Pupil block glaucoma (rare)	Painful. Intraocular pressure raised. Hazy cornea.	Intensive mydriatics and acetazolamide.	Iridectomy
Malignant glaucoma (very rare)			Vitreotomy or vitreous needling

## **Chronic postoperative uveitis**

There is the possibility that the eye might become infected with an organism of low virulence during cataract surgery. This is a very rare occurrence, but if it does happen it is almost always following an extracapsular extraction with an IOL. The organism is usually a bacteria called *Propionobacter* which lives quite harmlessly on the skin (known as a commensal bacteria), but in the eye it can cause chronic slight inflammation. The bacteria get in the folds of the posterior capsule or between the capsule and the IOL, where the defence systems of the body cannot

reach them. The eye shows all the signs of chronic uveitis, but on careful examination, there may be little patches of inflammation on the posterior capsule or behind the IOL. If the eye does not respond to conventional treatment for uveitis, the IOL and the posterior capsule may have to be removed in order to get the inflammation to subside.

## **A Check List for Post-operative Eye Examination**

<i>Symptom or sign</i>	<i>Probable causes</i>
<i>Pain</i>	Endophthalmitis Pupil block glaucoma Iridocyclitis Irritation from the sutures Epithelial corneal ulcer
<i>Eyelid swelling</i>	Endophthalmitis Retrobulbar haemorrhage from the L.A. block Eyelid haemorrhage from the facial block Allergy to topical medication
<i>Conjunctival vasodilation and oedema (chemosis)</i>	Endophthalmitis Allergy to topical medication Non-specific reaction to surgery or to retrobulbar local anaesthetic block
<i>Sub-conjunctival haemorrhage</i>	Surgical trauma Retrobulbar haemorrhage from L.A. block
<i>Corneal haze</i>	Striate keratopathy Endophthalmitis Raised intraocular pressure
<i>Anterior chamber shallow or absent</i>	Leaking wound Pupil block glaucoma
<i>Anterior chamber turbid or cloudy</i>	Hyphaema Iridocyclitis Lens fragments following extra-capsular extraction Endophthalmitis
<i>Pupil irregular</i>	Iridocyclitis Iris prolapse or iris incarcerated in the wound

## Secondary Intraocular Lens Implantation

As IOL's are becoming increasingly more popular and the standard method of cataract treatment in less developed countries, patients are often coming having had a previous cataract extraction without an implant and asking for a lens to be implanted in that eye. Another common experience is a patient who has had cataract extraction without an implant in one eye and has developed a cataract in the second eye. The best treatment is usually to remove the cataract and insert an IOL, and also insert an IOL in the other aphakic eye.

There are three possible places for a secondary IOLI:

- In the posterior chamber
- In the anterior chamber
- Fixed to the sclera

### *Secondary Intraocular Lens Implant in the Posterior Chamber*

If the posterior capsule is intact, a posterior chamber IOL can be placed in the ciliary sulcus (see fig. 5.7). This is the best place for a secondary lens implant. The technique for secondary implant of posterior chamber lenses is as follows:

1. Dilate the pupil fully.
2. Choose an IOL which has a large haptic and a large optic (6.5 or 7 mm). This is because the lens will be resting in the ciliary sulcus and not in the capsular bag.
3. Make an incision just large enough to insert the lens. Add viscoelastic fluid or air to the anterior chamber and insert the IOL in the standard way (see pages 116–9). Close the wound and wash out the viscoelastic fluid or air, or any other debris released by the operation, before final wound closure
4. The post operative care is the same as for a cataract extraction with a posterior chamber lens implant.

There are certain possible problems which may need special attention.

- A hole in the posterior capsule
- Adhesions between the iris and the posterior capsule
- A thickened posterior capsule with growth of new lens fibres (Elschnigg's pearls)
- A thickened posterior capsule with fibrosis of the capsule

There may be a hole in the centre of the posterior capsule following a previous capsulotomy but as long as the peripheral part of the capsule is present and the suspensory ligament of the lens is intact, a posterior chamber IOL can be inserted. However, if the vitreous has come through the hole in the posterior chamber and a



slit lamp examination shows some vitreous in the anterior chamber, all the vitreous should first be removed from the anterior chamber with a vitrectomy machine. If this is not available, it is possible to perform a “sponge and scissors” vitrectomy (see pages 114–5) but this is very much a second best option and may not clear all the vitreous from the anterior chamber. A viscoelastic injection into the anterior chamber as soon as the incision enters the anterior chamber may help to keep any vitreous away from the wound edges.

There may be adhesions between the iris and the capsule. These are best divided by injecting viscoelastic fluid between the iris and the capsule and using the pressure of the injected fluid to separate the two layers. It may be necessary to use capsular scissors to separate very firm adhesions between the iris and the capsule but this may make a hole in the posterior capsule. If the adhesions cannot easily be separated, it may be possible to insert the IOL and place the haptics so as to avoid the adhesions. If there are many adhesions, it may not be possible to insert a posterior chamber IOL at all.

New lens fibres, known as Elsnigg’s pearls, may have grown on the posterior capsule and in that case, inserting the secondary IOL is a very good opportunity to remove these new fibres using the Simcoe two-way cannula, or using a small cannula with a specially roughened tip known as a capsule polisher.

The posterior capsule may be thickened with fibrous tissue which cannot easily be irrigated away or polished. In that case, a small central capsulotomy should be made, either with capsular scissors, a capsulotomy knife or the tip of a cystitome. It is easiest to make this before inserting the IOL but the anterior chamber should be full of visco-elastic fluid to prevent any vitreous coming forward into the anterior chamber when the hole in the posterior capsule is made. If the surgeon has access to a YAG laser, then it is best to do a YAG laser capsulotomy during the post operative period rather than a capsulotomy during the operation.

### ***Secondary Intraocular Lens Implant in the Anterior Chamber***

In most cases, the previous operation will have been an intracapsular extraction and therefore a posterior chamber lens cannot be inserted. In these cases, an anterior chamber IOL is the easiest choice but there are certain precautions to observe.

- All anterior chamber IOL’s may gradually damage the vital corneal endothelial cells so that over the course of years they become reduced in number. This risks causing bullous keratopathy, a very serious complication. Therefore anterior chamber IOL’s should never be used on patients under 50 and only with great caution in patients under 60.
- If there are adhesions between the iris and the peripheral cornea (peripheral anterior synechiae), or if a full iridectomy has been performed, then it is very difficult to insert a secondary anterior chamber IOL.
- There may very often be vitreous present in the anterior chamber which needs careful and appropriate management.

The method for secondary IOL insertion in the anterior chamber is as follows:

1. Always constrict the pupil with pilocarpine.
2. Make a limbal incision just large enough to insert the anterior chamber IOL and as soon as the anterior chamber is entered, insert viscoelastic fluid or air to keep the vitreous face behind the pupil.
3. If vitreous was present in the anterior chamber pre-operatively, then ideally an anterior vitrectomy should be performed, or failing that a “sponge and scissors” vitrectomy.
4. Choose an anterior chamber IOL of the correct power and correct size (horizontal corneal diameter white-to-white plus 1 mm).
5. With a constricted pupil and a deep anterior chamber, a lens glide is not usually needed to insert an anterior chamber IOL but it may be helpful in difficult cases
6. The lens is inserted as described on page 153–4. Make sure the pupil is round and not distorted. A distorted pupil means that one of the haptics has caught on the peripheral iris and is not properly placed in the angle. It may be possible to adjust it with a fine cannula.
7. Make sure that there is a patent peripheral iridectomy because the posterior surface of the lens can cause pupil block against the pupil.
8. The wound is closed and air and viscoelastic fluid carefully washed out of the anterior chamber. Take care not to engage the vitreous when doing this and maintain a deep anterior chamber at all times.
9. The post operative care is routine and the pupil can safely be dilated after the intraocular lens is in place.

### ***Sclerally Fixated IOL's***

If the eye is aphakic and an anterior chamber lens contraindicated, either because the patient is young or because it cannot be inserted, then a sclerally fixated lens is the only option (see fig. 5.9). The operation is more difficult, takes longer and needs some special equipment but the long term results are better than with anterior chamber IOL's. In particular, the lenses will not cause any long term damage to the endothelial cells of the cornea.

There are several different ways of inserting and securing the lens but the most common method is as follows:

1. After opening up a small conjunctival flap, make two small half-thickness triangular flaps in the sclera. These should be over the pars plana, 3–4 mm from the limbus and usually in the upper nasal and lower temporal quadrants of the eye (fig. 5.85). The pupil should be dilated.
2. Make a 7 mm limbal incision to insert the IOL later.
3. Using a vitrectomy machine, through the limbal incision remove all vitreous

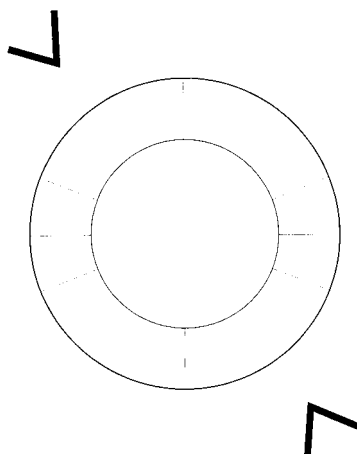


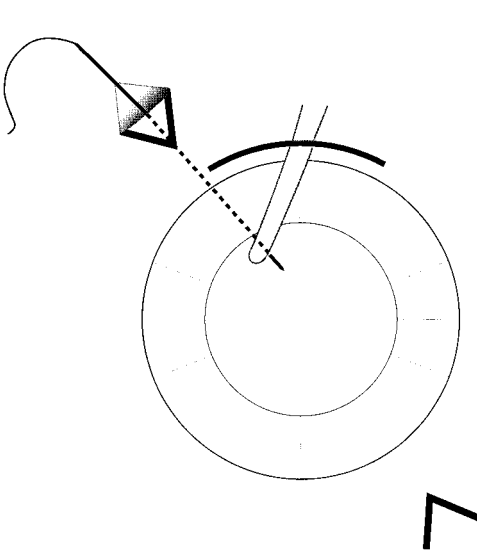
Fig. 5.85 To show the position of the two small half-thickness scleral pockets

from the anterior chamber and also from just behind the pupil. A vitrectomy machine is essential to do this. "Sponge and scissors" vitrectomy is not really good enough.

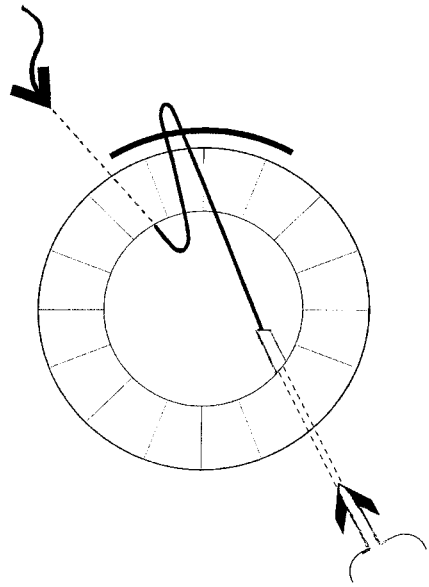
4. A 10"0" polypropylene or polyester suture is now passed from one scleral pocket to the other across the centre of the eye. *This suture must not be nylon as nylon will degrade inside the eye and after a few months, the suture will break.* There are various ways of passing this stitch across the eye but the following method is probably the easiest.
5. The suture is mounted on a long, thin, straight needle. The needle is inserted through the upper scleral pocket and when the tip is seen at the pupil margin, it is grasped with forceps placed through the wound and pulled out of the eye (fig. 5.86).
6. A small hypodermic needle is now inserted through the lower scleral pocket so the tip of the hypodermic needle is just visible in the pupil margin. The straight needle is then reinserted through the wound and its tip inserted into the tip of the hypodermic needle (fig. 5.87). The hypodermic needle is then carefully removed from the eye so that the tip of the straight needle comes out through the lower scleral pocket. In this way, the 10"0" suture has been passed right across the eye and is also looped out through the incision.

It is possible to combine steps 5 and 6 and pass the needle straight across the eye from one scleral pocket to the other. Alternatively, after step 5, the thread can be cut and the needle inserted through the lower scleral pocket from outside the eye to inside just as in fig. 5.86.


7. The next step is to cut the loop of the suture and tie each end to the haptic of a posterior chamber lens, which is placed on the surface of the cornea. Ideally a special lens with loops on the haptic is used but if this is not available, the tip of



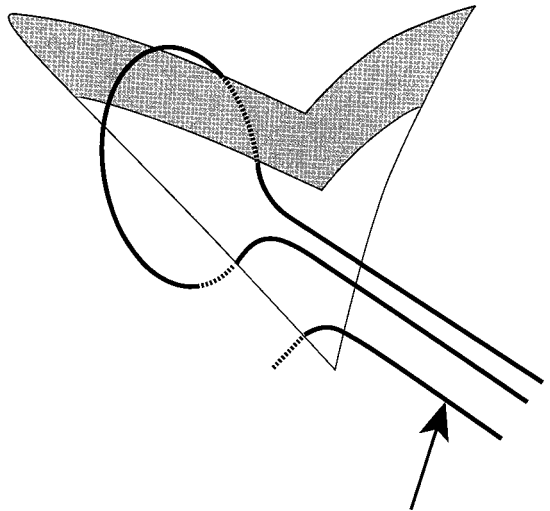
*Fig. 5.86* Figure 5.86 Inserting the polyester or polypropylene suture on a straight needle



*Fig. 5.87* Completing the insertion of the suture across the eye.



*Fig. 5.88* Securing the two suture ends to the intraocular lens lying on the surface of the eye.



*Fig. 5.89* A method of burying the knot. Tie all three suture ends together to leave a knot buried inside the sclera.

the haptic can be heated with a cautery point to make it into a small lump so that the suture will not slip off the end of the haptic (fig. 5.88).

8. Once the suture has been tied to the end of each haptic, the two suture ends are pulled tight whilst the lens is gently manoeuvred through the wound, through the pupil, to lie behind the iris with the two haptics tied to the two suture ends.
9. The last stage is to secure these two suture ends to the sclera and also to make sure that the knot is buried in the sclera and not on the surface of the sclera where it will irritate and become infected, and cause infection to enter the eye. The way to do this is as follows (see fig. 5.89):
  - First tie a 10“0” polyester or polypropylene suture to close the superficial scleral flap, making sure that the stitch begins and ends inside the wound so that the knot is buried.
  - Then tie this knot to the 10“0” polyester or polypropylene suture which is attached to the sclerally fixated IOL (indicated by the black arrow in fig. 5.89). In this way, the entire knot is buried inside the sclera.
  - Finally, close the limbal incision and apply routine post operative care.

## For further information

It is possible to obtain teaching videos of cataract surgery which are in many ways a better way of learning than from a book. The following can be recommended:-

Intracapsular cataract extraction and anterior chamber lens implant, and extracapsular cataract extraction and posterior chamber lens implant for developing countries. These are both available from the Christian Blind Mission International, Nibelungstrasse 124, D6140 Bensheim, Germany or the resource centre at International Centre for Eye Health.

“Extracapsular cataract extraction and intraocular lens implant for developing countries” by John Sandford-Smith from The Resource Centre International Centre for Eye Health, The London School of Tropical Medicine and Hygiene, 11 Keppel St., London, WC1E 7HT, U.K.

*Small incision cataract surgery videos:-*

A video from Aravind Hospital (1 Anna Nagar, Madurai, 625020 India) shows the technique using a loop described here.

The Henig technique video is available from The Christian Blind Mission International (Nibelungstrasse 124, D6140 Bensheim, Germany). or the International Centre for Eye Health.

The Blumenthal method video is called “small incision cataract surgery – mini nuc” – and is available from “Visitec” (7575 Commerce Court, Saratoga, Florida U.S.A. 34243–3212).