

CHAPTER 2

SURGERY AND THE EYE

This chapter is about basic surgical principles and techniques, and how a delicate and specialised organ like the eye reacts to surgery. It is obvious that a surgeon must know all this in detail. However nurses and theatre assistants looking after eye patients should understand these basic principles.

Basic Surgical Principles

There are three areas of knowledge and experience required to practise any kind of surgery. These are listed below:-

1. *Knowledge of basic sciences*

- *Anatomy.* This describes the structure of the body.
- *Physiology.* This describes the function of the body.
- *Pathology.* This describes diseases that affect the body, and how they alter the structure and function.

2. *Knowledge of surgical techniques*

- Sterility and prevention of infection.
- Handling instruments
- Basic surgical method.
- Haemostasis.
- Wound closure and sutures.

3. *Practical surgical skills*

Surgery on a small and delicate organ such as the eye is obviously different from other types of surgery. There are therefore several other vitally important principles specific to eye surgery. These will be discussed later in the chapter.

1. Knowledge of basic sciences

It is not possible in this book to provide all the necessary details of the anatomy, physiology and pathology of the eye. However, important points will be mentioned in the text.

Anatomy

It is essential for a surgeon (and any one involved in surgical care) to be familiar with the detailed anatomy of the region where he is operating, in particular its blood and nerve supply.

Physiology

The surgeon must know how each tissue and structure works when it is healthy. He should also know how the tissues react to surgical injury and what effect the operation will have upon the function of the tissues.

Pathology

The surgeon must know the causes of disease and the effects each disease will have in altering both the anatomy and the physiology of the diseased structures.

2. Knowledge of surgical technique

Eye surgeons should understand the basic science and technical skills of surgery. These include:

1. *Sterile technique.* This is essential in order to limit the risks of bacterial contamination and to prevent subsequent infection.
2. *Correct handling of surgical instruments.* It is important that the surgeon knows the exact purpose for which each instrument was designed and how to use it correctly. This ensures that tissues are grasped, cut, divided and retracted properly. Also the working life of instruments is extended by using them properly.
3. *Basic surgical method.* The surgeon should have a methodical approach, completing each step of the operation before progressing to the next. He must ensure good exposure and haemostasis at each stage. In this way the surgeon can see what he is doing and knows the exact structure he is touching. Complications frequently occur because inadequate attention has been paid to these details.
4. *Haemostasis* (See also p.26). Bleeding obscures the surgical field and makes an operation difficult. Blood may collect post-operatively and result in haematoma formation which delays wound healing and encourages infection. The surgeon should know how and where to place incisions so as to minimise bleeding and also how to manage bleeding. This can be controlled by compression, artery forceps and ligature, cautery or diathermy.

Compression or pressure effectively stops bleeding. Venous bleeding requires only gentle pressure, arterial bleeding requires firm pressure. If the pressure is maintained for a few minutes the cut blood vessels will constrict and the bleeding will lessen. Blood may also clot in the vessel. It is not sensible to rely on pressure alone to control bleeding from large vessels, because the blood vessel may well stop constricting, or the clot may give way and so cause post-operative haemorrhage.

Artery forceps and ligature should be used to secure medium or large blood vessels. However compression for three to four minutes is a helpful way of lessening blood loss from a large vessel so that it can then be more easily identified and clamped.

Surgical diathermy if available is the best way of stopping bleeding from small blood vessels, or bleeding from the surface of the eye. However, if diathermy is not available pressure or applying artery forceps for a few minutes without ligature is usually effective for small blood vessels.

Cautery is used mainly on the surface of the sclera. However it is not very effective in soft tissues. Both diathermy and cautery should not be used excessively on the surface of the eye, or they will cause burning and tissue destruction followed by excessive scarring. Minimal diathermy or cautery is all that is needed to seal off the small blood vessels.

5. *Wound closure and sutures.* It is essential to close wounds securely by bringing together each layer of tissue in the correct plane and without undue tension. It is most important to suture each layer to itself, epithelium to epithelium, fascia to fascia, skin to skin and so on. Good bites of the tissues are taken by rotating the needle holder along the curve of the needle. Care must be taken not to overlap edges nor to tie the sutures too tight which may cause death of the intervening tissues (necrosis) and poor healing.

The surgeon should be able to tie surgical knots using instruments and not fingers. Although the suture itself should not be tight, the knot must be tight and tied correctly to prevent it slipping or coming undone. A working knowledge of the different suture materials and an understanding of how they behave in the body will allow him to make an appropriate choice. Sutures for extraocular surgery are usually 4“0” to 6“0” gauge, sutures for intraocular surgery are usually finer (see page 30).

There are two types of suture, absorbable and non-absorbable.

Absorbable sutures have traditionally been made of “catgut” or collagen and dissolve after about 4 weeks. They are used for suturing deeper structures. Synthetic absorbable sutures such as polyglactin (vicryl) is stronger than catgut and therefore finer gauges (5“0” or 6“0”) can be used. They also cause less tissue reaction than catgut. Absorbable sutures can be used for skin closure if the patient cannot easily return to have the sutures removed or in small children who cannot easily cooperate. However absorbable sutures on the skin may cause some inflammation while they slowly dissolve. Very fine absorbable sutures are the best way of closing the conjunctiva.

Non-absorbable sutures can be made of many different materials: cotton, silk, nylon etc. They are normally used for closing the skin and are removed after 5–10 days. They can however be used to close deeper layers when they will remain buried in the tissues. 4“0” to 6“0” is an appropriate gauge for most extraocular surgery. Monofilament suture material (nylon or polypropylene) has only one strand and is only used for skin closure. It causes less tissue reaction but is harder to handle than braided sutures. Most modern ophthalmic sutures are fused to a needle by the manufacturers. However threaded reusable needles can be used which save money. Needles may be cutting, for skin or tough tissues like the tarsal plate, or round bodied, for muscle and connective tissue. Very fine corneal or scleral needles have a flat lancet point which is a

variation of the cutting needle. All ophthalmic needles are curved. The correct way of tying knots in sutures is described on pages 35 to 36.

3. Practical surgical skills

This is the final stage of learning as an apprentice with a trainer. Much useful advice can be learned from books and also from videos, but surgery is essentially a practical skill and needs to be taught as an apprenticeship training.

Eye surgery may be divided into two distinct categories:- extraocular and intraocular surgery.

Extraocular surgery is performed on the structures surrounding the eye itself such as the eye-lids and the conjunctiva. These tissues have an excellent blood supply. They therefore heal very well and rarely become seriously infected. They are on the surface of the body so surgical exposure is usually not a problem. They can be anaesthetised easily by infiltrating the tissues with local anaesthetic. Adrenaline (called epinephrine in the U.S.A.) (1 in 100,000) is always used in the local anaesthetic to lessen bleeding because these tissues are so vascular. For all these reasons the principles of extraocular surgery are the same as those for general surgery. However the extraocular tissues are rather small and some magnification is usually helpful for the surgeon.

Intraocular surgery is performed on the eye itself. The eye structures as well as being very small are very specialised and delicate. There are therefore several other basic rules or principles for any sort of intraocular surgery. Because it is specialised the eye has only limited powers of recovery from injury including the injury from the surgeon's operation. Other parts of the body will often recover completely from rough handling at operation or from complications like infection. Alternatively it may be possible to do another operation to correct any post-operative complications. Unfortunately this is not true of the eye. Bad surgery or post-operative complications will often lead to permanent loss of sight. It is a sad but true fact that there are some parts of the world where operative and post-operative complications of eye surgery are a significant cause of blindness in the community. Even the best surgeon has complications but with care and correct technique serious complications should be rare.



Fig. 2.1 Telescopic operating glasses

Principles of Intraocular Surgery

1. Magnification and illumination.
2. Prevention of tremor.
3. Prevention of infection.
4. Surgical access.
5. Haemostasis.
6. Protecting the corneal endothelium.
7. Avoiding damage to the lens.
8. Handling the iris.
9. Management of the vitreous.
10. Wound closure.
11. Reducing post-operative inflammation.

1. Magnification and illumination

The eye is small and delicate. It is important that the surgeon has a good clear view of the various fine structures and can see exactly what he is doing and touching. Therefore some magnification and good illumination are essential.

Magnification. This can be achieved in one of three ways:

1. *Simple convex spectacles.* These shorten the focal length of the surgeon's eye and so reduce the working distance. There are obvious disadvantages to this method; the surgeon's head is very close to the patient's eye and the degree of magnification is limited. However these lenses are cheap, robust and simple.
2. *Telescopic operating glasses.* (fig. 2.1) These can be designed to any working distance which the surgeon finds comfortable. The degree of magnification can be varied from $\times 2$ to $\times 5$. To magnify more than $\times 5$ is difficult since small movements of the surgeon's head will make the object appear to move. In addition the field of view reduces with increased magnification. Telescopic operating glasses are generally better than spectacle lenses but are more expensive and require a period of training in order to get used to them. Each model varies slightly and a surgeon will develop a preference for one particular type. In the end choice depends on preference, price and availability.
3. *Operating microscope.* Binocular operating microscopes are now used for nearly all intraocular surgery in developed countries, and this is rapidly becoming standard practise in developing countries also. The magnification and clarity are much greater than with telescopic glasses, and this means that intraocular surgery can be done to a higher standard with a microscope. Indeed for some intraocular operations a microscope is essential.

However, microscopes have some disadvantages. They are relatively expensive even if purchased second-hand. Most are large and difficult to transport although portable microscopes are available (see appendix page 322). If the patient does not lie completely still, the focusing and positioning has to be constantly changed. The training period is longer and many surgeons find that operating with a microscope takes longer.

Illumination. Good illumination is obviously required as well as magnification. Since only a small area needs to be lit the overall power of the light does not have to be great. There are satisfactory lamps available that work on mains electricity or 12 volts DC (see appendix page 322). Correct positioning is important to avoid shadows.

Nearly all modern operating microscopes have a *co-axial illuminating system*. This means that the light travels along the same path as that used to view the eye. It is difficult to achieve this using telescopic operating glasses. However some operating glasses are available with a head mounted light source which can provide rather poor quality coaxial illumination. The advantage of co-axial illumination is that the bright red reflex is seen emerging from the pupil against which details of the lens structure are clearly seen (see colour plates 1 and 2). Whilst this is extremely important when performing modern extracapsular cataract surgery it has little advantage for most other procedures.

2. Prevention of tremor

All surgeons must have steady hands and this is particularly important for eye surgeons. During early training anxiety and nervousness may cause a slight tremor. This should settle as experience and confidence are acquired. If it does not the trainee should be counselled to change to another career.

Some very simple suggestions to avoid tremor:

- Make sure the whole atmosphere in the operating room is calm and relaxed for both staff and patients. Some people find that having quiet background music is helpful.
- Make sure the patient is not restless, that the drapes are not obstructing the airway, and that the local anaesthetic block is satisfactory. The patient needs to be comfortable and not too hot or cold. A restless patient or a poor nerve block creates tension and anxiety in the surgeon. If possible someone should hold the patient's hand which is very reassuring and relaxing.
- The surgeon should obviously avoid alcohol and sometimes even coffee and other stimulants before operating. Try to avoid physical and emotional stress before operating, such as heavy manual work or driving long distances.
- A comfortable position with the operating table and the surgeon's chair at the right height makes a big difference for the surgeon. A bad posture for the surgeon can not only cause tremor but backache and cramps. In particular there must be support for the surgeon's elbows, forearms and wrists. The best way of ensuring this is to have an operating pillow with a deep hole for the

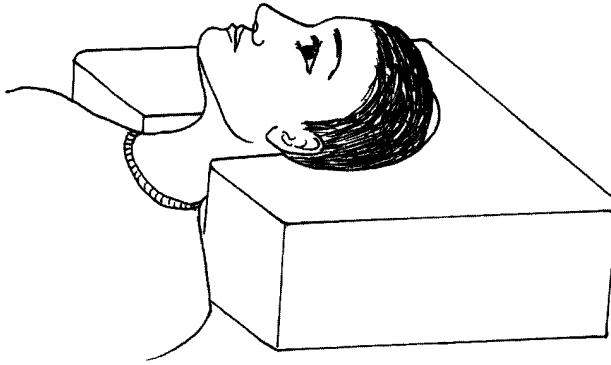


Fig. 2.2 A head pillow for eye surgery

patient's head (fig. 2.2). If it is not available pillows or sandbags beside the patient's head will help support the surgeon's arms.

3. Prevention of infection

A good sterile technique is absolutely essential for intraocular surgery. Post-operative infections elsewhere in the body are a serious complication but in the eye are a total disaster. Pathogenic bacteria multiply with ease inside the eye where they are out of reach of the body's defenses. The delicate intraocular structures are rapidly damaged and even vigorous treatment frequently fails. The result is a partial or total loss of sight. Intraocular infections following surgery are usually the result of poor surgical technique or operating theatre practice. The incidence of this tragic complication should be very low, hopefully less than 1 in 1,000. An incidence higher than this should suggest a break-down of correct procedures which needs to be identified and corrected. Good sterile technique is important for any operation but is absolutely vital for intraocular operations. In particular there are three specific precautions to take:

1. Patients with infection of the conjunctiva, lacrimal sac or eyelids, or with trichiasis must have this treated before intraocular surgery.
2. During surgery a "no touch" technique should be used. Each instrument should be held correctly by its handle. The "working" end that goes into the eye should not touch the surgeon's or the assistant's hand or the patient's skin or eye lashes. After use it should be placed on the instrument table avoiding other instruments. Wet instruments can destroy a "no touch" technique with moisture running down to the working end or contaminating other instruments. A good "no touch" technique is extremely important and must be practised by the assistant and anyone else handling the instruments as well as the surgeon. The routine use of surgical gloves may reduce the risk of infection. Some surgeons think that gloves reduce the delicate sense of touch from instruments. Therefore they do not use them unless performing more major surgery where

significant blood loss is expected or the case is infected. In theory gloves should reduce the risk of a patient transmitting diseases such as Hepatitis B or AIDS to the surgeon. Although it remains important to observe a “no touch” technique, wearing gloves is a sensible precaution both to reduce the risk to the patient of infection and to protect the surgeon.

3. *Irrigating fluids.* When irrigating the eye there is a risk of introducing infection with contaminated fluids. This is more likely if irrigating fluids are taken from a multi-dose container. If possible, use a fresh single dose container or a new infusion bag for each case. Any fluid used to keep the cornea moist must also be sterile. As a general rule never irrigate any fluid inside the eye unless it is essential.

This vital subject of preventing infection is discussed more fully in chapter 3.

4. Surgical access

The eye is a surface structure but the eye-lids must be held open. Although this can be achieved with sutures, a speculum is more often used. A solid speculum (fig. 2.3) is quite heavy and presses a little on the eye. It provides excellent exposure and is used for procedures where there is no risk that the ocular contents will prolapse e.g. pterygium or trabeculectomy. However a trained assistant can adjust the speculum so as to overcome any pressure on the eye (see pages 94 and 113). The wire speculum (fig. 2.4) is lighter but the exposure is not quite so good. It is used where there is a risk of the intraocular contents being pressed out of the eye at the time of surgery e.g. at cataract operations or repairing penetrating injuries. It is also very important to have a good facial nerve block to stop the eye-lids contracting and pressing on the eye.

Canthotomy procedure to enlarge the palpebral fissure (fig. 2.5)

In the normal patient, once the eyelids are held open with a speculum, there is enough space to gain access to the eye. Occasionally a patient may have rather contracted eyelids or a very deep set eye, causing some difficulty in getting good exposure of the eye. In such cases the palpebral fissure can be easily and quickly enlarged with a lateral canthotomy procedure.

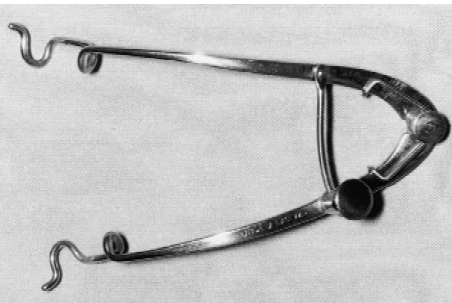


Fig. 2.3 A solid adjustable speculum – this is known as “Lang’s”

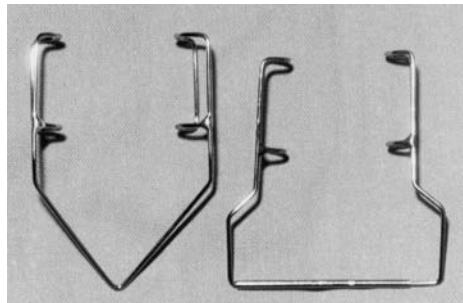
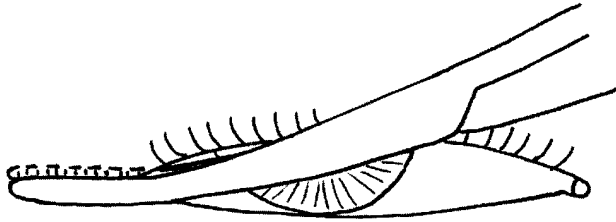



Fig. 2.4 Two types of wire speculum – the right hand one is adjustable and the left hand one is not



(a) Applying the artery forceps to the lateral canthus



(b) Cutting the lateral canthus with scissors

Fig. 2.5 Lateral canthotomy

1. Inject a small amount of local anaesthetic with adrenaline into the lateral canthus.
2. Apply an artery forceps to clamp the lateral canthus for a few seconds to produce haemostasis (fig. 2.5a).
3. Remove the artery forceps and cut with scissors along the line of the tissue clamped by the artery forceps (fig. 2.5b).

It is never necessary to re-suture or repair a lateral canthotomy at the end of the operation.

Superior Rectus stay suture

Most intraocular operations are performed on or near the upper limbus. In order to gain access to this the eye must be rotated downward using a superior rectus stay suture. Insert this as follows:-

1. Place a lens expressor or similar blunt instrument into the lower fornix and press gently to rotate the eye down (fig. 2.6).
2. Grasp the eye through the conjunctiva with toothed forceps 6 mm above the limbus. This is where the superior rectus muscle is inserted into the globe. Check that the forceps have grasped the muscle insertion by moving them downwards and the eye should rotate downwards at the same time. Now pass a 4“0” suture beneath the forceps and through the muscle insertion (fig. 2.7), but obviously it must not be placed too deeply so that it penetrates the sclera. Gentle traction on this suture should rotate the eye downward and expose the limbus.
3. If the suture has not been placed through the muscle the eye will not rotate downwards but the conjunctiva will be tented up instead.

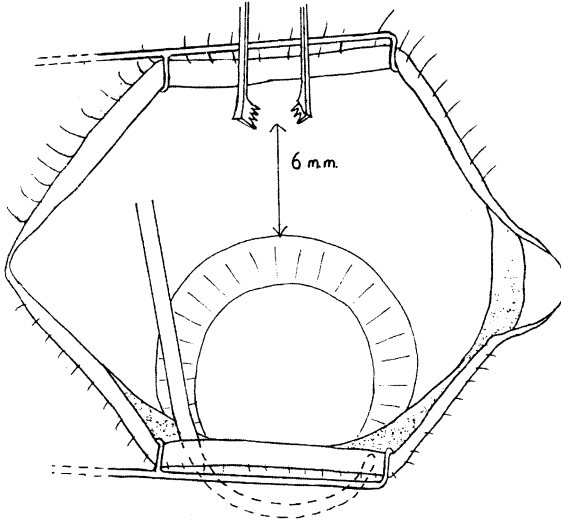


Fig. 2.6 Grasping the superior rectus insertion

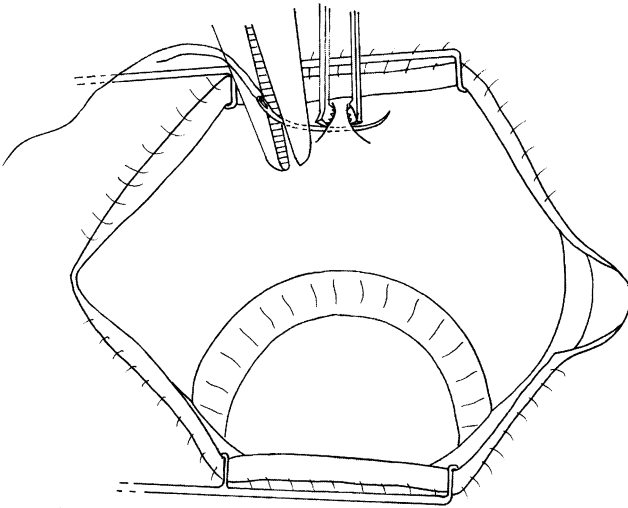


Fig. 2.7 Inserting the superior rectus suture

4. Once correctly positioned the suture is clamped lightly to the drapes to hold the eye rotated downwards. It should not be used to force an eye down when the superior rectus muscle is still contracting.

Where exposure is a problem, an *inferior rectus suture* as well as a superior rectus suture provides even better exposure. The two sutures together will also displace the eye forwards without causing any pressure on it. The inferior rectus suture is inserted in just the same way as the superior rectus suture.

Incisions into the eye

These can be made through the cornea, the sclera or the limbus. The limbus is the zone where the cornea and sclera meet.

The advantage of *corneal incisions* is they do not bleed, and they can be made quickly. However the disadvantages are that they do not heal quickly, and they may cause astigmatism from distortion to the cornea. A badly sutured corneal incision can cause serious astigmatism.

The sutures will cause irritation because they are on the surface of the eye, unless monofilament sutures are used with buried knots. Nearly always corneal sutures will need to be removed later on.

The advantage of *scleral incisions* is that they heal well and the sutures can be buried under the conjunctiva. The disadvantage is that they bleed from the wound surface and edges, and they cannot be made so quickly.

A popular site for incisions is at the *limbus* which avoids the worst complications of both corneal and scleral incisions. The incision may bleed a little from the surface but this can be prevented with cautery. Limbal incisions heal fairly well and the sutures can be buried under the conjunctiva.

The Anatomy of the Limbus

Most incisions into the eye are made in or near the limbus. This is where the transparent cornea joins the opaque sclera. The surgeon must know this part of the anatomy of the eye particularly well, and also to understand exactly what he (or she) sees when looking at the eye.

Fig. 2.8 shows the anatomy of the limbus and fig. 2.9 shows what the surgeon sees. At the limbus there are three different changes taking place.

1. On the surface of the cornea, the *epithelial* layer.
 2. In the substance of the cornea, the *stromal* layer.
 3. On the inside of the cornea, the *endothelial* layer.
- 1. At the surface the corneal epithelium changes to become the conjunctival epithelium. The basement membrane for the corneal epithelium is called Bowman's membrane. It is firmly attached to the cornea so the corneal epithelium cannot be picked up with forceps. Bowman's membrane changes to become the basement membrane of the conjunctiva. This is very loosely attached to the sclera and so the conjunctiva can be picked up with forceps. This takes place at point **A** in fig. 2.8.
 - 2. The stroma of the cornea is transparent and it gradually changes into the opaque white sclera. The cornea is said to be held in the sclera rather like a watch glass inside a watch. This means that the anterior layers of the corneal stroma change to become the sclera at point **A** but the posterior layers of the cornea do not change into sclera until point **B**.
 - 3. On the inside of the cornea there is the corneal endothelium, which rests on Descemet's membrane. This finishes in a distinct line called Schwalbe's line. There is then a space of about 1 mm where the trabecular meshwork drains the

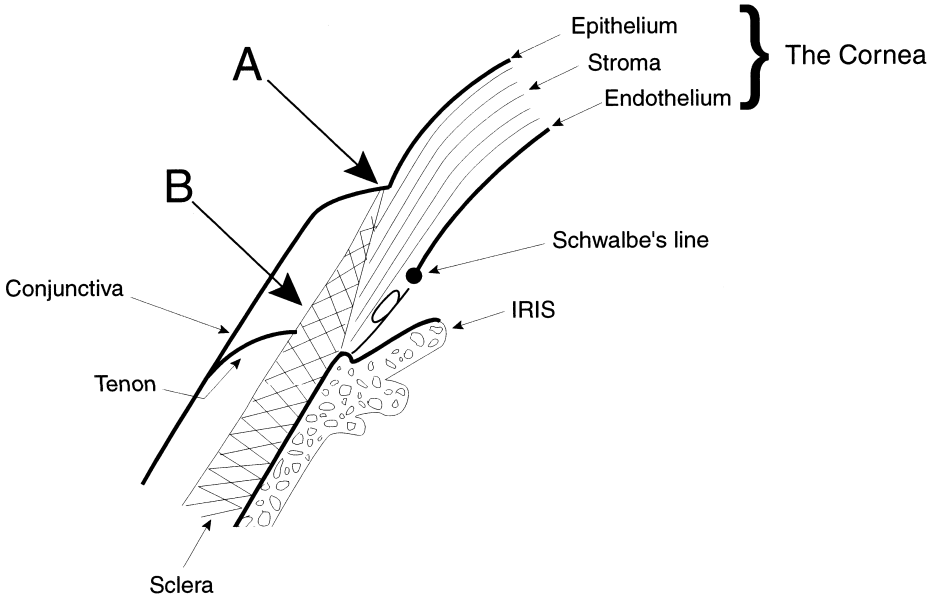


Fig. 2.8 The anatomy of the limbus

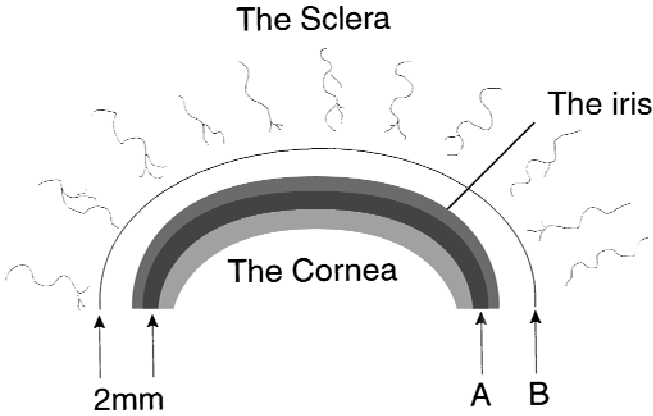


Fig. 2.9 How the surgeon sees the limbus

aqueous out of the eye, and then the base of the iris is attached to the sclera. This is called the scleral spur, and is found in line with point **B** in fig. 2.8.

So the limbus stretches all the way from point **A** to point **B** and this is a distance of about 2 mm. Finally just posterior to point **B** the Tenon's capsule is inserted into the sclera. Tenon's capsule is a thin layer of fascia which joins the conjunctiva to the sclera.

We will now look at the limbus from the viewpoint of the surgeon – fig. 2.9. At one end is the transparent cornea and at the other the opaque sclera. The surgeon

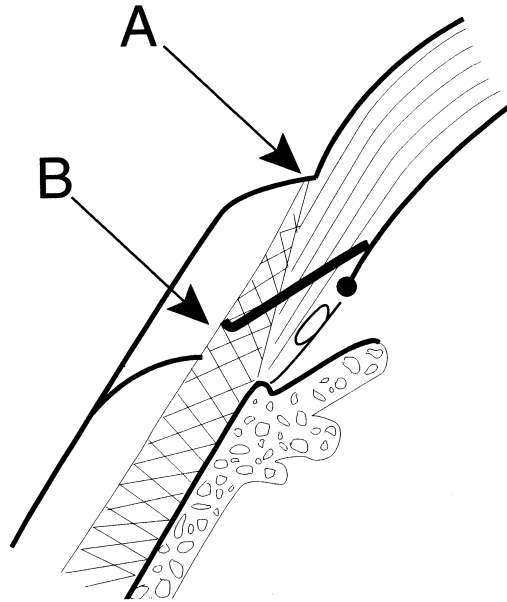


Fig. 2.10 The limbus to show the ideal position for the incision into the eye

can easily identify point **A** where the conjunctiva is attached to the corneal epithelium, and the limbus stretches for 2 mm back from this point. At first there is a blue-grey area about 1 mm thick which gradually becomes completely white like the rest of the sclera. This marks the position of Schwalbe's line, "Where the white meets the blue – Schwalbe's line waits for you!" There is nothing special to identify point **B** where the iris joins the sclera at the scleral spur but it is 2 mm posterior from point **A** which can be identified.

If an incision is planned at the limbus, it should enter the sclera at point **B** where the sutures will be well covered by the conjunctiva, and it should enter the anterior chamber at point **A** where it will be well clear of all the important structures in the angle, and it will not damage the iris. The ideal position for the incision is shown in fig. 2.10.

Dissecting the Conjunctiva

The conjunctiva must be cut and reflected back before surgery either at the limbus or on the sclera. It can be used to cover and protect the wound at the end of the operation. The conjunctival flap can be raised with its base at the fornix (fig. 2.11) or the limbus (fig. 2.12). The fornix based flap is cut along the limbus and undermined upwards. The limbus based flap is raised by cutting the conjunctiva approximately 5 mm above the limbus and reflecting it downwards. Both techniques are satisfactory. Tenon's capsule is a layer of connective tissue which lies between the conjunctiva and the sclera. It is particularly thick and obvious in younger patients, but tends to atrophy in old age. It must be dissected from the eye with the conjunctiva, failure to dissect it properly from the sclera results in poor

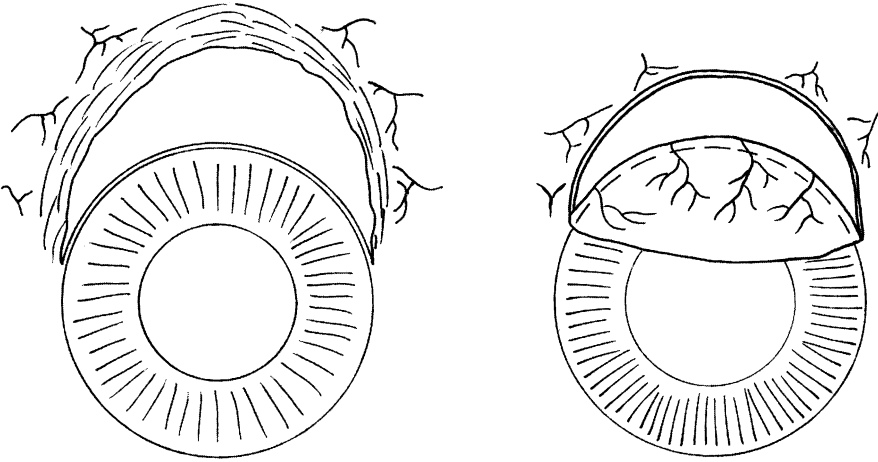


Fig 2.11 A fornix based conjunctival flap Fig. 2.12 A limbus based conjunctival flap

haemostasis and difficulty in placing the incision accurately. Excessive post-operative fibrous reaction in Tenon's capsule has been suggested as a cause of failure after trabeculectomy procedures.

The fornix based flap seems to be becoming increasingly popular nowadays because:-

- It does not cut through any of the conjunctival blood vessels, and so the conjunctiva heals quicker and better.
- Less dissection is needed to bare the limbus where the incision into the eye will be made.
- Tenon's capsule is more easily cleared.
- With a fornix based flap, any cautery to the limbus is less likely to cause burns of the conjunctiva as well.
- The conjunctiva can be secured at the end of the operation with one or at the most two sutures.

5. Haemostasis

Even small quantities of blood obscure the details of the eye and make surgery difficult. Most troublesome bleeding usually occurs from the episcleral blood vessels on the surface of the eye. It is difficult to deal with haemorrhage once it has occurred and so it is best to try to prevent it. This is usually done with very light cautery or diathermy.

The cautery is applied on the surface of the eye along the line where the incision is going to be made. This will be at the limbus for most cataract operations but further back on the sclera for a trabeculectomy operation. For surgery to the sclera try to avoid the penetrating branches of the anterior ciliary arteries or the major veins and plan the incision accordingly.

Types of cautery or diathermy.

- A hot point cautery (see fig. 5.12) can be heated over a small spirit lamp and is very simple and effective. Alternatively an old squint hook or a glass rod may be used.
- A battery cautery is an alternative. (See fig. 3.6K)
- Diathermy works by passing a high frequency low voltage electrical current through the tissues to cause a localised burn. The diathermy terminals remain cool but the tissues through which the current passes become hot. Most diathermy machines are bipolar, the current passes across the two jaws of a pair of forceps. For diathermy on the surface of the eye the two jaws of the forceps must be slightly apart and the surface of the eye must be moist to allow the current to flow through the tissues and heat them.

The most important fact about using the cautery or diathermy is to apply the *minimum heat possible* that just shrinks the superficial blood vessels and blanches them without causing any charring. Excessive use of the cautery will cause necrosis in the sclera. This will prevent the wound from healing and also cause post-operative inflammation. If the cautery is applied to the edge of the incision, the edges will shrink and contract. It may then be difficult to achieve a water-tight wound closure. For this reason, cautery should only be applied very lightly to the surface of the eye *before* any incision has been made to the limbus or sclera. In cataract surgery particular attention should be given to the ends of the incision at 3 o'clock and 9 o'clock. These are often more vascular than the rest of the incision especially if a pterygium is present.

Haemorrhage from the iris is not usually a problem although there may be a small amount of bleeding when an iridectomy is performed. This is really very surprising because the iris is an extremely vascular structure. If the iris does bleed the best treatment is patience. The bleeding will nearly always stop quickly and cautery should never be used on the iris or inside the eye. Blood can be washed out with gentle irrigation to the anterior chamber before it clots. If it has clotted a cellulose sponge will usually adhere to the clot and it can be gently lifted out of the anterior chamber, but this should be done with great care as the clot often adheres to the iris as well.

6. Damage to the corneal endothelium

The corneal endothelium is a single layer of cells lining the inner or posterior surface of the cornea. These cells remove water from the substance (stroma) of the cornea and are very active metabolically, keeping the cornea dehydrated. If they are damaged, the cornea swells as its water content increases, a condition known as corneal oedema. The cornea loses its transparency and becomes hazy and cloudy. The endothelial cells are unable to multiply and are not replaced once injured or destroyed. However neighbouring endothelial cells can hypertrophy and migrate to fill the gap if only a few endothelial cells are damaged.

During any intraocular surgery but particularly cataract surgery some of the endothelial cells may be damaged. Patches of corneal oedema occur post-operatively, and appear as irregular white opaque lines in the deeper parts of the

corneal stroma. The condition is called *striate keratitis* or *striate keratopathy* (see colour plates 6 and 11). It usually occurs on the upper part of the cornea because this is the part where surgical trauma is likely to occur. In most cases the other endothelial cells will take over the function of the damaged ones, and after a week or so the cornea becomes clear once again.

However in serious cases many endothelial cells may be damaged or the endothelial cells may not have been healthy in the first place. If this happens the remaining cells are unable to take over the function of the ones damaged at surgery, and so the entire cornea will become swollen (oedematous) and hazy. Fluid-filled blisters develop in the epithelium on the surface of the cornea, these are called bullae. As each blister bursts there is a shallow corneal ulcer so the patient experiences recurrent episodes of sharp pain. The vision is greatly reduced because of the corneal haze. The condition is called *bullous keratopathy* (see colour plate 7). It usually comes on quite soon after the operation but it may be delayed for a few months or even years.

It is extremely important to preserve the corneal endothelium and to limit any damage to endothelial cells at surgery. The surgeon should be aware of the different ways in which this damage may occur. The corneal endothelium is susceptible to both mechanical and chemical injury.

1. *Mechanical injury.* The endothelial cells are very fragile and can easily be rubbed off if an instrument touches the inner corneal surface. They can be damaged by a clumsy incision. Great care must be taken during any intraocular procedure to avoid touching the inside of the cornea. It is best to maintain a deep anterior chamber when instruments are being introduced into the eye. Excessive folding of the cornea by the assistant can cause damage as can vigorous irrigation in the eye. Massaging the cornea so that it rubs against the lens or the iris will also damage the endothelial cells. The golden rule of all intraocular surgery is “**avoid any unnecessary or excessive manipulation inside the eye**”.
2. *Chemical injury.* Take great care when choosing an irrigating fluid to be used in the anterior chamber. Ideally its composition should match that of the aqueous. Hartmann’s or Ringer’s solutions are best but physiological saline is acceptable. Solutions of the wrong osmotic strength or composition and particularly solutions containing preservatives can destroy the endothelial cells and cause permanent corneal oedema. Locally sold preparations are sometimes manufactured without proper quality control or are incorrectly packaged. Bacterial or chemical contamination may be present. It is very important to ensure that irrigating fluids come from a reliable source or are freshly prepared in one’s own hospital pharmacy. There may be chemical residues on surgical instruments if chemical solutions are used to sterilise the instruments. These must be very thoroughly rinsed. Take particular care to rinse very carefully the insides of any tubes, irrigation lines or cannulas. These may contain chemicals, boiled water or other residues which can seriously damage the corneal endothelium.

7. Avoiding damage to the lens

The lens capsule is another sensitive structure and, if the capsule is damaged or punctured, fluid will enter the lens and a cataract will form later. It is very easy to puncture the lens, and so great care must be taken not to touch it during operations such as iridectomy or trabeculectomy in which the lens is not to be removed from the eye.

8. Handling the iris

The iris is involved in many intraocular operations, and is often damaged in penetrating injuries.

The iris is probably less affected by surgical trauma than any other intraocular structure. Pieces of it can be excised without damaging the rest of the eye or the rest of the iris. If a complete segment of the iris is removed then of course the pupil sphincter will no longer function normally.

The iris is very vascular but surprisingly enough there is usually very little bleeding following surgery on it. However like all intraocular tissues it should be treated with great gentleness and care. There are certain situations in which the iris may create surgical problems during intraocular operations:

- If it is grasped or pulled too firmly, it may become torn off from where it is attached to the ciliary body. This is called the root or base of the iris, and it is where the main artery supplying the iris runs right round the iris at its base. An iris tear here will cause a brisk intraocular haemorrhage. When performing an iridectomy, try not to pull it away from its attachment to the ciliary body or it will bleed profusely. A peripheral iridectomy should leave a small hole in the middle of the iris and a full iridectomy will also divide the pupil margin (see pages 139–40).
- During surgery the iris easily becomes adherent to adjoining structures especially to the edges of the limbal incision. These adhesions should be freed before finishing the operation.
- Post-operatively the iris may adhere to the back of the cornea (anterior synechiae), or to the lens surface or to the face of the vitreous (posterior synechiae). Some degree of inflammation in the iris (iritis) is very common postoperatively and will contribute towards these adhesions.

9. The Vitreous

The vitreous is a gel-like substance that fills the bulk of the eye behind the lens. It has complex and delicate attachments to the retina. In youth these are strong and the gel has a firm consistency. As the vitreous ages it degenerates and becomes more fluid. This occurs more readily in myopic eyes and following ocular inflammation.

Because of its attachment to the retina any disturbance or damage to the vitreous has a significant risk of causing damage to the retina, particularly a retinal detachment. Until comparatively recently the vitreous was a “no go” area for eye surgeons. Nowadays operations can be carried out inside the vitreous, and the vitreous can be removed and replaced. However the equipment is very delicate, sophisticated and expensive and not routinely available in developing countries.

For the surgical procedures described here every attempt should be made to avoid any contact with the vitreous.

However the vitreous may occasionally prolapse from the eye either as a complication of cataract extraction or following a penetrating injury. If this happens it is very important to manage the vitreous loss correctly and so reduce the risk of further complications (see page 113).

10. Wound closure

Obviously the eye must be closed properly at the end of an intraocular operation. The use of fine sutures and accurate, secure wound closure has greatly lowered the incidence of post-operative complications. However all suture materials are foreign bodies and they can in themselves cause complications if they are used incorrectly. Sutures on the surface of the eye can cause severe irritation to the cornea, which can progress to corneal scarring and vascularisation. Just occasionally corneal sutures can cause infected corneal ulcers, and even endophthalmitis.

Suture Materials

For intraocular surgery sutures must be very fine, 8“0” or finer. Several different materials are used as sutures, and the surgeon must know how these sutures behave both at the time of operation and also into the future postoperatively.

The most commonly used sutures for intraocular surgery

| <i>Non absorbable sutures</i> | <i>Size</i> |
|---------------------------------------|----------------|
| Virgin silk (braided) | 8“0” or 9“0” |
| Nylon (monofilament) | 9“0” or 10“0” |
| Polyester or mersilene (monofilament) | 10“0” or 11“0” |
| <i>Absorbable sutures</i> | |
| Collagen | 8“0” |
| Polyglactin or vicryl | 8“0” or 9“0” |

Braided sutures are made of many different strands of material and have the advantage of being easier to handle and knot. Monofilament sutures have just one strand. They are stronger for their size and cause less tissue reaction, but are harder to handle and knot.

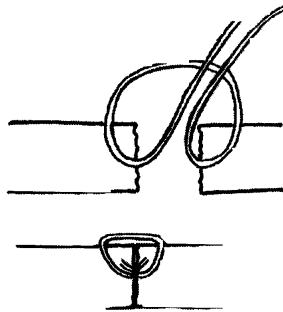
1. “Virgin silk” is the usual name for very fine 8“0” or 9“0” silk. This is very popular, it is easy to handle and knots well because it is braided. On the surface of the eye it is fairly soft and doesn’t cause too much irritation. Some delayed tissue reaction occurs because the suture dissolves very slowly over the course of some months or even years. Virgin silk is always used as interrupted sutures. About five sutures are recommended to close a standard cataract incision. It can also be used to suture the conjunctiva and the scleral flap of a trabeculectomy. If virgin silk sutures are buried under the conjunctiva they can usually be left for ever, but they can occasionally cause a foreign body reaction. If they are

used to suture the conjunctiva they will usually fall out by themselves after a few weeks. If they are used on the cornea they **must** be removed after a few weeks, because they act like a foreign body and will cause inflammation and possibly infection.

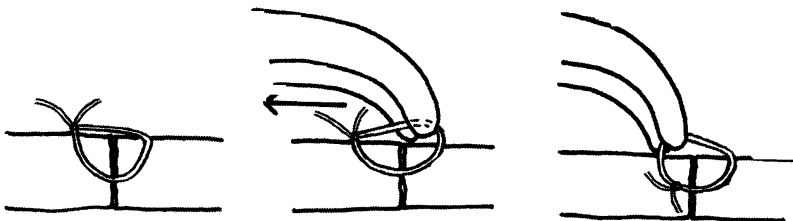
2. Fine monofilament nylon of 9“0” to 10“0” gauge is another popular suture for intraocular surgery. Nylon is strong and extremely fine. It is so fine that the 10“0” gauge is hard to work with unless using an operating microscope. Nylon is inert and causes hardly any tissue reaction or inflammation in itself. Because it is so fine and inert a nylon suture on the cornea will become covered by the corneal epithelium. In this way it doesn't cause any inflammation. However if the knots and the suture ends are left on the surface of the eye, they will not become covered by the epithelium. Nylon is much harder than virgin silk ,and so these knots and suture ends lying on the cornea will act like sharp and hard foreign bodies. Even when a nylon suture is used under a conjunctival flap, the stitch ends can protrude through the conjunctiva and cause irritation. Therefore using nylon sutures on the cornea, the knots **must** be buried in the tissues and not left on the surface. Even under the conjunctiva the knots should be buried if possible. If not the ends should be cut very short so there is no risk of the ends coming through the conjunctiva.

There are two ways of burying the knots with nylon sutures:-

- Insert the needle from the inside of the wound outwards so the two ends and the knot are inside the wound (see fig. 2.13).
- Alternatively tie the knot on the surface of the cornea as normal and using suture-tying forceps twist the stitch so that the knot then becomes buried (see fig. 2.14). (This technique will not work for 9“0” nylon, as the knot is too thick to pass into the cornea).



2-13 Placing the suture with the knot buried



2.14 Rotating the suture to bury the knot

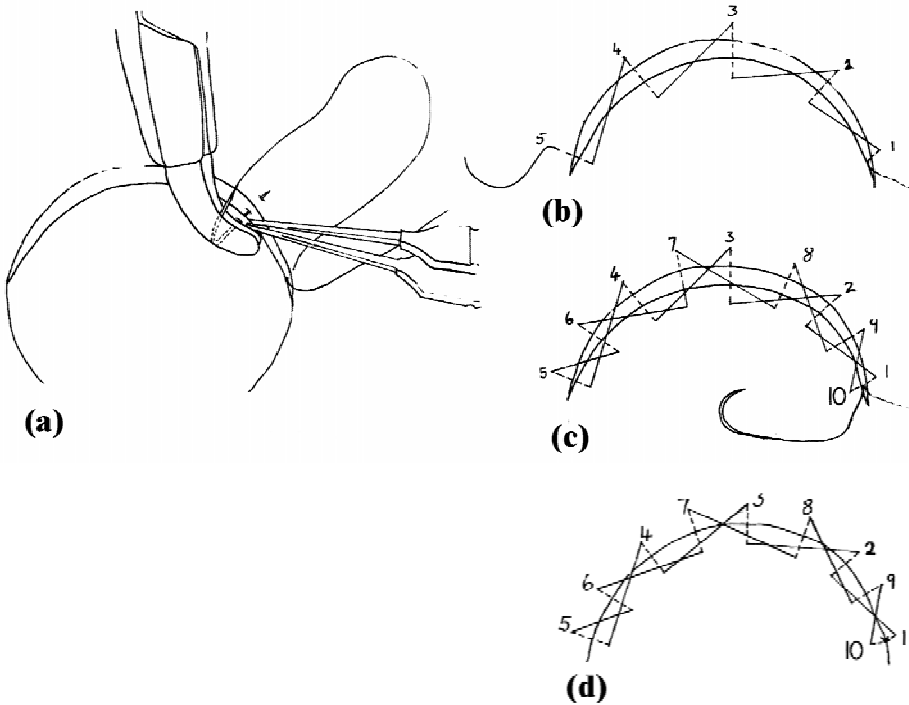


Fig. 2.15 The technique of closing a wound with a running monofilament suture

Nylon sutures are not as easy to work with as virgin silk, and the knots tend to slip or come undone. The knots must be tied correctly (see previous page). Interrupted monofilament sutures can be used to close a cataract incision or to suture the scleral flap after a trabeculectomy. Monofilament nylon is very popular as a continuous or running suture to close cataract incisions (fig. 2.15). It provides a very quick and secure wound closure with minimal inflammatory reaction but the knot should be buried in the tissues. The way to do this is to start the suturing from inside the tissues and also finish the suturing inside the tissues so the knot is automatically buried.

There is another problem with monofilament nylon sutures on the surface of the cornea. After about a year the suture material “bio-degrades”, so that it weakens because of the action of the tissue fluids and will eventually break. This means that the ends come to the surface, so they are no longer covered with corneal epithelium. They then act as foreign bodies causing irritation and a risk of corneal abscesses. After some time the sutures may also become loose and in this way act as foreign bodies. Therefore if nylon sutures are used on the surface of the cornea *they must be removed*. The ideal time for this is about six months after the operation. If they are removed before this there is the possibility of causing astigmatism because it takes up to six months for a corneal wound to heal completely.

3. Polyester or mersilene sutures are also monofilament and are fairly similar to nylon. Polyester is even harder and stronger than nylon, and so even finer gauges can be used, 10“0” to 11“0”. However it is slightly more difficult to handle. Polyester sutures do not “biodegrade” at all. As long as they do not become loose they can be left indefinitely in the cornea, which is an advantage if the patient is not coming back after the operation.
4. Collagen or polyglactin sutures are absorbable. Absorbable sutures usually cause some inflammation in the surrounding tissues during the process of absorption. Collagen is rarely used now for intraocular surgery because polyglactin is much stronger, and causes less inflammation. 8“0” polyglactin (vicryl) is braided and handles very much like virgin silk, except the knots are not quite so secure so have to be tied more carefully. It should only be used as interrupted sutures, and should be used in the same way as virgin silk. That means:- to close a scleral or limbal incision under a conjunctival flap, or to suture the conjunctiva itself. Absorbable sutures should not be used on the cornea, because they will cause a foreign body reaction. Polyglactin is more expensive than virgin silk. It has the advantage of not causing delayed foreign body reactions in the tissues because it is always absorbed after a few weeks.
5. Other suture materials are used occasionally. Polypropylene is very similar to polyester but more elastic. Very fine stainless steel can be used. It is inert, but the ends must be buried. In an emergency human hair can be used, if there is a fine needle to thread it on.

Summary of recommended sutures for intraocular use

1. Incisions at the limbus or in the sclera
 - Either a: interrupted virgin silk or polyglactin
 - Or b: continuous nylon or polyester
 - Or c: interrupted nylon or polyester
2. Corneal incisions or repairing corneal wounds
 - Either a: interrupted or continuous polyester (buried knots)
 - Or b: interrupted or continuous nylon (buried knots and remove after 6 months)
3. Conjunctiva
 - interrupted polyglactin or virgin silk

Loose sutures are not performing any useful function and should always be removed. Once any suture becomes loose it will work its way to the surface of the eye and cause irritation. Loose suture material on the conjunctiva causes some irritation, but will fairly soon falls out. However loose sutures on the surface of the cornea cause severe irritation and may become infected forming a corneal abscess. They must therefore be removed immediately.

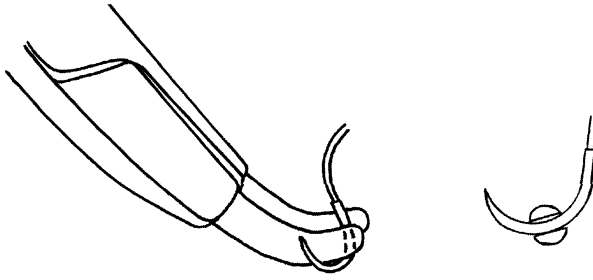


Fig. 2.16 The correct position to hold the needle

Needles

The needles used for suturing the eye are obviously fine and small and can be easily damaged. They have a flat lancet point. Nowadays most needles come with the thread attached but it is possible to obtain re-usable needles which can be threaded. This will be a little cheaper. Since the cornea and sclera are tough tissue, blunt needles are very difficult to use. If handled incorrectly the needles can bend or even snap. The needle should be held between the tips of a needle holder half-way along its length (fig. 2.16).

Suture Technique

For intraocular surgery it is very important to adjust the tension of the sutures correctly. If tied too tightly they can cause astigmatism; too loosely and the wound may leak. The needle point should enter the tissue with the needle tip pointing straight downwards approximately 1 mm from the wound edge. Countertraction is applied by holding the wound edge with forceps and this helps to hold the tissues in place. These forceps should be either fine toothed forceps (fig. 2.17) or fine cupped forceps (fig. 2.18). The cupped forceps are more practical because they are less likely to get damaged. As the needle passes through the tissues the needleholder is rotated and this applies force along the curve of the needle to avoid bending it. The tip of the needle will come out into the wound and should pass through at least half the total thickness of the cornea or the sclera (fig. 2.19a). The needle is allowed to carry on into the opposite side so that the depth of the suture is equal to avoid a step in the wound. The needle is advanced until the tip is well clear before it is grasped with the needle holder to pull the suture through. In this way the tip is

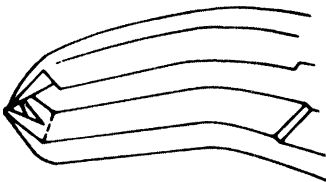


Fig. 2.17 Toothed forceps

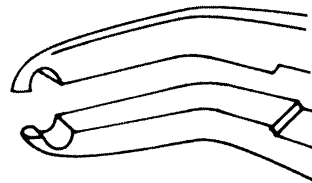


Fig. 2.18 Cupped forceps

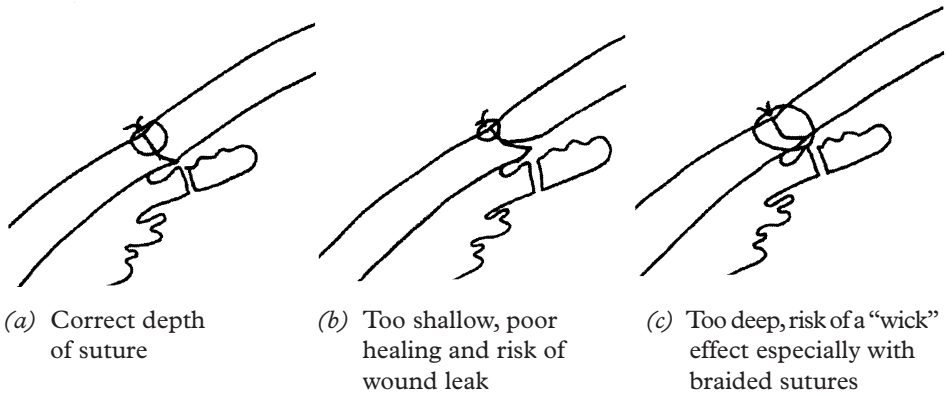


Fig 2.19 Suturing the wound

avoided and so the risk of blunting it is reduced. Some people find it easier to take separate bites with the needle on each side of the wound. The sutures are placed perpendicular to the incision passing the needle from mobile tissue to fixed tissue, i.e. from cornea to sclera. Try to take bites of equal size on each side of the wound.

If the stitch is not deep enough it will fail to hold the wound edges together securely and the wound may leak (fig. 2.19b). If the stitch is too deep the suture material may pass right into the anterior chamber. The stitch will then become a "wick" which may allow aqueous to leak out of the eye, or it may become a track which allows infection to enter the eye (fig.2.19c). This "wick" effect is more of a problem with virgin silk sutures than monofilament sutures.

Tying knots

Suture materials vary in their ease of handling and knotting. Tying knots is made easier if the suture end is kept short. This also reduces wastage of the suture material. Suture-tying forceps are available but in general any blocked tissue holding forceps and the needle holder are adequate. Using the forceps the suture is wound twice around the jaws of the needle holder (fig. 2.20). The suture end is then grasped with the needle holder. The knot is then pulled off the holder and tensioned so that the wound edges are brought together but not too tightly. A second single hitch is applied this time winding a loop into the needle holder in the opposite direction. The original direction is used for the third hitch thus ensuring a surgical knot (fig. 2.21). It is important to lay the hitches properly so as not to twist the knot. The knot should always be left on the scleral side of the incision where it can be more easily buried under the conjunctiva. The ends are cut short. (With monofilament sutures the knots may slip or come loose. Some surgeons therefore wind the thread three times round the needle holder on the first hitch).

The conjunctiva heals very rapidly and does not require extensive suturing. However it is helpful to use one or two fine sutures to hold it in place. One great advantage of the fornix based conjunctival flap is that it can be secured with one or at most two sutures to tighten it (see fig. 5.52, page 121).

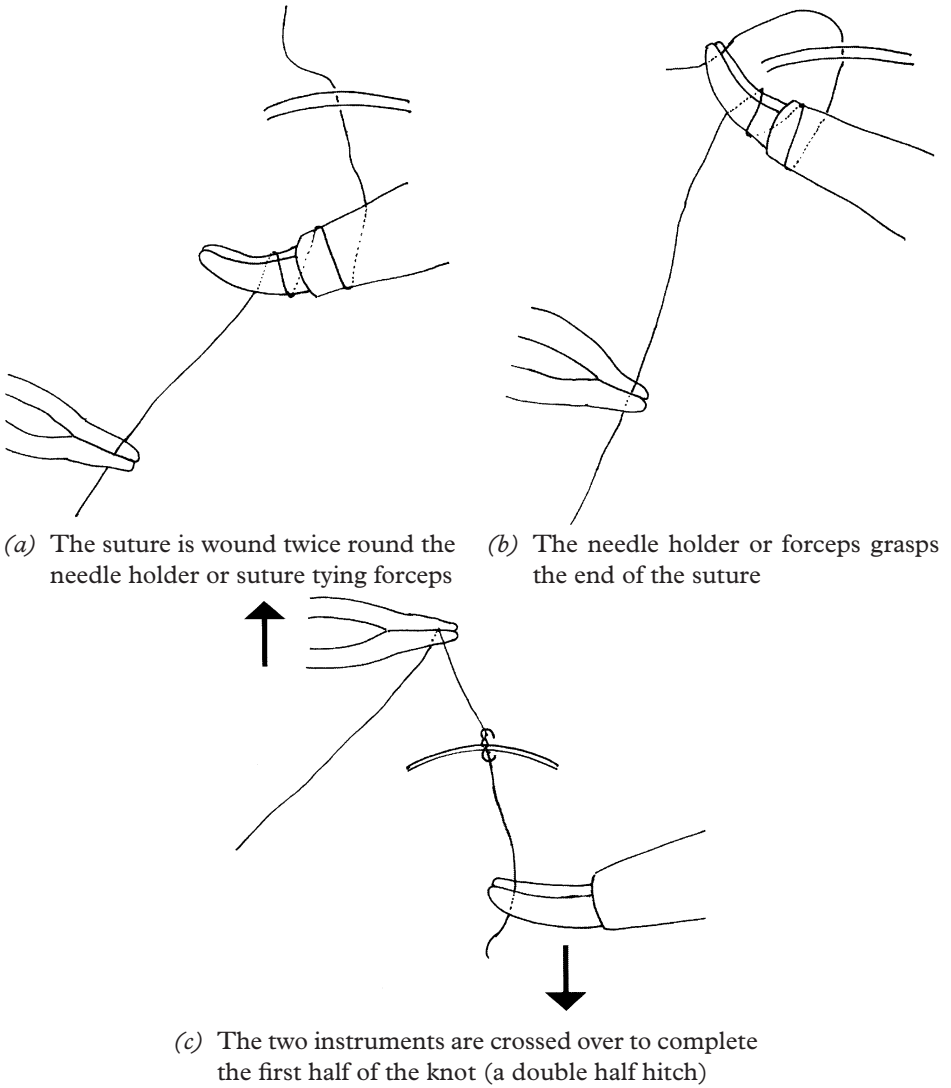


Fig. 2.20 Winding the suture around the needle holder

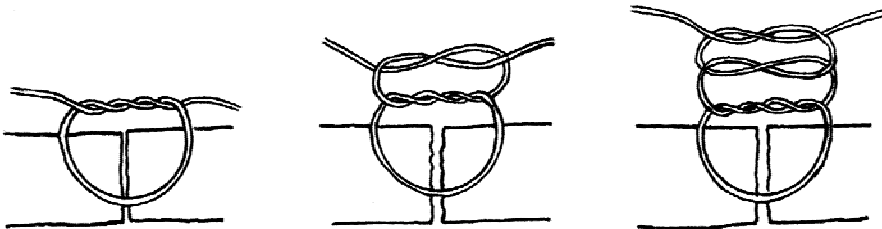


Fig. 2.21 The complete knot

Poor wound closure can cause many problems post-operatively.

The most common are:

- Excessive leakage of aqueous causing a delay in the reformation of the anterior chamber.
- Prolapse of the iris or vitreous through the wound.
- Bleeding into the anterior chamber a few days after the operation from the rupture of small blood vessels trying to bridge the gap in the wound.
- Astigmatism from the irregularity of the curvature of the cornea.

These complications are all discussed in greater detail on page 159.

11. Reducing Post Operative Intraocular Inflammation

There is always some inflammation following any intraocular operation. This will be increased if the surgery was difficult or complicated. Post-operatively mydriatics and steroids are applied locally to the eye almost routinely to diminish post-operative intraocular inflammation. (Post-operative inflammation and its treatment is discussed in more detail on pages 156.)